Research Paper Medical Science

Management of congenital multiple pulmonary stenosis in TGA undergo to ASO

Miguel A. Maluf	Cardiovascular Division – São Paulo Federal University – Brazil
Luiz J. Kajita	São Paulo Heart Institute - Brazil

KEYWORDS

INTRODUCTION:
The arterial switch operation has been universally recognized as the therapy of choice for children born with transposition of the great arteries with ventricular septal defect (TGA – VSD) [1], intact ventricular septum (TGA- IVS) [2] or variants with an excellent early outcome [3]. The arterial switch operation (ASO) ensures "anatomic correction" at the arterial level, has been lowered and is consistently below 10% in most contemporary series. Most children who have undergone the ASO have also enjoyed normal growth, development, and cardiac function [4,5,6].

Since a neopulmonary trunk needs to be reconstructed in a nonanatomical position, neopulmonary stenosis is a frequent finding, but it rarely has clinical consequences. Most obstructions of the neopulmonary trunk are located at the neopulmonary anastomotic site and are clearly related to inadequate growth.

Right ventricular outflow obstruction is the most frequent postoperative complication, occurring with sufficient severity to require re-intervention in up to 10% of cases. Usually, the obstruction is either at the level of the pulmonary trunk or pulmonary bifurcation and, more uncommonly, in the right ventricular infundibulum [7]. Conversely, right ventricular outflow obstruction resulting from late onset pulmonary valve stenosis (previously aortic valve) is exceedingly rare.

Congenital stenosis of branches pulmonary artery is an uncommon association in TGA, witch compromises the surgical outcome of the ASO and has indication for invasive procedures to remodeling the pulmonary trunk and branches.

We report a neonate who had TGA– IVS and multiple pulmonary stenosis, summited to surgical correction at Cardiovascular Division of São Paulo Federal University.

The purpose of this study is to review the long-term outcomes in late survivor of the ASO and analyzed the different procedures used for reconstruction of the pulmonary branches and relief gradient RV-PA.

CASE REPORTS
Neonate, M, 5 days old, were referred because of TGA-IVS. Significant left ventricle - pulmonary artery (LV-PA) pressure gradient was found during echocardiography; the cardiac catheterization registered mild gradient between LV-PA (40mmHg) and multiple right and left pulmonary artery stenosis. (Fig 1)

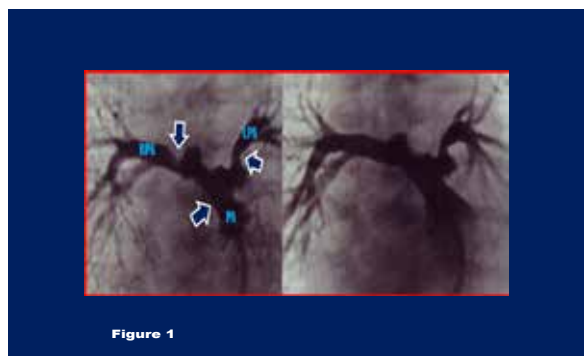

Figure 1

After successful ASO, employing Lecompte's maneuver and enlarged of the right and left pulmonary artery (RPA, LPA) branches, in March, 1995, the neonate underwent clinical follow up during which, a progressive right ventricular outflow tract obstruction caused by stenosis of the pulmonary trunk (PT) to a lesser extent of the pulmonary branches, was diagnosed.

Balloon arterioplasty of PT, RPA and LPA, was performed, in December, 1998, at 45 months of follow-up (3 years old), because of right ventricular hypertension (RV:LV ratio 0.6). After the procedure, the RV:LV ratio dropped to 0.3, and the RV–RPA, LPA peak pressure gradient decreased to 15 and 20 mmHg, respectively.

Symptoms of tiredness. dyspnea, cyanosis appeared after 72 months of follow-up (6 years old), caused by restenosis of the pulmonary branches and surgical reconstruction was indicated.

Reoperation: Operative technique
The operation was performed under the conditions of moderate hypothermic cardiopulmonary bypass (CPB) and beating heart. The pulmonary artery approach was performed with vertical arteriotomy, from the supravalvar area and extended through of the pulmonary trunk (PT) to distal right and left branches.

Multiple bilateral stenosis was detected and submitted to reconstruction of the PT, RPA and LPA, using a preserved corrugated bovine pericardium pantaloon patch.

Postoperative echocardiographic evaluations showed satisfactory flow form the RV to pulmonary branches.

Computed tomography angiography performed with 192 months of follow-up (16 years old), detected important localized bilateral stenosis at the distal portion of the pulmonary branches. The PT and proximal RPA and LPA, were well developed.

Pulmonary stenosis is related to the inadequate growth of the pulmonary anastomotic site, or retraction of the tissue at the junction between the enlarged area (bovine pericardium patch) and distal pulmonary arteries, induced localized pulmonary branches stenosis.(Fig 2 A, B, C)

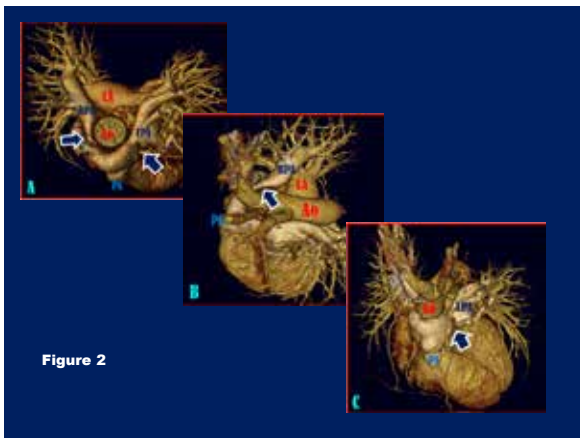

Endovascular stent implantation in the pulmonary arteries

To endovascular stent implantation for pulmonary artery stenosis, was used a long, large-bore vascular sheath to insure precise implantation without embolization or malposition. A long vascular sheath, has not difficult to position at distal pulmonary branches.

A Palmaz Genesis stent were delivered uncovered on balloon catheters via short sheaths (6-7 Fr); super-stiff guidewires were not necessary. These stents, with a maximal expanded diameter of 29 mm, were placed for peripheral pulmonary artery stenosis. The stents were initially implanted on 8 mm balloon catheters and further expanded.

Stents were placed in the RPA and LPA (Fig 3 A, B, C). Both stents were implanted successfully in the desired location without stent malposition or embolization. Mean angiographic diameter increased from 5.5 to 29 mm and 4.5 to 29 mm, respectively. (Fig 3 D)

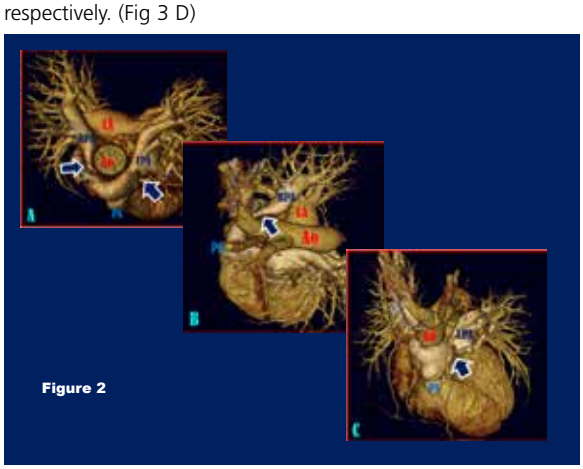

The peak systolic ejection gradients, between RV-PA, decreased from 60 to 40 mm Hg (Table 1).

The uncovered delivery of the premounted Palmaz Geneis stent allowed for precise and safe endovascular stent implantation without the hemodynamic and technical problems associated with long vascular sheath usage. This technique is useful for the palliation of pulmonary arteries stenosis and was an effective definitive treatment for peripheral pulmonary artery stenosis.

Discussion.

The development of pulmonary artery stenosis is a potential complication during the mid- to long-term follow-up after arterial switch operation (ASO) for transposition of the great arteries. Surgical results have been disappointing and conventional balloon dilation yields a fairly important incidence of failures and recurrences [7]. Formigari et al [8] evaluated the results with implantation of balloon-expandable stents in 5 out of 13 patients with a previously attempted unsuccessful conventional balloon dilation of pulmonary artery branch stenosis after ASO. In two more cases, stents were used as a primary procedure. Balloon angioplasty achieved a 15% increase in mean diameter of the stenosis vs. 124% with the use of stents ($P < 0.01$), a 10% decrease of the pressure gradient across the stenosis vs. 71% of stents ($P < 0.01$), and a 10% drop in RV/aorta pressure ratio vs. 43% of stents ($P < 0.01$). Compared to conventional balloon angioplasty in this series, stents were more effective in the treatment of patients with peripheral pulmonary artery stenosis after ASO. Balloon dilation should be considered in selected cases unsuitable for treatment with endovascular stents.

In our experience, form 180 cases of ASO, operated between 1993 to 2010, 5 (2.77%) patients were submitted to invasive procedure for correction of supravalvular and pulmonary branches stenosis, between 1 month and 192 months, of follow-up. There no death and in all cases the gradient, between RV– PA, was alived.

It is possible that, the pulmonary stenosis is related either to the inadequate growth of the pulmonary anastomotic site or to the inadequate growth of the new right ventricular outflow tract in patients with associated aortic arch obstruction [9]. Nakanishi et al. [10] observed a small annulus or even growth failure of the neopulmonary annulus after the ASO in 18% of their series. The reported incidence of pulmonary stenosis varies from 7 to 50% [11].

This case reports, multiple stenosis of pulmonary artery branches, after born. We just employing combined invasive treatment, for correction of pulmonary stenosis, in three step (45, 72 and 192 months), after ASO: Balloon pulmonary arterioplasty (3 years old), surgical reconstruction of pulmonary artery (6 years old) and finally pulmonary stents implanted in both branches of pulmonary artery (17 years old).

Actually, the patient is 19 years of age, performs routine activities without restrictions and exercises with moderate effort, without cardiac medication. In the stress test, He showed: good physical fitness in exercise test, there are not myocardial ischemia or cardiac arrhythmias

Conclusion:

Over time, congenital stenosis branches pulmonary artery or after ASO, balloon angioplasty, could be the initial treatment of choice owing to the high success rate. Surgical intervention is offered to those with pulmonary valve stenosis, having pressure gradients of >50 mmHg, and re-stenosis, after intervention/stent implantation. In this patient, implantation of balloon-expandable stents in the pulmonary branches, with a previously attempted unsuccessful conventional balloon dilation and pulmonary artery branches surgical reconstructions, after ASO, had a successful results.

REFERENCES

1- Jatene AD, Fontes VF, Paulista PP, de Souza LC, Neger F, Galantier M, Souza JE. Successful anatomic correction of transposition of the great vessels. A preliminary report. Arq Bras Cardiol 1975 ;28:461-64. | 2- Castaneda AR, Trusler GA, Paul MH, Blackstone EH, Kirklin JW, and the Congenital Heart Surgeons Society: The early results of treatment of simple transposition in the current era. J Thorac Cardiovasc Surg 1988;95:14-28. | 3- Lecompte Y, Zannini L, Hazan E, Jarreau MM, Bex JP, Tu TV, Neveux JY. Anatomic correction of transposition of the great arteries. J Thorac Cardiovasc Surg 1981;82:629-31. | 4- Wernowsky G, Hougen TJ, Walsh EP. Mid-term results after arterial switch operation for transposition of the great arteries with intact ventricular septum: clinical, hemodynamic, echocardiographic and electrophysiologic data. Circulation 1998;77:1333–1344. | 5- Angeli E, Raisky O, Bonnet D, Sidi D, Vouhé PR . Late reoperations after neonatal arterial switch operation for transposition of the great arteries. Eur J Cardio-Thorac Surg 2008; 34:32-6. | 6- Lupinetti FM, Bove EL, Minich LLI . Intermediate-term survival and functional results after arterial repair for transposition of the great arteries. J Thorac Cardiovasc Surg 1992;103:421–427. | 7- Yacoub MH, Bernhard A, Radley-Smith R. Supravalvular pulmonary stenosis after anatomic correction of transposition of the great arteries: causes and prevention. Circulation 1982;66:193–197. | 8- Formigari, R., Santoro, G., Guccione, P., Giamberti, A., Pasquini, L., Grigioni ENG, M. and Ballerini, L. Treatment of pulmonary artery stenosis after arterial switch operation: Stent implantation vs. balloon angioplasty . Cathet. Cardiovasc. Intervent 2000;50:207–211. | 9- Serraf A, Roux D, Lacour-Gayet F . Reoperation after arterial switch operation for transposition of the great arteries. J Thorac Cardiovasc Surg 1995;110:892–899. | 10- Nakanishi T, Matsumoto Y, Seguchi M. Balloon angioplasty for postoperative pulmonary artery stenosis in transposition of the great arteries. J Am Coll Cardiol1993;22:859–866. | 11- Raja S, Nayak S, Kaarne M. Arterial Switch Operation for Simple Transposition: Three Decades Later. The Internet Journal of Thoracic and Cardiovascular Surgery 2003;6(2):35-45. |