Research Paper Medical Science

Mikulicz's Disease – An IgG4-Related Disease. A Clinical Case

Daniela Trandafir	M.D., Ph. D., Assistant Professor, Faculty of Dental Medicine, Department of Surgery, "Grigore T. Popa" University of Medicine and Pharmacy, Iasi, Romania
Eugenia Popescu	D.M.D., Ph. D., Professor, Faculty of Dental Medicine, Department of Surgery, "Grigore T. Popa" University of Medicine and Pharmacy, Iasi, Romania
Mihai Danciu	M.D., Ph. D., Lecturer, Faculty of Medicine, Discipline of Pathology, "Grigore T. Popa" University of Medicine and Pharmacy, Iasi, Romania
Violeta Trandafir	D.M.D., Ph. D., Assistant Professor, Faculty of Dental Medicine, Department of Surgery, "Grigore T. Popa" University of Medicine and Pharmacy, Iasi, Romania

ABSTRACT

Mikulicz's disease is a symmetrical and persistent swelling of the salivary and lacrimal glands, considered by some researchers to be a form of primary Sjögren's syndrome due to its histological similarities.Recent studies have concluded that Mikulicz's disease pathogenesis differs from that of Sjögren's syndrome, because Mikulicz's disease patients was detected with an increased serum IgG4 but also with infiltration with abundant IgG4-positive plasma cells in lacrimal and salivary glands. Considering the clinical aspects, Mikulicz's disease show a good response to the treatment with corticosteroids, both in terms of normal dimension of the affected glands and their secretion recovery.We report the clinical case of an elderly patient, who was diagnosed in our service with Mikulicz's disease, with positive response after two weeks treatment with low-dose Prednisone.

KEYWORDS: Mikulicz's disease, IgG4-related diseases, salivary and lacrimal glands symmetric hypertrophy, corticosteroid therapy

INTRODUCTION

Mikulicz's disease, also known as benign lymphoepithelial lesion, designates idiopathic, bilateral, symmetric and painless swelling of the lacrimal, parotid and submandibular glands. The complications of the disease include autoimmune pancreatitis, retroperitoneal fibrosis, tubulointerstitial nephritis, autoimmune hypophysitis and Riedel's autoimmune thyroiditis, disorders that have in common immunoglobulin IgG4 elevated serum levels and tissue infiltrations with IgG4-positive plasmacytes.Two teams of researchers from the Japanese Ministry of Health, Labour and Welfarewere in agreement,in their second workshop in Kanazawa in 2010, to use the term „IgG4-related disease (IgG4-RD)" to identify these clinical entities [1].

Therefore, IgG4-related disease is a multiorgan disease and includes several immunologically mediated diseases that previously were considered as isolated lesions of a single organ, with no evidenceof subjacent systemic involvement.The key to diagnosis in IgG4-related diseases are three histopathological characteristics, namely: lymphoplasmacytic infiltration, storiform fibrosis („wheel spokes" shaped) and obliterative phlebitis [2], the extension of fibrosis being the main determinantfactorof the response to immunosuppressive therapy. In general, in the inflammatory stage, IgG4-related diseases respond to glucocorticoid therapy, but recurrent or refractory cases are also common.

We present the clinical case of a male patient, 74 years old, who at first was clinically suspected of Mikulicz's disease diagnosis andthe confirmation was made by immunological examination of the patient's serumand by histopathological examination ofa swollen salivary gland that has been surgically extirpated.

CLINICAL CASE

A male patient, 74 years old, farmer, was admittedinthe Clinic of Oral and Maxillofacial Surgery Iasi, in 2015, with bilateral, symmetric and painless swelling of the submandibular glands, notified by 2-3 months (**fig. 1**). It should be mentioned that he had recently been investigated in the medical services of Gastroenterology and Internal Medicine, and the general diseases associated at the time of admission in our clinic could be summarized as follows:1)Ascending colon polip; 2)Resected stomach (for duodenal ulcer); 3)Stump stomach gastritis; 4) Permanent atrial fibrillation; 5)Chronic heart failure, NYHA class II; 6)Right bundle branch block; 7)Dilated cardiomyopathy; 8)Mild hypertension;9) Type II diabetes;10) Dyslipidemia; 11)Treatment with oral anticoagulants.The drug treatment he followed in the last 30 days was represented by: 1) Digoxin, 1tb/ day; 2) MR Preductal, 1tbX2/ day; 3) Carvedilol 6.25mg, ½ tbX2/ day; 4) Indapamide, 1tb/ day; 5) Ursofalk 250 mg, 1tb/ day; 6) Controloc 40 mg/ day; 7) Pradaxa 110 mgX2/ day. The clinical examination at his admission in the Clinic of Oral and Maxillofacial Surgery revealed the following aspects: mild swelling of both lacrimal gland (without a complaint of the sensation of dry eye) (**fig. 2**); bilateral, symmetric and painless moderate swelling of the submandibular (**fig. 1**) and sublingual glands (**fig. 3**) and only mild swelling of the parotid glands (with a vague sensation of dry mouth). As general complaints, we mention: weight loss of about 5 kg in the last 2 months and fatigue. Of the biological blood investigationswe

mention the following results: anti-Ro (SS-A) = 1.1 U/mL (below 7 U/mL - negative) and anti-La (SS-B) = 0.9 U/mL (below 7 U/mL - negative); IgG = 1890 mg/dL (normal, 700-1600 mg/dL); negative viral markers (HBsantigen = 0.37, HCV antibodies = 0.008); negative tumor markers, except CA 19-9 slightly increased (alphafetoprotein = 1.06 IU/mL, negative; CA 19-9 = 92.9 U/mL (normal, 0-33 U/mL); carcinoembryonic antigen = 1.97 ng/mL, negative).Schirmer's test indicated 10 mm of paper wetting in both eyes after 5 minutes, which means a minordecrease in tear production. CT-scanning of the „head" and „chest" segments showed just a diffuse bilateral parotid and submandibular gland hypertrophy and some swollen lymph nodes (1.5 cm diameter) in bilateral submandibular and laterocervical levels, with an inflammatory aspect.It was decided to perform a biopsy of one of the submandibular respectively sublingual glands, for a final histopathological diagnosisfollowed by immunohistochemistry. Pathologic examinationrevealed themaintaining of the salivary glands lobular structure, the existence of an abundant diffuse lymphoplasmacytic infiltrate with the reactive type of medium lymphocytes and isolated strips of fibrosis(**fig. 4**).Phenotyping immunohistochemistry of the exuberant lymphoplasmacytic infiltration was performed to rule out the malignant lymphoid process. The clinical examination, the results of biological investigations (with increased serum IgG levels) and the morphological aspectof chronic sialadenitis with marked lymphoid hyperplasia ledus to a positive diagnosis of Mikulicz's disease.Moreover, IgG subclasses research by nephelometric method (a test workedin Germany), showed a growth of IgG4 subclass to 144 mg/dL (normal, 5-130 mg/dL).It was givena low dose of oral corticosteroid (Prednisone, 15 mg/day) – due to gastric personal history, finding that the initial swollen salivary and lacrimal glands returned to the normal size (after just two weeks of treatment).The subsequent evolution was favorable, with decreased dose of cortisone to 10 mg/day after one month and 5 mg/day after another month, after which corticosteroid therapy was discontinued.

DISCUSSION

Mikulicz's disease is a rare idiopathic disorder,characterised by benign and painless swelling of the lacrimal, parotid and submandibular glands, bilaterally.It was included in the diagnosis of primary Sjögren's syndrome, but it is a unique condition involving persistent enlargement of the salivary and lacrimal glands, accompaniedby a few autoimmune reactions and a good response to glucocorticoids that leads to recovery of the gland functionality [3].Elevated serum levels of IgG4 and importantinfiltrates of plasma cells expressing IgG4have been reported to be associated to Mikulicz's disease in the last 10 years [4]. Thefollowing issues are used for diagnosis: (a) visible confirmation of the symmetrical and persistent swelling in more than two lacrimal and major salivary glands, (b) significant infiltration of mononuclear cells in the lacrimal and salivary glands, (c) ruling out other diseases that present glandular swelling, such as sarcoidosis and lymphoproliferative diseases [5].

Currently, there is a growing recognition of some IgG4-associatedsystemic diseases, which brings together a variety of illnesses of unknown etiology, occurring mostly in the middle or old age with specific histological, serological and clinical related issues [6].These entities may include:Mikulicz's disease, type 1 autoimmune pancreatitis, retroperitoneal fibrosis, chronic sclerosis aortitis, autoimmune thyroiditis, IgG4-associated interstitial pneumonitis, IgG4-associated tubulointerstitial nephritis [7].The hallmarks for IgG4-related diseases are: positive IgG4 lymphoplasmacytic infiltration accompanied by tissue fibrosis and obliterative phlebitis and elevated serum IgG4 levels in the majority of patients who address to the medical advice with diffuse enlargement of an organ.A good therapeutic response to glucocorticoids is also a characteristic of these diseases [8].Diagnosis is based on biopsy and histopathological exam and the existence ofelevated serum levels of IgG4.The treatment of choice is a glucocorticoid one, the average dose of oral prednisone (40-50 mg/day) being strongly recommended, with a corresponding decrease in cortisol over a period of two months. The therapeutic response is characterized by relieving symptoms,the reductionin size of the swollen organ, improvement of its functions and often lowering serum IgG4 levels [9]. The normal evolutionand prognosis of these diseases are not well documented.Most patients initially respond well to corticosteroid treatment, but relapses are common to discontinuation.The interested organ dysfunction may occur due to the uncontrolled and progressive inflammation, but also to the fibrotic changes in the affected tissues [10].

This case is distinguished by bilateral moderate chronic inflammatory swelling of the submandibular and sublingual glands,but less evident in the parotid and lacrimal glands. Since the salivary and lacrimal secretions were interested in a small degree, we concluded that the salivary and lacrimal glands damage was not very old. The bilateral and symmetric swelling of the salivary and lacrimal glands, the patient gender and his advanced age favored a clinical diagnosis of Mikulicz's disease.CT examination revealed parotid and submandibular symmetrical hypertrophy without detected tumors within those structures.The histopathologic examination of biopsied salivary glands (a sublingual gland and submandibular one) revealed lobular structure preservation and the existence of a diffuse lymphoplasmacytic infiltrate, supportingMikulicz's disease diagnosis.This IgG4 elevated level in patient serum as well as the good therapeutic response to administration of Prednisone have determined the inclusion of this case into systemic diseases associated with IgG4.As a characteristic of the case, we emphasize the use of low-dose Prednisone, due to personal history of stomach resection for ulcer disease.Minimal xerostomia and keratoconjunctivitis sicca, the gender of patient, increased plasma levels of IgG4, glandular architecture preservedare the main arguments favoring the Mikulicz's disease diagnosis instead of Sjögren's syndrome.The favorable case evolution after 6 months from the diagnosis and the initiation ofthe treatment with Prednisone, did not rule out the further follow up of the patient to detect any relapse after the treatment was discontinued.

CONCLUSIONS

Mikulicz's disease diagnosis was established after clinical examination and was confirmed by the histopathological examination of the affected salivary gland biopsy.

The increased serum IgG4 level supports the autoimmunity in this clinical entity and in the absence of anti-Ro and anti-La antibodies, we can differentiate Mikulicz's disease from Sjögren's syndrome.

The glucocorticoid treatment effectiveness in our case of Mikulicz's disease correlates with the histopathological aspect showing the preservation of the lobular architecture of the salivary glands and early fibrosis.



Fig. 1. Extraoral image with bilateral, symmetric moderate swelling of the submandibular glands



Fig. 2.Extraoral image with bilateral, symmetric mild swelling of the lacrimal glands



Fig. 3.Intraoral image with bilateral, symmetric moderate swelling of the sublingual glands

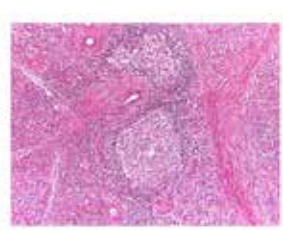

Fig. 4.Histopathological image: chronic sialadenitis with lymphoplasmacytic infiltration and fibrosis (hematoxylin-eosin, magnification X40)

REFERENCES

1. Wu Y, Xu ZR, Zhou WJ, Yang YM. Immunoglobulin G4-related Disease with Features of Mikulicz's Disease and Autoimmune Pancreatitis Which Firstly Presented as Asymptomatic Lymphadenopathy: A Case Report. Chin Med J 2015;128(5):706-707. | 2. Kamisawa T, Zen Y, Pillai S, Stone JH. IgG4-related disease. The Lancet 2015;385(9976):1460-1471. | 3. Yamamoto M, Takahashi H, Ohara M, et al. A new conceptualization for Mikulicz's disease as an IgG4-related plasmacytic disease. Mod Rheumatol 2006;16(6):335-340. | 4. Yamamoto M, Yajima H, Takahashi H, et al. Everyday clinical practice in IgG4-related dacryoadenitis and/or sialadenitis: results from the SMART database. Mod Rheumatol 2015;25(2):199-204. | 5. Yamamoto M, Takahashi H, Sugai S, et al. Clinical and pathological characteristics of Mikulicz's disease (IgG4-related plasmacytic exocrinopathy). Autoimmunity Rev 2005;4:195-200. | 6. Umehara H, Okazaki K, Masaki Y, et al. A novel clinical entity, IgG4-related disease (IgG4RD): general concept and details. Mod Rheumatol 2012;22(1):1-14. | 7. Khosroshahi A, Stone JH. A clinical overview of IgG4-related systemic disease. Curr Opin Rheumatol 2011;23:57-66. | 8. Stone JH, Zen Y, Deshpande V. IgG4-related disease. N Engl J Med 2012; 366(6):539-551. | 9. Geyer JT, Ferry JA, Harris NL, et al. Chronic sclerosing sialadenitis (Küttner tumor) is an IgG4-associated disease. Am J Surg Pathol 2010;34(2):202-210. | 10. Cheuk W, Chan JK. IgG4-related sclerosing disease: a critical appraisal of an evolving clinicopathologic entity. Adv Anat Pathol 2010;17(5):303-332.