Research Paper Medical Science

Obstetrics and Gynaecology: Intestinal Obstruction Due to Ladd's Band in Pregnancy: A Case Report

Dr Omana E K	Assistant Professor Of Obstetrics And Gynaecology, Academy Of Medical Sciences, Pariyaram,Kannur,Kerala
Dr. Vidya S. Prabhu	Assistant Professor Of Obstetrics And Gynaecology, Academy Of Medical Sciences, Pariyaram,Kannur,Kerala
Dr Ajith S	Professor Of Obstetrics And Gynaecology, Academy Of Medical Sciences,Pariyaram,Kannur,Kerala.
Dr. J S Divya Louis	Academy Of Medical Sciences,Pariyaram, Kannur,Kerala

ABSTRACT

Intestinal obstruction in pregnancy is rare.It carries significant maternal and fetal mortality,often due to delay in diagnosis and treatment. A 30year old G3A2 with history of acute renal failure due to increased vomiting and intra uterine fetal demise at her 21 weeks in previous pregnancy,now presented with vomiting and elevated renal function test at her 23 weeks.USG: dilated stomach and duodenum with increased peristalsis with a live fetus. MRI: midgut malrotation. Laparotomy done. Obstruction was due to Ladd's band. Ladd's procedure done. At her 38weeks she delivered a male baby vaginally. Ladd's bands create an obstruction of the duodenum. Most cases of intestinal obstruction during pregnancy result from pressure of the growing uterus. A surgical operation called a Ladds procedure is performed.The possibility of a congenital band must be included in the differential diagnosis of patients with symptoms and signs of bowel obstruction and no history of abdominal surgery, trauma. A reluctance to operate during pregnancy adds unnecessary delay, which increases morbidity for both mother and fetus. Often vomiting is misdiagnosed as hyperemesis,such misdiagnosis should be avoided as prompt diagnosis and appropriate therapy are crucial.

KEYWORDS Intestinal obstruction,pregnancy, ladd's band,ladd's procedure.

INTRODUCTION:

Intestinal obstruction in pregnancy is rare with incidence of 1:1500-1:66431 pregnancies[1]. Intestinal obstruction in pregnancy carries significant maternal (6%) and fetal (26%) mortality [2]. Often, this is due to delay in diagnosis and treatment. This case is reported because of its rarity and successful fetal and maternal outcome.

CASE REPORT:

A 30year old G3A2 patient,who had a complete abortion at 6weeks. In her second pregnancy at 21 weeks she was referred to us as a case of acute renal failure due to increased vomiting with intra uterine fetal demise.she was taken up dialysis. She improved within 24 hours after expulsion of fetus.

Now, in third pregnancy at her 23weeks of gestation, she again presented with vomiting and was dehydrated, same as in her second pregnancy. Lab investigations showed elevated renal function test.She had no prior surgical his-

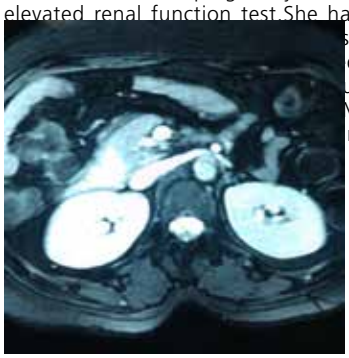

showing, dilated stom-
d peristalsis. Live fetus
us ryles tube aspiration
MRI was taken fig(1)(2)
nal obstruction due to

Fig.1 superior mesenteric artery and vein relationship altered,with whorling of mesenteric vasculature.

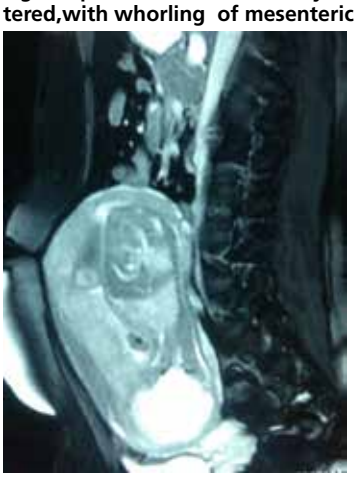

Fig2 collapsed small bowel loops. Fetus in utero.

Emergency laparotomy done. Obstruction was due to Ladd's band. Ladd's procedure done. Post-op period was uneventful. She was discharged on ninth post-op day. At her 38weeks she delivered a male baby vaginally.

DISCUSSION:

Intestinal obstruction in pregnancy is uncommon. Symptoms of intestinal obstruction in pregnancy include: abdominal pain (98%), vomiting (82%), constipation (30%). Congenital bands are a rare cause of intestinal obstruction. Their occurrence in adults is an extremely rare condition.[3] Obstruction is caused by entrapment of the intestine between the band and mesentery or by compression of the bowel.

Ladd's bands, sometimes called bands of Ladd are fibrous stalks of peritoneal tissue that attach the cecum to the abdominal wall, and create an obstruction of the duodenum. This condition is found in malrotation of the intestine. Most cases of intestinal obstruction during pregnancy result from pressure of the growing uterus . This more likely occurs around midpregnancy, when the uterus becomes an abdominal organ [(2)] .

A surgical operation called a "Ladd procedure" is performed to alleviate intestinal malrotation. The procedure involves surgical division of Ladd's bands, widening of the small intestine's mesentery, performing an appendectomy and correctional placement of the cecum and colon. Mortality rates with obstruction during pregnancy can be excessive because of difficult and delayed diagnosis, reluctance to operate during pregnancy, and the need for emergency surgery[(4)] .

CONCLUSION:

The possibility of a congenital band must be included in the differential diagnosis of patients with symptoms and signs of bowel obstruction and no history of abdominal surgery, trauma. This clinical situation requires early surgical intervention that will be diagnostic and therapeutic. A reluctance to operate during pregnancy adds unnecessary delay, which increases morbidity for both mother and fetus. Often vomiting is misdiagnosed as hyperemesis and it ends up in renal failure and death. Such misdiagnosis should be avoided as prompt diagnosis and appropriate therapy are crucial.

REFERENCES

1.H. T. Sharp, "The acute abdomen during pregnancy," Clinical Obstetrics and Gynecology, vol. 45, no. 2, pp. 405–413, 2002. PMID:12048399. | 2.Davis MR, Bohon CJ: Intestinal obstruction in pregnancy. Clin Obstet Gynecol 26:832, 1983. | 3. Habib E, Elhadad A. Small bowel obstruction by a congenital band in 16 adults. Ann Chir. 2003;128:94–7. [PubMed]. | 4. Firstenberg MS, Malangoni MA: Gastrointestinal surgery during pregnancy. Gastroenterol Clin North Am 27:73, 1998. |