Research Paper Medical Science

Prospective Study of Fine Needle Aspiration Cytology of Lymph Nodes of The Head And Neck Region over a 2 Year Period with Histopathological Correlation

Dr.Satish Arakeri Assistant professor, Department of Pathology, DMWIMS, Naseera nagar, Meppadi (PO), Kalpetta, Kerala-673577 India

Dr.Gandhi N Professor, Department of pathology, MVJ Medical college and research hospital, Hoskote- Bangalore, Karnataka. 562114.

ABSTRACT

Introduction: Fine needle aspiration cytology (FNAC) is a simple, quick and inexpensive method used to sample lymph nodes found in the head and neck region.1,2 Aims:1) To study the different cytomorphological patterns of FNAC associated with lymph nodes in the head and neck region. [2]) To correlate the FNAC findings with histopathology. 3) To evaluate the sensitivity and specificity using histopathology as the gold standard. Material and methods: FNAC of 100 cases of lymph node swellings of head and neck region is included. 20 cases have histopathological correlation. Results: Cervical group of lymph nodes are most common presentation in both benign and malignant condition. Reactive lymphadenitis and metastasis are the most common benign and malignant condition respectively. Overall accuracy and sensitivity was 90% and 100% respectively[3,4], Conclusion: FNAC is a very useful and accurate approach in diagnosing various benign and malignant lymphadenopathies.

KEYWORDS FNAC, Lymph node, Head & neck

INTRODUCTION

Lymphadenopathy is one of the commonest clinical presentations of all age groups attending Out Patient Departments. The etiology can vary from an inflammatory process to a malignant condition. Most common tool used in the present day is Fine needle aspiration cytology.[1,2]

Fine needle aspiration cytology (FNAC) is the study of cells and other tissue components obtained by sampling of a palpable superficial lesion or radiologically localized deep seated lesion through a small gauge needle. FNAC is used routinely as a first line of investigation in the evaluation of patients with lymphadenopathy. Enlarged lymph nodes are one of the oldest indications for FNAC. This diagnostic modality has gained considerable importance in the management of patients with lymphadenopathy over several years.[1,2]

MATERIALS AND METHODS

Source of data:

All the patients with enlarged lymph nodes clinically, attending the M.V.J Medical College Hospital and Research Hospital, Hoskote, Bangalore was included in the study.

Inclusion criteria:

All superficial lymph node swellings of the head and neck region

Exclusion criteria:

1. All non-lymphoid aspirates from the head and neck region
2. Inadequate aspirate

Materials.

1. 5ml/10ml disposable syringe
2. 22-26 gauge needle
3. Cameco syringe holder
4. Clean non grease glass slide
5. Cotton swab
6. Methylated spirit
7. 95% ethyl alcohol in coupling jars
8. Haematoxylene & Eosin stain
9. Giemsa stain.

Method:

A total of 100 patients were included in our study, referred from the department of Medicine, Pediatrics, Surgery, ENT, Chest Medicine and Tuberculosis. The skin over the lymph node to be aspirated is cleaned and disinfected. Lymph node is fixed in the left hand between index finger & thumb. A 24 gauge needle attached to syringe is mounted in the cameco syringe holder and introduced into the lymph node. A vacuum is created in the syringe by pulling back the plunger. Needle is carefully moved in different directions to dislodge the material.

When adequate material is aspirated into the syringe, suction is gently released to equalize the pressure. This prevents sucking of aspirated material into the barrel of syringe. Aspirated material is well spread on the slides. 2-3 wet slides are fixed in 95% ethyl alcohol used for staining with Haematoxylene-Eosin stain and Papanicolaou stain. Air dried smear used for doing Giemsa stain. Few slides for special stains wherever required eg. AFB for tuberculosis etc. Examine the slides under microscope. Immunohistochemistry has been done in our department in cases of Lymphoma to confirm the diagnosis. The markers used are CD15, CD30, CD19, CD20, and CD3.

Results and Discussion:[10,11,]

In our study, cervical lymphadenopathy is the most common among all the lymph nodes of the Head and Neck region. The sex ratio of the lymphadenopathy of the Head and Neck region is M: F= 1: 1.2. The benign lymphadenopathy of the Head and Neck region is more common in 3rd decade whereas malignant lymphadenopathies are more common in 6th decade. Out of 100 cases, 20 cases had excision biopsies which were sent for histopathological study. Benign lymphadenopathy is the most common presentation of lymphadenopathy of the Head and Neck region amounting to 77% of all. . Among benign lesions, Non-specific reactive lymphadenitis (FIG 1A) is the most common findings of enlarged lymph nodes of the Head and Neck region amounting to 48%, followed by granulomatous lymphadenitis amounting to 32% and tubercular lymphadenitis (FIG 1B) includes 20%, malignant lesions forms 23% of all the cases undergone FNACs' of the Head and Neck region. Among 23 cases, 4 were primary malignancies. Three cases were diagnosed as Hodgkin's lymphoma(FIG 1C) and one case as Non-Hodgkin's lymphoma on cytology. Rests of the 19 cases were metastases (FIG 1D) to the lymph nodes. Out of total 100 cases, 19 cases were found to have metastatic tumor cells. 17 cases were diagnosed as metastat-

ic squamous cell carcinoma and 2 cases were diagnosed as poorly differentiated carcinoma.

TABLE 1: Cytopathological diagnosis of FNAC of lymph nodes.[11,10]

CYTOPATHOLOGICAL DIAGNOSIS	NUMBER OF CASES	% OF CASES	GENDER		AGE RANGE (YRS)
			MALE	FEMALE	
BENIGN LESIONS					
Non-specific reactive lymphadenitis	37	37 %	16	21	2.5 – 60
Granulomatous lymphadenitis	24	24 %	11	13	8 – 75
Tubercular lymphadenitis	15	15 %	04	11	13- 55
Rosai -Dorfmann disease	01	01 %	01	00	21
MALIGNANT LESION					
Hodgkin's lymphoma	03	03 %	01	02	12- 72
Non-Hodgkin's lymphoma	01	01 %	00	01	24
Metastases	19	19 %	13	06	27 – 82
TOTAL CASES	100	100 %	46	54	2.5 – 82

FIGURE 1: FNAC smear of Non specific reactive lymphadenitis of lymph node showing mixed population of reactive lymphoid cells. (H&E X 400)

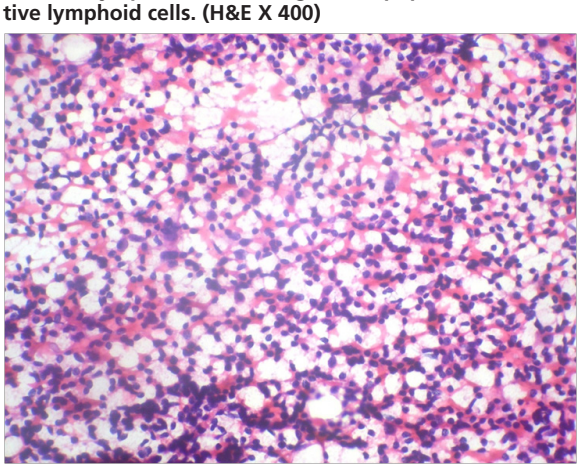

FIGURE 2: FNAC smear of tubercular lymph node showing granuloma consists of epitheloid cells, fibroblast, lymphocyte and necrosis. (H&E 400).

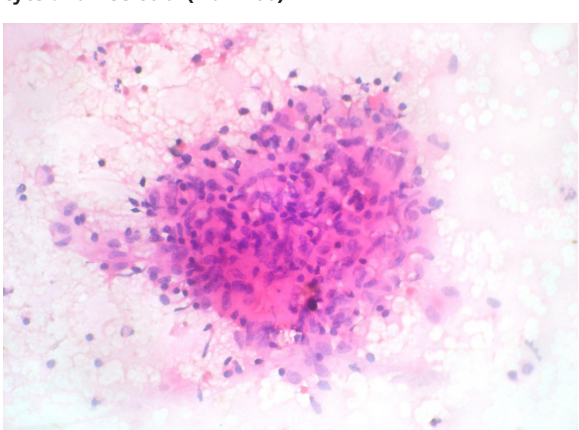

FIGURE 3: FNAC smear of lymph node of Hodgkin's lymphoma showing Classical Reed-Sternberg cell. (MGG 1000).

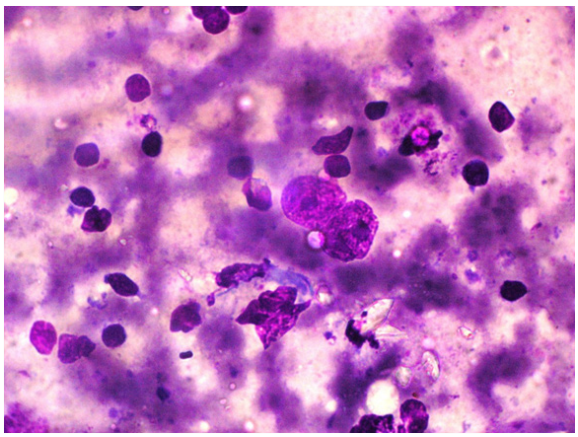

FIGURE 4: FNAC smear of metastatic lymph node showing tumor cells of squamoid type in a background of lymphoid cells. (H&E 100).

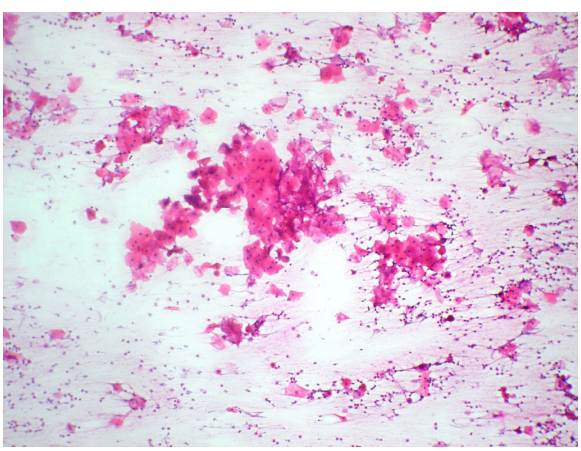

Out of 100 cases, 20 cases have histopathological correlation which is discussed below.

TABLE 2 Table demonstrating FNAC diagnosis with histopathological diagnosis.[4,6,7,9,10]

CYTOLOGICAL DIAGNOSIS	NUMBER OF CASES	HISTOPATHOLOGICAL DIAGNOSIS	NUMBER OF CASES
Non-specific reactive lymphadenitis	05	Non-specific reactive lymphadenitis	03
		Tubercular lymphadenitis	01
		Lymphoproliferative disorder	01
Granulomatous lymphadenitis	08	Non-specific reactive lymphadenitis	01
		Tubercular lymphadenitis	06
		Non-Hodgkin's lymphoma	01
Tubercular lymphadenitis	03	Tubercular lymphadenitis	03
Hodgkin's lymphoma	02	Hodgkin's lymphoma	02
Non-Hodgkin's lymphoma	01	Hodgkin's lymphoma	01
Metastases	01	Metastases	01
TOTAL CASES	20		20

TABLE 3: Statistical analysis of the malignant and benign diagnosis from the data available for correlation

STATISTICAL INDICES	PERCENTAGE %
Sensitivity	100 %
Specificity	66.66%
Percentage of False Positive	25%
Percentage of False Negative	00
Positive Predictive Value	87.5
Negative Predictive Value	100 %
Accuracy	90%

Conclusion:

Cervical group of lymph nodes is the most common presentation in both benign and malignant condition. Non-specific reactive lymphadenitis is the most common benign pathology associated with enlarged lymph nodes whereas metastasis is the most common malignant condition. The sensitivity and specificity of FNAC is fare enough with lot of various other advantages like rapid diagnosis, reliable, less traumatic, minimal complication, repeatability, economical and convenient.

REFERENCES

1. Ioachim HL, Medeiros JL. Ioachim's lymph node pathology, fourth edition, Lippincott Williams Wilkins, 2008. | 2. Orell SR, Sterer GF, Whitaker D. Fine needle aspiration cytology, 4th edition, Chirchill Livingston, 2005; 1-8 and 83-124. | 3. Buley ID. Fine needle aspiration of lymph nodes. Journal of clinical pathology 1998; 51: 881-885. | 4. Rosai J. Rosai and Ackerman's surgical pathology, volume 2, 9th edition, Elsevier 2004; 1877-2018. | 5. Bagwan IN, Kane SV, Chinoy RF. Cytologic evaluation of the enlarged neck node: FNAC utility in metastatic neck disease. The Internet Journal of Pathology2007; 6(2):13-17. | 6. Das DK.Value and limitations of Fine needle aspiration cytology in diagnosis and classification of lymphomas: A review. Diagnostic Cytopathology 1999; 21(4):240-249. | 7. Prasad RR, Narasimhan R, Sankaran V,Veliath AJ. Fine needle aspiration cytology in the diagnosis of superficial lymphadenopathy: An analysis of 2,418 cases. Diagnostic Cytopathology 1996; 15(5):382-386. | 8. Steel BL, Schwartz MR, Ramzy I. Fine needle aspiration biopsy in the diagnosis of lymphadenopathy in 1,103 patients. Role, limitations and analysis of diagnostic pitfalls. Acta Cytologica 1995; 39(1): 76-81. | 9. Lee J. Usefulness and limitations of fine needle aspiration cytology in adult cervical lymph node enlargement patients: an analysis of 342 cases. Tuberc Respir Dis, Jan 2004; 56(1): 18-28. | 10. Shamshad Ahmad S, Shakeel A, Kafil A, Shano N, Tariq M. Study of fine needle aspiration cytology in lymphadenopathy with special reference to acid fast staining in cases of tuberculosis. JK science, Jan-Mar 2005; 7(1):1-4. | 11. Rashmi K, Charanjeet A, Varun S. Diagnosis of sinus histiocytosis with massive lymphadenopathy (Rosai-Dorfman Diasease) by fine needle aspiration cytology. Journal of Cytology 2009; 26(2):83-85. |