Research Paper Medical Science

Right Transverse Sinus Thrombosis Presenting with Bilateral Abducens Palsy A Case Report

DR.FARAH NAAZ	PG Resident, Department Paediatrics, Government Medical College, Kota
DR.HIMANSHU GOYAL	PG Resident, Department Paediatrics, Government Medical College, Kota
DR.R.K GULATI	Professor& Head of department Paediatrics, Government Medical College, Kota
DR.HEMANT JAIN	Assistant Professor, Department Paediatrics, Government Medical College, Kota
DR.GOPIKISHAN	PG Resident, Department Paediatrics, Government Medical College, Kota

ABSTRACT

Transverse sinus thrombosis is a known but uncommon intracranial extradural complication of CSOM. Even rare is simultaeneous occurrence of bilateral abducens palsy in the same patient.We report a case of 9 month old infant who presented with complaints of headache vomiting diplopia and bilateral abducens palsy with MRI revealing transverse sinus thrombosis.Patient was treated with thrombolytics and antibiotic therapy.

KEYWORDS transverse sinus thrombosis,, bilateral abducens palsy

INTRODUCTION

Cerebral venous sinus thrombosis is a rare condition . Although recognized for more than 100 years,[1] it has only in recent years come to be diagnosed frequently ante-mortem. This is partly due to greater awareness among physicians and neurologists, and partly to improved non-invasive imaging techniques. its clinical presentation is extremely variable and life-threatening [1,2]. The most frequent symptoms and signs are headache (95%), focal seizures with or without secondary generalization (47%), unilateral or bilateral paresis (43%) and papilledema (41%) [3]. Patients who are at risk of developing venous thrombus formation are those with hypercoagulable states, dehydration, adjacent infectious processes, low cerebral blood flow, oral contraceptives, hormone replacement therapy .We report a case of Transverse sinus thrombosis presenting with bilateral abducens palsy in a 9 month old child.

CASE REPORT

A 9 month male child presented with complaints of recurrent vomitings, headache followed by fever anemia and bilateral convergence of eyes.There were complaints of frequent upper airway infections.Extraocular muscle examination revealed bilateral abducens palsy.(fig 1)



Fig 1: revealing bilateral abducens palsy

Fundus examination revealed bilateral optic disc margins blurring suggestive of Papilledema. Other cranial nerves were normal.There were no peripheral neurological signs. 2 d echo and coagulation profile was normal.

MRI brain revealed-Absence of normal flow void in region of right transverse sinus.{fig 3 &4}

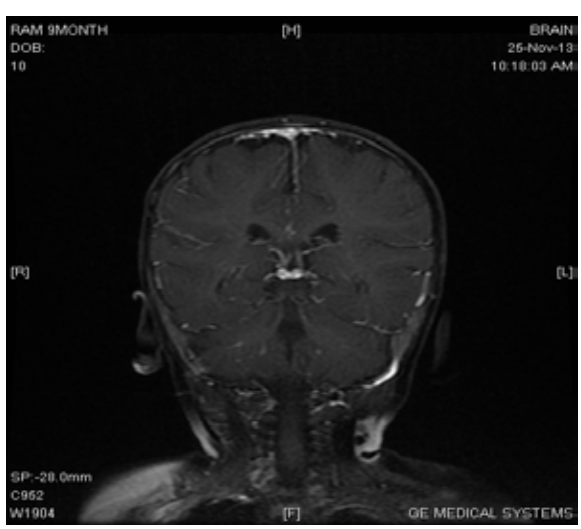

Fig 2

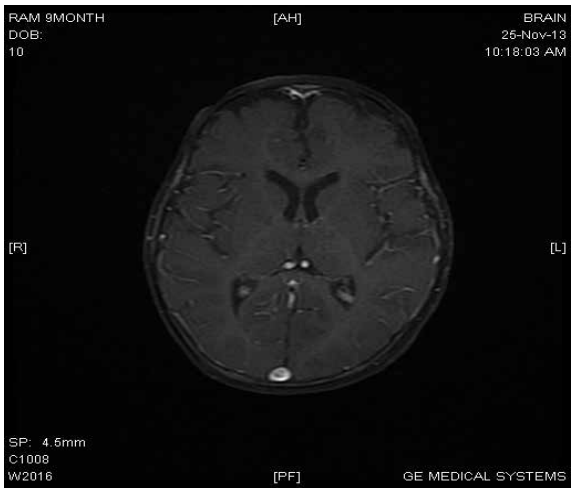

Fig 3

FIG 2 & 3 :showing right transverse sinus thrombosis

DISCUSSION

Although occurence of Transverse sinus thrombosis has declined considerably with advent of new genre of highly efficacious antibiotics , this sinister condition is still associated with mortality and morbidity 10% and 30% respectively(4,5).

Etiopathogenesis is primarily related to spread of infection to sigmoid sinus through a coalescent or cholesteatomal bone erosion causing formation of perisinua abcess.

Transverse sinus thrombosis can also be caused by a osteothrombophlebitis phenomenon. Hypercoagulable atates , inherited (antithrombin third) protein c or protein s deficiency. Or a acquired neoplasm or trauma are a risk factor for transverse sinus thrombosis(6)

The neurological manifestation of cavernous sinus thrombosis and transverse sinus thrombosis may be a vague symptom of vomiting ,headache , seizures or stroke like manifestation of chronic intracranial hypertension like blurring of vision.(7) .MRI is very sensitive for this than CT scan on account of ability to show low or absent flow in venous sinus , clot formation and presence of inflammation in meninges.

CONCLUSION.

Transverse sinus thrombosis is considered an unsual complication of otitis media and other hypercoagulable states requiring accurate diagnosis , recognition and treatment. Imaging is essential to form a diagnosis and plan for strategy. Management of Transverse sinus thrombosis is controversial but usually consists of conservative surgeries combined with IV antibiotics. Anticoagulant therapies are also proposed now a days.

REFERENCES

1.)Bousser MG. Cerebral venous thrombosis: nothing, heparin or local thrombolysis. Stroke1999; 30:481–3 | 2.)Cantu C, Barinagarrementeria F: Cerebral venous thrombosis associated with pregnancy and puerperium: review of 67 cases. | Stroke 1993, 24:1880-1884. PubMed Abstract | Publisher Full Text OpenURL | 3).Lim YH: Aseptic cerebral venous sinus thrombosis in early pregnancy. | Hong Kong J Emerg Med 2007, 14:237-239. OpenURL | 4.)de Bruijn SFTM, de Haan RJ, Stam J, for the Cerebral Venous Sinus Thrombosis Study Group: Clinical features and prognostic factors of cerebral venous sinus thrombosis in a prospective series of 59 patients. | J Neurol Neurosurg Psychiatry 2001, 70:105-108. PubMed Abstract | Publisher Full Text | PubMed Central Full Text | 5).C.Biarchini C.Aimani , A martini "Lateral sinus thrombosis as a complication of acute mastoiditis". | Otorhinolaryngologica Italica vol.28no.1 pp.30-33 2008 | 6).M.iseri ,O.aydin, E.ustundag, A.almac," Management of lateral sinus thrombosis in CSOM" | "Otology and neurology"vol.27 no.8 pp1098 -1103,2006 | 7)Bradly DT, Ha Shia saki gt, Mason JC ," otogenic sigmoid s thrombosis | :what is the role of anticoagulation?laryngoscope 2002:112:1726 (pubmed) | 8) V.caso, A.angelli, M.Paciaroni.Handbook of CVT kranger 2008 | Stam J Thrombosis of cerebral veins and sinuses.NEJM 2005 352 1791-8 |