Research Paper Medical Science

Umbilical Pilonidal Sinus- A Rare Clinical Occurence

*** Uroos Fatima**	Associate Professor, Deptt. Of Pathology, DMWIMS, Naseera Nagar, Mepaddi, WAYANAD, KERALA. * Corresponding Author
Yogesh Kumar Yadav	Assistant Professor, Deptt. Of Pathology, Integral Institute of Medical Sciences and Research, LUCKNOW,UTTAR PRADESH.

ABSTRACT

Pilonidal Sinus disease is a recurrent, chronic disorder that is observed most commonly in sacrococcygeal region. It can occur in periumbilical region also but umbilical presentations are rare . Only few cases of Umbilical pilonidal sinus have been reported in literature.(1)Here, we report a case of umbilical sinus in male who was treated by umbilectomy and finally diagnosed on histopathology. The present paper recapitulates its clinical presentation, microscopy and treatment.

KEYWORDS umbilicus, sinus, pilonidal

INTRODUCTION

Pilonidal sinus is a chronic recurrent disease characterized by a granulomatous response to hair shaft penetrating epidermis from the cutaneous surface.[1]Its most common site is sacrococcygeal region but has been observed in periumbilical region as well[2].Underlined predisposing factors like male sex with a hairy body, deep naval, young age, poor personal hygiene have been outlined but the exact etiology of this disease still remains unknown(3). Possible causes such as cases of recurrent, resistant omphalitis(4) or congenital occurrence (5) have been suggested in etiopathogenesis. More aggressive treatment of umbilical pilonidal sinus has been advocated as compared to its sacrococcygeal counterpart because of risk of peritoneal extension of inflammation. A definite diagnosis of this condition is therefore necessary.

CASE REPORT

A 42 year old male patient reported on surgical side with a two year history of intermittent, seropus ,blood mixed discharge from umbilicus alongwith pain, tenderness and swelling in the area. Repeated antibiotic treatments had failed to provide relief to the patient.He complained of mild abdominal pain also but any intraabdominal lesion was ruled out by sonography. Past history revealed UTI one year back for which he took adequate treatment . On examination the patient had a hairy body .The umbilicus was everted with serohaemorrhagic discharge from the sinus and the opening was covered with exudate. Both Laboratory and sonography findings did not yield any significant abnormality. The patient was advised umbilectomy to which he gave his consent.

HISTOPATHOLOGICAL FINDINGS

Gross:An umbilectomy specimen measuring 4.0x3.0x2.0 cms was received . An everted umbilicus with a sinus opening covered with skin and underlying subcutaneous tissue was identified. Cut surface showed the sinus tract leading to a well defined circumscribed cavity located 2.5 cm from the skin surface, measuring 1.0cm in diameter . The cavity was filled with hair and necrotic material. Subcutaneous fat showed areas of congestion.(Fig 1)

Microscopic sections showed keratinized stratified squamous epithelial lining of the sinus tract ending into the cavity. The cavity showed edematous fibrocollagenous tissue with eccrine glands embedded in loose myxoid stroma along with hair follicles and hair shafts. Surrounding stroma showed dense inflammatory cell infiltrate comprising lymphocytes, plasma cells, histiocytes , few polymorphs and proliferating congested vessels . Numerous foreign body type giant cells were also seen around hair shafts.(Fig 2) Inflammatory foci was seen extending into the subcutaneous tissue.

DISCUSSION

Pilonidal sinus disease is a common problem of sacrococcygeal region (1). It is caused by hair penetrating skin causing a foreign body reaction and development of sinus lined by granulation tissue. Initially the patient may be asymptomatic but later on develop swelling, pain and discharge. The complaint may be recurrent.

Pilonidal sinus of umbilicus is rarely reported[6],fewer than 20 cases have been reported before 1980[7].The disease is most often seen in young white males with dark, straight hair.Although, congenital anomalies related to the closure of neural canal can certainly occur in this area, it is now believed that large majority of pilonidal sinuses have an acquired pathogenesis.(8)The most common symptoms of this condition described in a study are umbilical pain(100%), bloody discharge(69%), purulent discharge(23%), and umbical mass(26%).(1)Our patient presented with all the above symptoms.

The differential diagnosis of umbilical swelling like umbilical hernia, epidermoid cyst, endometriosis, metastatic tumors, urachus, pyogenic granuloma and congenital abnormalities are more commonly encountered in clinical practice. Yet, closer inspection of the sinus and presence of deep seated hair in the cavity will make diagnosis of this condition easier. Sometimes simple extraction of hair from the sinus will relieve symptoms in most patients.Occasionally, incision and drainage of an abscess may be necessary.[6]

There is no consensus about treatment of pilonidal umbilicus sinus disease, however, failure of conservative methods of hair extraction and appropriate personal hygiene leads to compounding of the problem being recurrent ,which makes surgery as an inevitable option[1,9]. Though , umbilectomy has been advised for cessation of recurrence[1,6] yet excision of sinus tract with reconstruction surgery can be advised and has been performed.(9,10).

CONCLUSION

In summary, we report a case of recurrent discharge from umbilicus in a middle aged patient who was later treated by umbilectomy and diagnosed as a case of Umbilical Pilonidal Si-

nus on histopathology. The present paper recapitulates microscopic features and treatment of this rare disease. Its diagnosis is essential to prevent ,the more alarming peritoneal spread of this infection and inflammation.

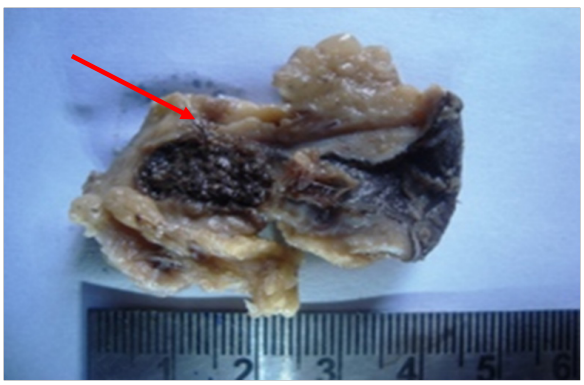

Figure 1 : specimen showing centrally located brownish nodular area with hair surrounded by necrotic material (➔)

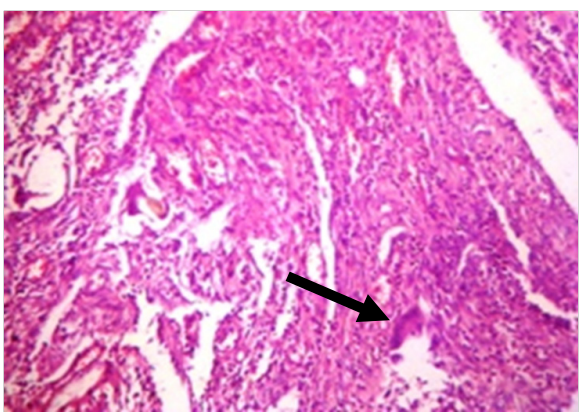

Figure 2 : H&E stained section from the tissue showing hair shaft surrounded by chronic inflammation and multinucleated giant cell(➔).(40x)

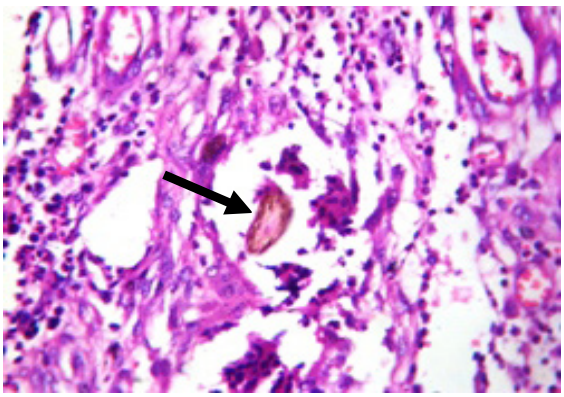

Figure 3: H&E stained section showing hair shaft (➔) surrounded by multinucleated giant cells.(400x)

REFERENCES

1.EryilmazR,SahinM,Okan I, Alimoglu O, Somay A. Umbilical pilonidal sinus disease:predisposing factors and treatment.World J surg.2005;29(9):1158-1160. | 2.Hull TL, Wu J.Pilonidal disease.Surg Clin North Am.2002;82(6):1169-1185. | 3.Gupta S,Sikora S,Singh M, Sharma L: Pilonidal disease of the umbilicus-a report of two cases. Jpn J Surg 1990;20: 590-592 | 4.Colapinto ND: Umbilical pilonidal sinus. Br.J Surg 1977;64:494-495 | 5.Tocchi A, Liotta G, Agostini N, Maggiolini F: The umbilical pilonidal cyst: a case report. Comments on its etiopathogenesis and treatment. G.Chir 1994;15:33-36 | 6.Sroujieh AS, Dawoud A: Umbilical sepsis. Br J Surg 1989;76:687-688 | 7.McClenathan JH:Umbilical pilonidal sinus. Can J Surg 2000;43:225 | 8.Kabay S, Olgun EG, Yucel M, Yaylak F, Hacioglu A. A rare case of pilonidal sinus of the umbilicus.Central European Journal of Urology 2009;62(2):116-117 | 9.Fazeli MS, Lebaschi AH, Adel MG, KAzemeini AR. Evaluation of the outcome of complete sinus excision with reconstruction of umbilicus in patients with umbilical pilonidal sinus. World J Surg.2008;32(10):2305-2308 | 10. Akkapulu N, Tanrikulu Y. Umbilical Pilonidal Sinus:A Case Report. J MedCases.2011;2(6):272-274. |