Research Paper Medical Science

Rudimentary Thymus In A Case Of Potter's Syndrome

Dr. Prasenjit Bose Department Of Anatomy, Institute Of Medical Sciences, Banaras Hindu University, Varanasi, Uttar Pradesh, 221005, India.

Dr Royana Singh Associate Professor, Department Of Anatomy, Institute Of Medical Sciences, Banaras Hindu University, Varanasi, Uttar Pradesh , 221005, India.

Dr. Anjali Rani Assistant Professor , Department of Obstetrics and Gynaecology, Hindu University, Varanasi, Uttar Pradesh , 221005, India

ABSTRACT

Potter syndrome refers to a group of characteristic facial findings associated with lack of amniotic fluid and kidney failure in an unborn infant . It is related to a chain of events that may have different beginnings (absent kidneys,cystic kidneys,obstructed ureters),but which all end with the same conclusion (oligohydramnios).Rudimentary thymus is a rare finding in Potter syndrome.We report here a case of 20 weeks old male fetus with Potter syndrome, who had polycystic kidneys, hypoplastic lungs, hepatomegaly, intestinal obstruction and most interesting finding was rudimentary thymus which is a rare finding.

KEYWORDS Potter syndrome, Polycystic kidneys, Hepatomegaly, Rudimentary thymus, Pulmonary Hypoplasia.

Introduction

In the year 1946, Edith Potter described a series of 20 cases with absent kidneys, noting the characteristic appearance of lungs and head (Potter,1946). She found out that all these cases have one common finding that is oligohydramnios and it was due to absent kidneys. Potter symdrome is a rare disorder with an incidence of 1 in 4,000 births with predominance in males (Potter, 1946) (Thomas, 1974). It is accompanied by severe oligohydramnios, renal abnormalities (bilateral renal agenesis, severe hypoplasia, dysplasia, polycystic kidney, and obstructive uropathy), or chronic leakage of amniotic fluid (oligohydramnios sequence) during middle gestational weeks. Renal failure is the main defect in Potter's syndrome. Later it was proved that the pressure effect of growing uterus without the presence of the amniotic fluid upon the fetus resulted in the typical facial appearances and the position of the limbs. The presence of the typical facial appearance is also known as Potter phenotype (Thomas , 1974) (Robertson and Rennie, 1999) (Kleinman, 1992).

Potter's syndrome occurs in sporadic and autosomal recessive forms (Robertson and Rennie 1999) (Kleinman 1992). The Potter syndrome can be classified into five types-1. Classic Form: In this the infant has bilateral renal agenesis. This is the most common type.2. Type I: It is due to Autosomal Recessive Polycystic Kidney Disease. Mainly associated with fibrosis or cystic changes of liver and pancreas.3. Type II: In this one kidney is absent and the other is small and malformed.4. Type III: It is due to Autosomal Dominant Polycystic Kidney Disease. Linked to mutation in genes PKD1 and PKD2. Mainly associated with hepatic cysts and enlarged spleen.5. Type IV: This occurs when a longstanding obstruction in either the kidney or ureter leads to hydronephrosis.

Other characteristic features include premature birth, breech presentation, a typical facial appearance (Potter's facies), and limb malformations. Most infants are still born or if live born die due to severe respiratory insufficiency. Clinical and Ultrasonography findings along with a positive family history are diagnostic features of the Potter's syndrome (Bain et al ,1964) (Scott and Goodburn, 1995).

Though Potter's syndrome is rare but we suggest that it may be more common because infants are stillborn , die soon after birth or most of the women in this region still do no go for hospital delivery.

Case Report

A female patient of Indian origin on routine examination for amenorrhea of 20 weeks visited the Department of Obstetrics and Gynaecology. She had undergone abdominal sonography. USG report confirmed polycystic kidneys in the developing fetus, thus mother was advised termination of pregnancy. Termination was done under aseptic procedures.

After taking proper consent from parents, the fetus was procured by the Department Of Anatomy. On external features examination, the foetus was a male with well-developed penis and scrotal sac.The typical facial appearance of potter phenotype was observed. It had widely separated eyes, broad nasal bridge,flattened nose low set ears and micrognathia {Fig 1.Arrow (white)}.The following findings were observed after autopsy:thorax; hypoplasia of both lungs, well-developed heart and arterial branches (Fig. 1 black arrow) and most interestingly the rudimentary thymus. Abdominal cavity exhibited hepatomegaly with embedded gallbladder (Fig. 1.black arrow), intestinal obstruction showing dilated loop of the duodenum, meckel's diverticulum the differentiation of the gastrointestinal tract with colon atresia . Both the kidneys were polycystic , the left being small than that of right kidney. The ureters of both the side descended down to open into the posterior aspect of the urinary bladder. The lower abdominal cavity had two well-developed testis (Fig. 1).



Fig 1.The typical facial appearance of potter phenotype of the fetus , widely separated eyes, broad nasal bridge, flattened nose low set ears and mircognathia (white arrow). hepatomegaly with embedded gallbladder (black arrow) intestinal obstruction showing dilated loop, polycystic kidneys (black arrow), and hypoplasia of both lungs (black arrow), the rudimentary thymus.

Histological section of liver, kidney, pancreas and thymus were subsequently done The liver and the pancreas histological section showed fibrosis with few cystic spaces(Fig.2).

The thymus showed lymphocytes scattered within the parenchyma. Both the kidneys showed dilated pelvis , obliteration of the minor calyces. Undifferentiated glomerulus, extensive fibrosis and cystic spaces.

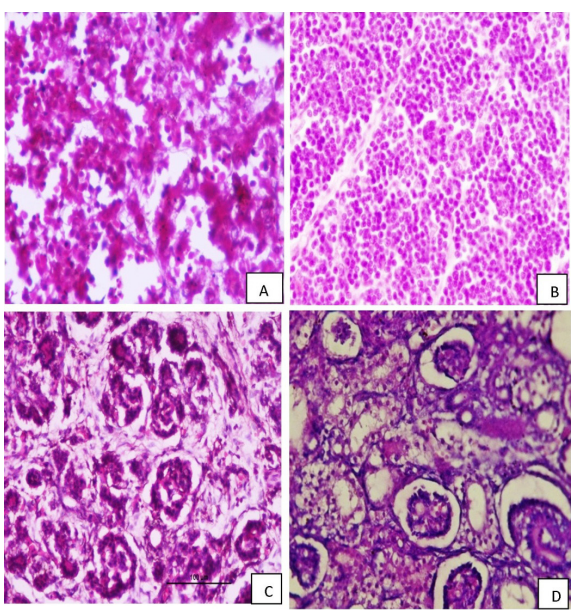

Fig.2 . Microphotograph of Potter syndrome foetus A. Thymus section , B. liverfoetal hepatocytes with fibrosis ,C. Pancreas section illustrating acinus with extensive fibrosis and cyst and D. Polycystic Kidney showing disarranged glomeruli and multiple cystic spaces.

On the basis of the external and internal examination ,we came to the conclusion that it was type I Potter phenotype.

Discussion

Potter's syndrome is found in 0.2% to 0.4% of the stillborn infants and is incompatible with life outside the uterus and thus die soon after birth (Scott and Goodburn 1995) (Dayal et al ,2003).The male to female ratio was 2:1 (Khatami, 2004). The characteristic feature of Potter syndrome includes facial features ; hypertelorism, Mongolian palpebral fissure, epicanthal fold, specific suborbital crease, depressed nasal bridge, parrot-beak nose, posteriorly rotated low-set ears, receding small chin, a crease below lower lip, bow legs, clubfoot, hip dislocation, wide and broad hands, and a short neck (Dayal et al, 2003).The non-renal features of Potter's syndrome includes altered facies, aberrant hand and foot positioning , late foetal growth deficiency, and pulmonary hypoplasia, which are known as the oligohydramnios tetrad, as they are the consequence of foetal compression due to prolonged oligohydramnios (Bain et al ,1964)(Scott and Goodburn, 1995).

During nephrogenesis, the essential interaction between the ureteric bud andmetanephric mesenchyme is controlled by genes, transcription factors, and growth factors (Khatami, 2004).The genetic disorder often occurs prior to day 31 of fetal development. The ureteric bud which forms the kidneys fails to develop and the absence of the kidneys causes a deficiency of amniotic fluid after the weeks 12 to 16.4 (Schuardt et al , 1996)(Moore et al , 2007) Renal agenesis when accompanied by these characteristic features called "Potter's phenotype". This genetic disorder occurs in males twice as often as in females and is more common in infants with a positive family history of kidney malformation..

Potter syndrome can also be seen in infants with normal kidneys due to the prolonged leakage of amniotic fluid during the middle gestational weeks (Khatami, 2004) Scott and Goodburn,(1995) found no renal malformations in 50% autopsied second or third trimester fetuses with the features of Potters syndrome.There was a high incidence of chorioamnionitis,suggesting that the mechanism of oligohydramnios was occult amniotic fluid leakage. The presence of polycystic kidneys hepatomegaly and splenomegaly are also not uncommon (Potter,1946) (Khatami, 2004) But rarely do we find the rudimentary thymus which we have seen in this case

Conclusion

In Potter's syndrome,the typical facial characteristics and associated pulmonary hypoplasia of the neonates occur as a result of oligohydramnios due to renal pathology. Death occurred mostly due to severe respiratory insufficiency.In high risk pregnancies,a mid gestation ultrasonography examination is advised for the amount of amniotic fluid,the fetal kidneys and the urinary tract.This reported case was fatal as it was associated with polycystic kidneys,hypoplasia of lungs, intestinal obstruction and rudimentary thymus. By presenting this we recommend prenatal diagnosis of all high risk pregnancies.

REFERENCES

1. PotterE.L. (1946). Facial characteristics of infants with bilateral renal agenesis.Am J ObstetGynecol, 51, 885-888. | 2. Thomas., T. L. (1974). Oligohydramnios, cause of the nonrenal features of Potter's syndrome, including pulmonary hypoplasia. . Journal ofPaediatrics, 84(6), 811-814. | 3. Robertson N.R.C., Rennie J. M. (1999). Textbook of Neonatology. (3rd ed.): Churchill Livingstone; | 4. Kleinman L.I., Stewart C. L., Kaskel F. (1992). Renal disease in the newborn.In: Edelman CM, ed. Pediatric Kidney Disease (2nd ed., pp. 1044): London: Little Brown. | 5. Bain A.D., Smith I. I., Gauld I. K . (1964). Newborn after the prolonged Leakage of liquoramnii. Brit.Med. J., 2, 598-599. | 6. Scott R. J., Goodburn S. F. (1995). Potter's syndrome in the second trimester: prenatal screening and pathological findings in 60 cases of oligohydramnios sequence. Prenatal Diag., 15, 519-525. | 7. Dayal J., Maheshwari. E., Ghai P. S., Bhatotia S. (2003). Antenatal ultrasound diagnosis of Potter's syndrome. Indian J Radiol Imaging, 18, 81-83. | 8. Khatami F. (2004). Potter's syndrome: A study of 15 patients. Arch Iranian Med, 7(3), 186-189. | 9. Schuardt A., D'Agati A. V., Pachnis V., Costantini F. (1996). Renal agenesis and hypoplasia in ret-K-mutant mice result from defects in ureteric bud development. . Development. , 122, 1919. | 10. Moore K. L. ,Persaud T., Torchia M.G. (2007). The Developing Human: Clinically Oriented Embryology with Student Consult Online Access(9th ed.): Elsevier. |