Research Paper Medical Science

Squamous Cell Carcinoma Arising in Mature Cystic Teratoma – A Rare Case Report

DR IVY SHARMA ASSISTANT PROFESSOR OF PATHOLOGY DEPARTMENT, GAUHATI MEDICAL COLLEGE AND HOSPITAL, GUWAHATI/ SRIMANTA SANKARADEVA UNIVERSITY OF HEALTH SCIENCES,GUWAHATI, ASSAM.

DR CHANDAN JYOTI SAIKIA DEMONSTRATOR OF PATHOLOGY DEPARTMENT, GAUHATI MEDICAL COLLEGE AND HOSPITAL, GUWAHATI/ SRIMANTA SANKARADEVA UNIVERSITY OF HEALTH SCIENCES,GUWAHATI, ASSAM.

ABSTRACT

Mature cystic teratomas account for 30–45 % of all ovarian tumours. Malignant transformation of these tumours is rare with squamous cell carcinoma (Scc) being the commonest histological type. Malignant transformation in a mature cystic teratoma of the ovary is rare. The most common malignancy is squamous cell carcinoma, which consists of about 75% of malignant transformations. In the present report, we describe a case of squamous cell carcinoma arising in a mature cystic teratoma in a 29-year-old female .

KEYWORDS Squamous cell carcinoma, dermoid cyst, mature cystic teratoma, of ovary, malignant transformation ,germ celltumour.

INTRODUCTION

Mature cystic teratoma (MCT) is the most common germ-cell tumor of the ovary. It consists of well-differentiated derivatives of the three germ-cell layers. Malignant transformation is a rare complication of this pathology; it accounts for 1-2% of MCTs and the prognosis of this disease is generally poor with squamous cell carcinoma being the most common type. Mature cystic teratomas are common benign tumors of the ovary. They are bilateral in about 10 % of cases. Malignant transformation is most commonly seen in post-menopausal age group, but has been also reported in patients in and around 30 years or even younger as in our case. These carcinomas are treated with surgical excision and adjuvant chemotherapy. In this study, we present a case of a 29 year old female with squamous cell carcinoma arising in mature cystic teratoma. She was evaluated clinically, biochemically and with imaging studies. Ultrasonography report was suggestive of right ovarian dermoid cyst . Right sided opherectomy was done and specimen was sent for histopathological examination..

CASE REPORT:

Our patient was a 29 years old female who had first presented with pain abdomen. and enlargement of abdomen for 3 months. She gave no history of weight loss, loss of appetite and no bowel/bladder-related symptoms.

Clinical examinations showed a lump palpable just below the umbilicus. The mass was cystic and non-tender with well-defined margins. Ultrasonography showed a large hyperechoic solid lesion measuring 12.7 x10.4 cm showing dermoid mesh and posterior small attenution at places with no internal vascularity in abdominopelvic area possibly arising from right ovary. Minimal free fluid noted in POD (pouch of douglas). Impression was given as features suggestive of right ovarian dermoid cyst .

Gross examination: We received a cut open cystic mass containing hair and sebaceous material measuring 11.6x5.4x4 cm. A solid area was noted measuring 2x1.5 cm. Cyst wall showed variable thickness.

Microscopic examination : Multiple sections showed features of mature teratoma with focal areas showing features of well differentiated squamous cell carcinoma.



GROSS PICTURE OF MATURE CYSTIC TERATOMA WITH COMPONENTS OF SQUAMOUS CELL CARCINOMA

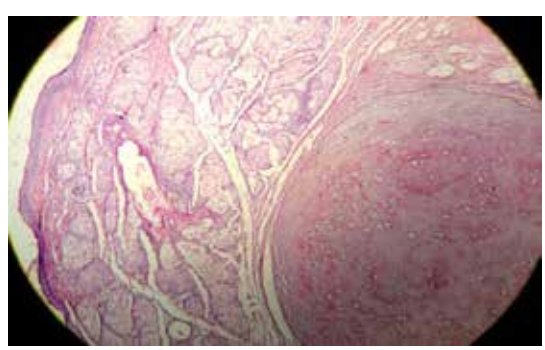

MICROSCOPIC PICTURE OF MATURE CYSTIC TERATOMA SHOWING SQUAMOUS EPITHELIUM, ABUNDANT SEBACEOUS GLANDS AND CARTILAGE

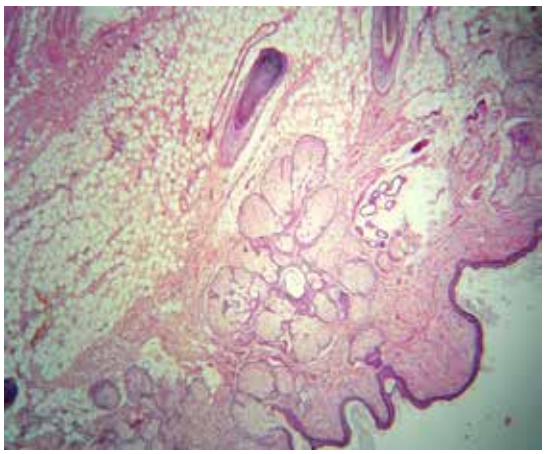

ANOTHER MICROSCOPIC PICTURE OF MATURE CYSTIC TERATOMA SHOWING ADIPOSE TISSUE ON LEFT SIDE

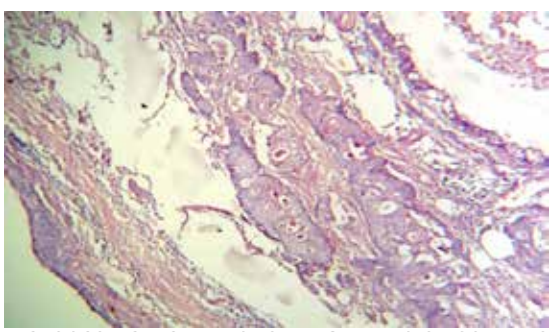

MCROSCOPIC PICTURE SHOWING AREAS OF SQUAMOUS CELL CARCINOMA IN MATURE CYSTIC TERATOMA (LOW POWER VIEW)

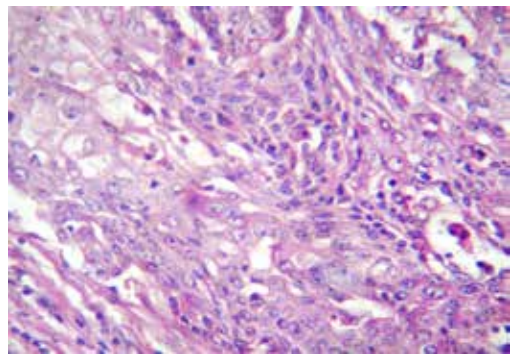

MICROSCOPIC PICTURE SHOWING AREAS OF SQUAMOUS CELL CARCINOMA IN MATURE CYSTIC TERATOMA (HIGH POWER VIEW)

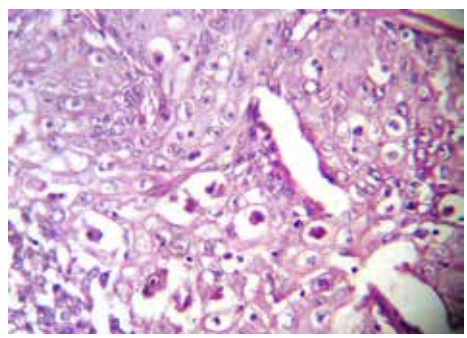

MICROSCOPIC PICTURE OF ANOTHER AREA SHOWING SQUAMOUS CELL CARCINOMA (HIGH POWER VIEW)

Discussion:

MCT(Mature cystic teratoma) accounts for 10–20 % of all ovarian tumors in women within the reproductive age(1), while malignant transformation of mature teratoma is more common after the age of 50yrs .SCC arising from an MCT is a rare pathologic event and in most instances not diagnosed preoperatively .SCC arising in an MCT has historically been observed in relatively older patients, particularly those after menopause; although, it has been sometimes reported in young patients who are around 30 years of age (2) or even younger (3,9) as in our case. A couple of studies demonstrated the role of patient's age in differential diagnosis as it is prudent to maintain a higher suspicion of malignancy in MCTs occurring in patients over the age of 45 (4). In most of the series, the median age at diagnosis of malignant transformation of MCT was 54-61.5 years [5] and the most common symptoms were abdominal pain, palpable mass and abdominal distension; but some people may be asymptomatic at diagnosis(6). MCT with diameter > 10 cm is associated with increased risk of malignancy in some studies (7) The prognosis for these tumors has been often reported to be very poor with a five-year survival of only 15 – 30%(8)

Conclusion :

Squamous-cell carcinoma arising in a mature cystic teratoma is an unusual disorder. This rare type of tumor should be kept in mind when faced with a dermoid cyst, especially in older patients or in larger than usual cyst. The prognosis for these tumours have been very poor with a five year survival of only 15-30%.

REFERENCES

1. Kurman R J. Blaustein's Pathology of the Female Genital Tract. 5th ed. New York: Springer Verlag; 2002. | | 2.Kurtz JE, Jaeck D, Maloisel F, Jung GM, Chenard MP, Dufour P. Combined modality treatment for malignant transformation of a benign ovarian teratoma. Gynecol Oncol. 1999; 73: 319 – 321. | | 3 . Rim SY, Kim SM, Choi HS. Malignant transformation of ovarian mature cystic teratoma. Int J Gynecol Cancer. 2006; 16: 140 – 144. | 4.Kikkawa F, Ishikawa H, Tamakoshi K, Nawa A, Suganuma N, Tomoda Y. Squamous cell carcinoma arising from mature cystic teratoma of the ovary: a clinicopathologic analysis. Obstet Gynecol. 1997; 89: 1017 – 1022. | 5. Dos Santos L, Mok E, Iasonos A: Squamous cell carcinoma arising in mature cystic teratoma of the ovary: a case series and review of the literature. Gynecol Oncol 2007, 105:321-4 | (6). Tseng CJ, Chou HH, Huang KG, Chang TC, Liang CC, Lai CH and co: Squamous cell carcinoma arising in mature cystic teratoma of the ovary. Gynecol Oncol 1996, 63:364-70. | 7. Yamanaka Y, Tateiwa Y, Miyamoto H, Umemoto Y, Takeuchi Y, Katayama K and co: Preoperative diagnosis of malignant transformation in mature cystic teratoma of the ovary. Eur J Gynaecol Oncol 2005, 26:391-21 | 8. Kurman R J. Blaustein's Pathology of the Female Genital Tract. 5th ed. New York: Springer Verlag; 2002. | 9. Park JY, Kim DY, Kim JH, Kim YM, Kim YT, Nam JH. Malignant transformation of mature cystic teratoma of the ovary: experience at a single institution. Eur J Obstet Gynecol Reprod Biol. 2008 Dec; 141(2):173-8. |