Research Paper Medical Science

Subclavian Steal Syndrome with Bovine Arch Configuration of Aorta - A Case Report

Dr.Roopa Assistant professor, Department of Radiodiagnosis, DM WIMS, Naseera nagar, Meppadi (PO), Wayanad, Kerala-673577, India

Dr. MD. Nazrul Haque Assistant Professor, Department of Radiodiagnosis, DM WIMS, Naseera nagar, Meppadi (PO), Wayanad, Kerala, India.-673577

ABSTRACT

Subclavian steal syndrome refers to the phenomenon of reversal of blood flow in vertebral arteries usually caused by stenosis of the proximal subclavian artery. We report a case of 61yr old female presented with history of giddiness more after excessive use of left upper limb. Subclavian steal was detected on color Doppler study and CT angiography confirmed severe stenosis of left proximal subclavian artery. Bovine arch configuration of aorta noted on CT angiography. Percutaneous Transluminal Angioplasty was done. Clinical symptoms of patient improved after the procedure.

KEYWORDS vertebral artery, subclavian artery, bovine arch, color Doppler

Introduction

The phenomenon of subclavian steal is caused by occlusion or stenosis of the proximal subclavian artery before the origin of vertebral artery with subsequent retrograde filling of the SA via the ipsilateral vertebral artery [1, 2]. The designation "subclavian steal" was coined by Miller Fischer in 1961 to characterize 2 cases reported by Reivich et al [3].Because of the reversal of flow in the vertebral artery patient can present with neurological symptoms. Fisher dubbed the combination of retrograde vertebral flow and neurologic symptoms into subclavian steal syndrome (SSS), suggesting that blood is stolen by the ipsilateral vertebral artery from the contralateral vertebral artery. Later it was suggested that "steal" may cause brainstem ischemia and stroke secondary to arm exercise.

Case report

A 61 year old female presented to the physician with history of giddiness, which is more after left upper limb exertion. On examination, left upper limb pulses were weak. Jugular venous pressure was normal. Pulse rate was 62 per minute and blood pressure in right upper limb was 140/64mmHg and in left upper limb was 94/70mmHg. No cardiac or carotid murmur noted. Respiratory system and abdominal examination were normal. She was a known case of diabetes mellitus and dyslipidemia.

Because of discrepancy in the blood pressure in upper limbs, patient was admitted in the medicine department and detailed evaluation was done. Chest X Ray was normal.ECG was done in which ST-T wave changes were noted. Echocardiogram showed LV diastolic dysfunction, trivial mitral regurgitation and trivial aortic and tricuspid regurgitation. Aortic and tricuspid valves were mildly thickened.

Carotid Doppler study was done to evaluate carotid vessels and vertebral vessels. Carotid Doppler was done on high-resolution B-mode duplex ultrasound (GE Voluson S6) with color and pulsed wave Doppler using L7–4MHz linear array transducer.

Carotid duplex ultrasound examination revealed normal velocities and normal spectral waveform in right CCA, ICA, ECA and vertebral artery. Doppler study of left CCA, ICA and ECA were also normal. Direction of flow in left vertebral artery is opposite to that seen in left common carotid artery. So we suspected subclavian steal syndrome. CT Angiography of head and neck was performed which revealed severe stenosis of left proximal subclavian artery and bovine arch was noted i.e. left common carotid artery originating from right brachiocephaic trunk. 3D reconstructed image was showing severe stenosis of left proximal Subclavian artery and bovine arch configuration of aorta. Subsequently patient underwent Percutaneous transluminal angioplasty (PTA). After PTA, patient symptoms were relieved.

Figure 1(a) Color Doppler ultrasound showing the normal antegrade flow, velocity and spectral waveform in right common carotid artery.

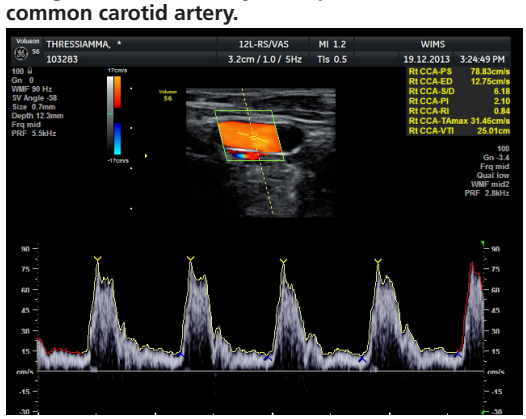

Figure 1(b) Color Doppler ultrasound showing the normal antegrade flow, velocity and spectral waveform in right internal carotid artery.

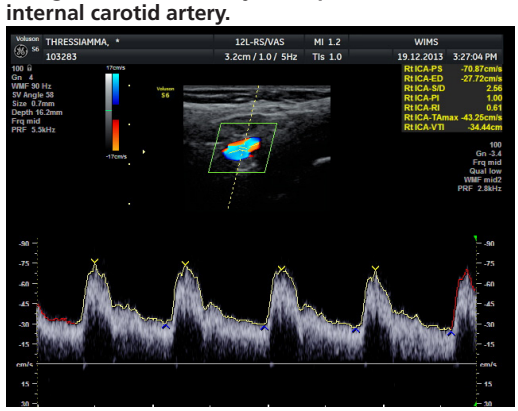

Figure 1(c) Color Doppler ultrasound showing the normal antegrade flow, velocity and spectral waveform in the right External carotid artery.

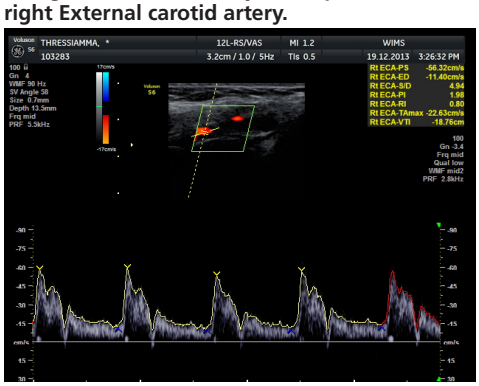

Figure 1(d) Color Doppler ultrasound showing the normal antegrade flow, velocity and spectral waveform in right vertebral artery.

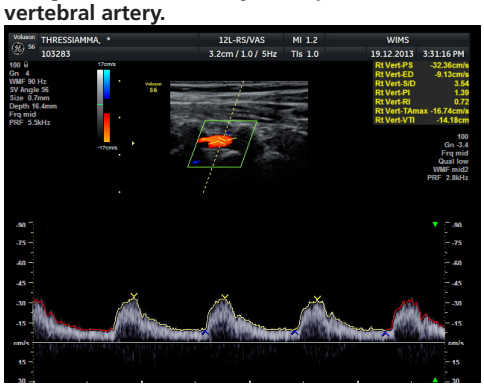

Figure 1(e) Color Doppler ultrasound showing the flow direction in left vertebral artery which is opposite to the flow seen in left common carotid artery.

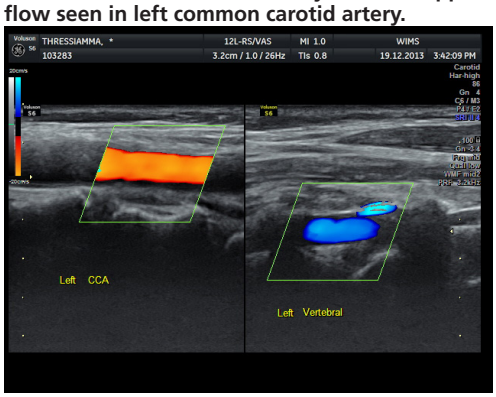

Figure 2(a) Color Doppler ultrasound showing the normal antegrade flow, velocity and spectral waveform in the left common carotid artery.

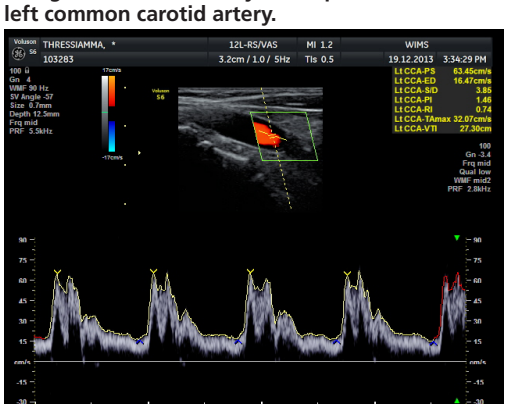

Figure 2(b) Color Doppler ultrasound showing the normal antegrade flow, velocity and spectral waveform in left internal carotid artery

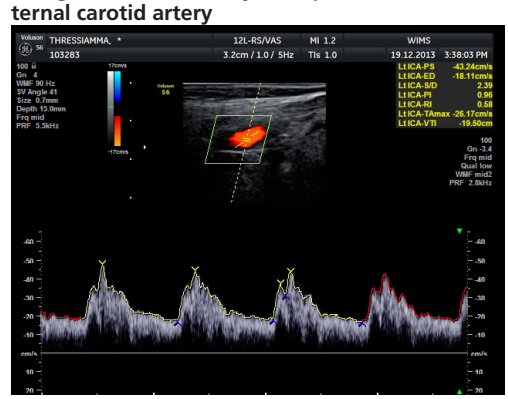

Figure 2(c) Color Doppler ultrasound showing the normal antegrade flow, velocity and spectral waveform in the left external carotid artery.

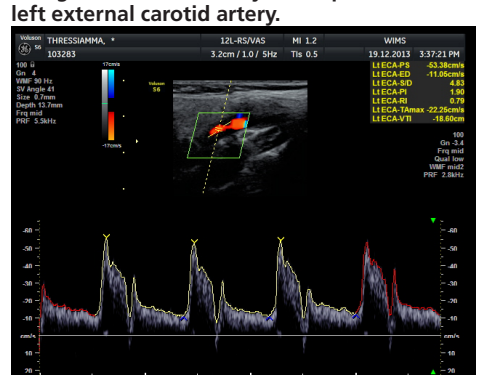

Figure 2(d) Color Doppler ultrasound showing reversal of flow in left vertebral artery.

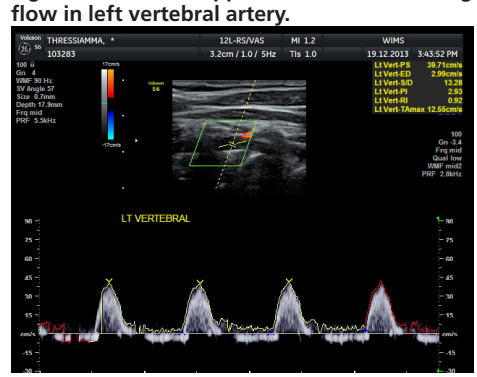

Figure 3(a) Axial CT Angiography showing severe stenosis of left proximal subclavian artery

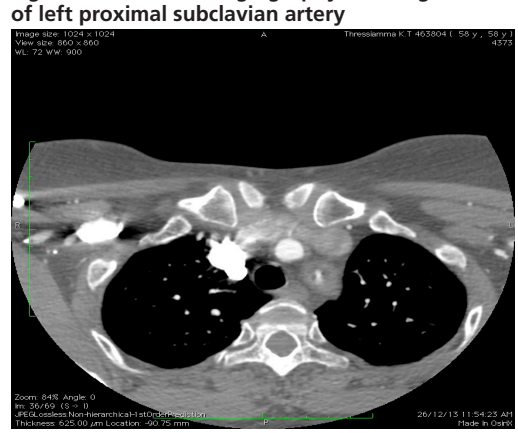

Figure 3(b) Coronal reconstructed CT Angiography showing the Bovine arch i.e. left common carotid artery is originating from brachiocephalic trunk



Figure 4: 3D reconstructed image showing severe stenosis of left proximal subclavian artery and bovine arch configuration of aorta. Flow is seen in distal Subclavian artery as it is filled by retrograde flow through the ipsilateral vertebral artery.

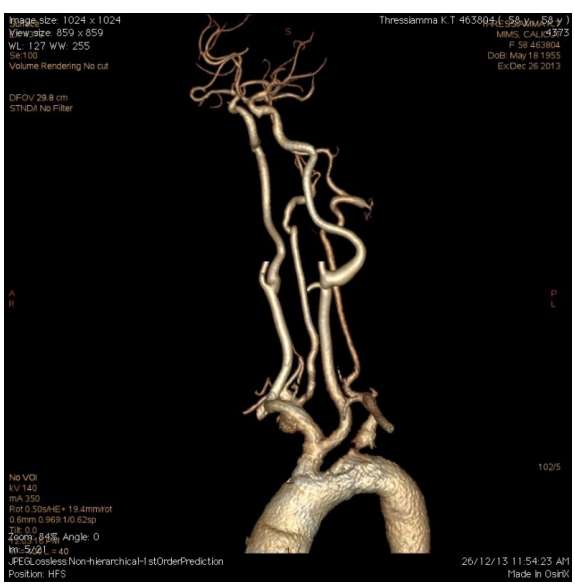

Discussion

Subclavian steal syndrome is reversal of flow in the ipsilateral vertebral artery due to stenosis of proximal subclavian artery .The arm may be supplied by retrograde flow in the vertebral artery at the expense of vertebrobasilar circulation. This reversal of flow in vertebral artery leads to neurological symptoms like giddiness. The neurological symptoms will be aggravating on excessive use of ipsilateral upper limb. Color Doppler ultrasound is the preferred examination for subclavian steal syndrome which can detect reversal of flow in the vertebral arteries. But the evaluation of proximal subclavian artery is difficult due to overlying sternum, clavicle and ribs. The normal diameter of vertebral artery is 4mm [4, 5]. Normally the flow in vertebral arteries is antegrade and cephalad i.e. towards the brain, similar to the common carotid artery. Normal peak systolic velocity in vertebral arteries is 20 to 60cm/sec [6]. There are four types of abnormal wave patterns in vertebral artery on color Doppler study in subclavian stenosis [7]. First one is complete subclavian steal in which reversal of flow noted in vertebral artery ipsilateral to the stenotic or occluded subclavian artery. Second one is incomplete or partial subclavian steal in which transient reversal noted in vertebral artery during systole which may be converted into a complete steal using 5 minutes of exercise or inflation of sphygmomanometer cuff to induce rebound hyperaemia. This type suggests stenosis of subclavian artery, not occlusion. Third variety is presteal phenomenon which shows Bunny waveform in which systolic deceleration is less than the diastolic flow .This may be converted into partial steal after exercise or cuff manoeuvre .It is seen with proximal subclavian stenosis. Last variety is tardus-parvus or dampened waveform seen in vertebral artery stenosis. Normally 3 vessels take origin from aortic arch. The first branch is the brachiocephalic trunk, which branches into the right subclavian artery and the right common carotid artery. The second branch in the most common pattern is the left common carotid artery and the last branch is the left subclavian artery. There are few variations in the branching pattern. In the most common bovine arch type, left common carotid artery shares a common origin with brachiocephalic trunk. Other less common variant which is also known as bovine arch ,in which left common carotid artery originates from brachiocephalic trunk[8]. In our study left common carotid artery is arising from brachiocephalic trunk. Treatment for Subclavian stenosis is Percutaneous transluminal angioplasty [9].

Conclusion

Subclavian steal syndrome is the common vascular disease which can present with neurological symptoms which depends upon the collateral circulation of the vertebrobasilar system. CT Angiography can better evaluate the subclavian artery which is difficult to evaluate on color Doppler. There are 20 different types of aortic arch configurations, of which Bovine arch configuration of the aorta is most common. We reported this case because of the rarity of combination of subclavian stenosis and bovine arch configuration of aorta.

REFERENCES

1. Chan-Tack KM. Subclavian steal syndrome: a rare but important cause of syncope. South Med J 2001;94:445-447. | 2. Hennerici M, Klemm C, Rautenberg W. The subclavian steal phenomenon: a common vascular disorder with rare neurologic deficits. Neurology 1988;38:669-673. | 3. Reivich M, Holling HE, Roberts B, Toole JF. Reversal of blood flow through the vertebral artery and its effect on cerebral circulation. N Engl J Med 1961;265:878-885. | 4. Buckenham TM, Wright IA, PhD: Ultrsound of the extracranial arteries. The British Journal of Radiology. (2004) ;77:15-20. | 5. Barbara A Carroll. Extracranial cerebral vessels: Diagnostic Ultrasound,3rd edition.2009 :Volume I:Page no.980 to 984. | 6. Zwiebel WJ. Ultrasound vertebral examination. In: Zwiebel WJ, ed.Introduction to vascular ultrasonography, 4th ed. Philadelphia, PA: Saunders, 2000:167 -176. | 7. Kliewer MA,Hertzberg BS,Kim DH et al ,Vertebral artery Doppler waveform changes indicating subclavian steal physiology.AJR 2000;174:815-819. | 8. K.F. Layton Bovine Aortic Arch Variant in Humans: Clarification of a Common Misnomer: Am J Neuroradiol 27:1541– 42 :Aug 2006. | 9. Felipe Fregni, Luiz Eduardo, Branco et al:Treatment of subclavian steal syndrome with Percutaneous Transluminal Angioplasty and Stenting, Arq Neuropsiquiatr 2003;61(1):95-99. |