Research Paper Pathology

Subcutaneous Entomophthoromycosis mimicking soft tissue tumour: Report of two cases in Maharashtra, India

Dr. Jyoti K Kudrimoti	MD Department of Pathology, First floor, B J Medical College, Sassoon Hospital Compound, Station Road, Pune, Maharashtra, India,411001
Dr. Savita S. Patil	MD Department of Pathology, First floor, B J Medical College, Sassoon Hospital Compound, Station Road, Pune, Maharashtra, India,411001
Dr.Somnath S Khedkar	MD Department of Pathology, First floor, B J Medical College, Sassoon Hospital Compound, Station Road, Pune, Maharashtra, India,411001
Dr. Medha M Khandekar	MD Department of Pathology, First floor, B J Medical College, Sassoon Hospital Compound, Station Road, Pune, Maharashtra, India,411001
Dr. Shaila C Puranik	MD Department of Pathology, First floor, B J Medical College, Sassoon Hospital Compound, Station Road, Pune, Maharashtra, India,411001

ABSTRACT

Entomophthoromycosis (subcutaneous zygomycosis) is a sporadic subcutaneous infection that is largely restricted to tropical areas of Africa, Asia, and South America. It presents in two clinically distinct forms. Subcutaneous zygomycosis, caused by Basidiobolus ranarum and rhinofacial zygomycosis caused by Conidiobolus coronatus. Neither of these two forms occur preferentially in patients with underlying disease or defective immunity1. Entomophthoromycosis is characterized by the formation of firm and nontender swellings, generally on the extremities, trunk, & rarely other parts of the body2. Subcutaneous zygomycosis can also mimic soft tissue tumors3. We present 2 cases with large, rapid-growing zygomycotic subcutaneous lesions, initially misdiagnosed as a soft tissue tumor, emphasizing importance of rapid & thorough diagnosis with a high index of suspicion, especially in endemic areas. Our experience with these cases highlights importance of awareness & early recognition of this condition to prevent disfigurement produced by advanced disease, misdiagnosis, & unnecessary delay in treatment. Subcutaneous zygomycosis should be considered in differential diagnosis of subcutaneous swellings, especially in tropical countries. Treatment should be given on histopathological diagnosis as fungus is difficult to grow in culture with immunology & serology having limited basis in use for diagnostic purposes.

KEYWORDS Entomophthoromycosis (subcutaneous zygomycosis) , soft tissue tumors

1. Introduction:

Entomophthoromycosis (subcutaneous zygomycosis) is a sporadic subcutaneous infection that is largely restricted to tropical areas of Africa, Asia, and South America. It presents in two clinically distinct forms. Subcutaneous zygomycosis, caused by Basidiobolus ranarum and rhinofacial zygomycosis caused by Conidiobolus coronatus. Neither of these two forms occur preferentially in patients with underlying disease or defective immunity[1]. Entomophthoromycosis is characterized by the formation of firm and nontender swellings, generally on the extremities, trunk, and rarely other parts of the body[2]. Subcutaneous zygomycosis can also mimic soft tissue tumors[3]. We present two cases with large, rapid-growing zygomycotic subcutaneous lesions, initially misdiagnosed as a soft tissue tumor, emphasizing the importance of rapid and thorough diagnosis with a high index of suspicion, especially in endemic areas.

2. Case Presentation:

Case 1

A fortynine year old male was admitted with the complains of a gradually increasing painless multiple swellings over bilateral gluteal regions & both thighs of 6 months duration. One of the swelling on anterior aspect of right thigh was ulcerated.

Local examination showed multiple large illdefined nontender indurated subcutaneous swellings approximately 10 to 15 cms in size, on anterior as well as posterior aspect of both thighs and also on bilateral gluteal regions. The swellings were firm in consistency with smooth and rounded edges. The overlying skin was lobulated and hyperpigmented and showed a large ulcer on anterior aspect of right thigh measuring 10 X 12 cms. There was no regional lymphadenopathy. Clinical diagnosis of soft tissue tumor was considered.

General and systemic examination was normal. Routine laboratory investigations revealed an elevated TLC (20,400/cmm). HIV status was negative. X-ray of the thigh revealed a soft tissue swelling without any bone involvement.

Case 2:

A 35 year male was admitted with the complains of multiple gradually increasing painless swellings over the chest, neck & abdomen of 7 to 8 months duration.

Local examination showed multiple nontender indurated subcutaneous swellings from 8 to 10cm in size on sternum, lateral chest wall, neck & abdomen. The swellings were firm in consistency with smooth and rounded edges.Clinical diagnosis was soft tissue tumor.

Routine laboratory investigations revealed an elevated TLC (27,400/cmm). HIV status was negative. X-ray & USG revealed multiple soft tissue swellings in subcutaneous plane without any bone involvement. There was mediastinal swelling suggestive of lymphadenopathy on HRCT. Outside report of biopsy of mediastinal swelling was tuberculous granulomatous lesion. Patient was treated outside with AKT for 6 months but swell-

ings persisted & increased in size.

Fine needle aspiration cytology (FNAC) findings:
FNAC in 1st case was suggestive of a granulomatous lesion. In 2nd case,FNAC showed multiple foreign body type of giant cells, few containing hyphal fragments admixed with histiocytes, eosinophils & lymphocytes. Caseation was absent. AFB stain was negative. Thus FNAC was suggestive of fungal granulomatous lesion.

Gross & microscopic findings:
Biopsy taken from one of the nodules in1st case & chest swelling in 2nd case were sent for histopathological examination.

We received 3 tissue fragments measuring 0.5x 1cm in 1st case & multiple tissue fragments together measuring 3cc in 2nd case with grey-white cut surface. In both cases,H & E stained sections revealed normal skin with subcutaneous tissue showing inflammatory granulomatous reaction with few multinucleated giant cells. The central portion showed fragments of broad, thinwalled, and infrequently septate fungal hyphae surrounded by a peculiar eosinophilic mass and the Splendore-Hoeppli phenomenon (Figures 1 and 2). Periodic acid Schiff (Figure 3) and Gomori methenamine silver (Figure 4) stains were positive. In 2nd case central necrosis was noted but AFB stain was negative.

In both the cases,culture on Sabouraud's dextrose agar after three days of incubation was negative & in view of typical histopathological findings, diagnosis of entomophthoromycosis was made.

The 1st patient was given antifungal treatment for six months. The recovery was uneventful. After six months of follow up there was no recurrence. Unfortunately, in 2nd case, antifungal treatment was started but patient succumbed to death on day of admission.

Discussion
In 1956 in Indonesia, Lei-Kian Joe described the first case of entomophthoromycosis in humans; the infectious agent was Basidiobolus ranarum. In 1965 Bras reported a case in a Jamaican native caused by Conidiobolus coronatus. Worldwide, there have been about 250 reported cases caused by Basidiobolus haptosporus. All of them affecting trunk and extremities, and usually seen in children. Approximately 160 cases caused by Conidiobolus coronatus have been reported[4]. Entomophthoromycosis (subcutaneous zygomycosis) caused by Basidiobolus ranarum manifests clinically as a firm, painless, disciform nodule on the trunk or extremities, which if untreated may enlarge and spread locally, but systemic dissemination is extremely uncommon. Rhinofacial zygomycosis caused by Conidiobolus coronatus is a locally progressive infection of the nasal cavity, paranasal sinuses, and soft tissues of the face. The microscopic features of both forms of entomophthoromycosis are similar and give rise to an eosinophilic granuloma situated in the subcutaneous tissues[5]. In lab diagnosis, zygomycotic fungi that are clearly visible in direct microscopic or histopathological mounts are difficult to grow in culture from clinical specimens as they have coenocytic hyphae which will often be damaged and become nonviable during biopsy procedure or by chopping up or grinding processes in the laboratory.[6,7,8] Histopathology is most rapid diagnostic method with characteristic splendore hoeppli phenomenon.[6,7,8] In both of our cases, fungus could not be grown in culture & diagnosis was made on histopathology.

The disease usually occurs in children, less often in adolescents, and rarely in adults. Males are much more frequently affected than females[9]. Both of our cases were adult males.

Chiewchanvit et al., studied eight cases of entomophthoromycosis out of which five patients were diagnosed as subcutaneous zygomycosis (females aged 7–77 years), two rhinofacial zygomycosis (26 and 39 years, males) and one case was of gastrointestinal entomophthoromycosis (34 year, male)[10]. Our cases were having subcutaneous zygomycosis.

The disease is primarily one of the subcutaneous tissue, but on occasion deeper structures have been invaded. Two deaths have been noted; in one patient the large intestine and pelvis were involved, and in the other the neck.[11,12,13] Both of our cases had multiple subcutaneous swellings but second case patient had mediastinal swelling indicating invasion in deeper structures & died.

In a study of ten cases of entomophthoromycosis by Krishnan et al., eight were caused by Basidiobolus haptosporus, predominantly in children below ten years of age, and thigh was the most commonly involved site[14]. Our first case had thigh & gluteal region involved.

Entomophthoromycosis is a potentially curable disease which can masquerade as a neoplasm. Cases have been reported in The literature, where subcutaneous zygomycosis presented as a mimicker of soft tissue tumor, synovial sarcoma, and Burkitt's lymphoma [16-18]. In our patients also, such a large size of the swellings, its duration and clinical presentation misguided the clinician to diagnose these as a soft tissue tumor. Another disease common in Uganda that simulates entomophthoromycosis basidiobole is Buruli ulcer. This is caused by Mycobacterium ulcerans, which also appears to be a lipophilic organism. The disease it produces also spreads slowly and involves extensive areas of subcutaneous tissue.26 In biopsy specimens the overlying skin is seen to be atrophic but rarely ulcerated. The subcutaneous mass itself is firm and thickened with fibrous tissue containing occasional yellowish foci of necrosis.26 Our first case showed cutaneous ulceration & second case showed presence of central necrosis in granulomas.

Histologically, basidiobolomycosis is associated with eosinophilic infiltration. This has been postulated to be due to a mixture of Th1 (granuloma) and Th2 type of immune response. This causes the release of cytokines like IL-4 and IL-10 which in turn are helpful in recruiting eosinophils to the affected site 5. Both of our cases showed moderate eosinophilic infiltration in the lesions. The other histological features are presence of broad thin walled infrequently septate hyphal fragments enveloped by eosinophilic "Splendore-Hoeppli" material1. This was prominent in both the cases.

In the past, clinical isolates of Basidiobolus were classified as B. ranarum, B. meristosporus, and B. haptosporus. But recent taxonomic studies based on antigenic analysis, isoenzyme banding, and restriction enzyme analysis of rDNA indicate that all human pathogens belong to B. ranarum 15. Most patients with entomophthoromycosis respond very well to oral potassium iodide therapy as well to azoles, particularly itraconazole 15. This highlights importance of early treatment on histopathological diagnosis.

To summarise, subcutaneous zygomycosis presents as a painless subcutaneous swellings usually in young & middle age. It is usually seen in the natives of Asia, Africa, and South America. This is commonly misdiagnosed as soft tissue tumour. Demonstration of the aseptate fungal hyphae on histopathology and confirmation by culture clinches the diagnosis. Fungus is difficult to grow in culture. Treatment with potassium iodide and azoles is the gold standard.

Our experience with these cases highlights the importance of awareness and early recognition of this condition to prevent disfigurement produced by advanced disease, misdiagnosis, and unnecessary delay in treatment.

To conclude, subcutaneous zygomycosis should be considered in diffential diagnosis of subcutaneous swellings, especially in tropical countries. Treatment should be given on histopathological diagnosis as fungus is difficult to grow in culture with immunology & serology having limited basis in use for diagnostic purposes.

Legends:
Case 1:
Figure1:
Clinical phptographs of the multiple large illdefined indurated subcutaneous swellings approximately 10 to 15 cms in size, on bilateral gluteal regions and also on thighs.



Figure2:

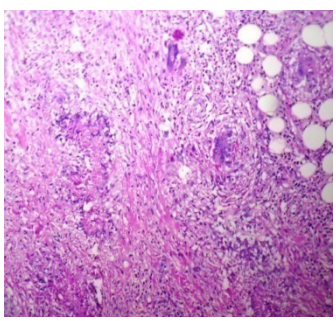

Low power view of the lesion showing granulomatous reaction, mixed inflammatory infiltration, and fibrosis (H & E, 100x).
Figure3:

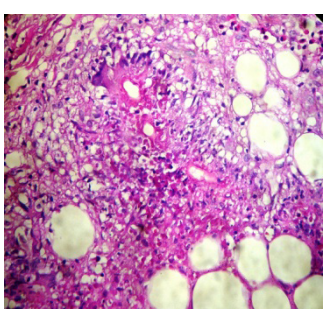

Splendore-Hoeppli bodies surrounded by eosinophils, polymorphs and few histiocytes. (H&E, 400x).

Figure4:

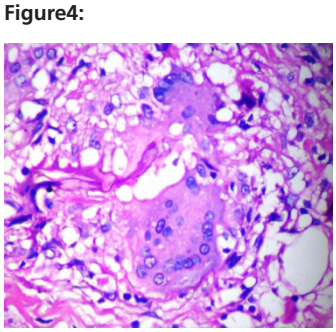

Photomicrograph showing aseptate fungal hyphal filament on Periodic acid Schiff (PAS, 400x),

Figure 5:

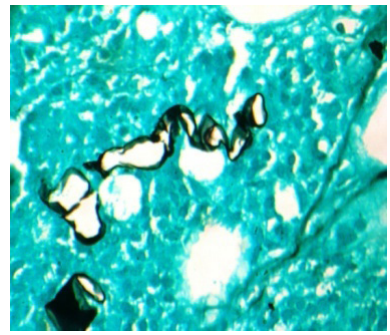

Photomicrograph showing aseptate hyphal filaments on Gomori silver methenamine silver (GMS) stain. s (GMS, 400x).

Case2:

Figure 6: Clinical photograph of the large indurated subcutaneous swelling approximately 10 x 8 cms in size on chest.



Figure 7: FNAC smear showing foreign body type of giant cell with hyphal fragment in cytoplasm. (Romanavasky, 1000x).

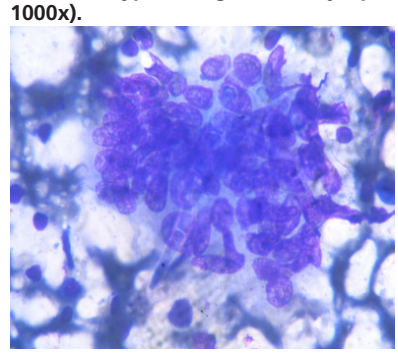

Figure 8: Low power view of the lesion showing granulomatous reaction, mixed inflammatory infiltration, and fibrosis & central necrosis (H & E, 100x).

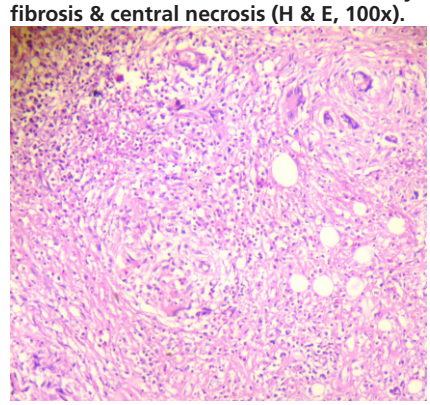

Figure 9: 5-15 µm broad,thin walled, infrequently septate hyphae(represented by empty tubular spaces) surrounded by distinctive & characteristic eosinophilic sheath - Splendore Hoeppli phenomenon(H&E, 400x).

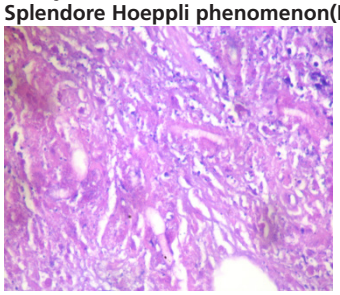

Figure 10: Photomicrograph showing infrequently septate fungal hyphal filament on Periodic acid Schiff (PAS, 400x),

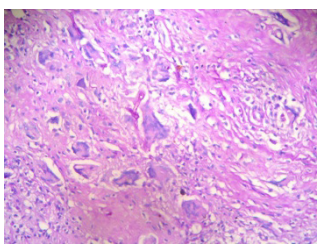

Figure 11: Photomicrograph showing infrequently septate hyphal filaments on Gomori silver methenamine silver (GMS) stain. (GMS, 400x).

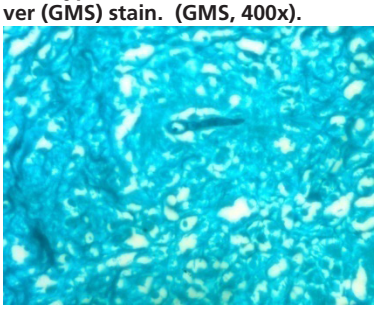

REFERENCES

1. F. W. Chandler and J. C. Watts, "Fungal Diseases," in Anderson's Pathology, I. Damjanov and J. Linder, Eds., Mosby, St. Louis, Mo, USA, 10th edition, 1996. | 2. M. R. Naniwadekar, S. V. Jagtap, B. P. Nikam, and K. D. Sanghavi, "Subcutaneous phycomycosis in a child," Online Journal of Health and Allied Sciences, vol. 8, no. 3, p. 14, 2009. | 3. S. P. Thotan, V. Kumar, A. Gupta, A. Mallya, and S. Rao, "Subcutaneous phycomycosis-fungal infection mimicking a soft tissue tumor: a case report and review of literature," Journal of Tropical Pediatrics, vol. 56, no. 1, pp. 65–66, 2010. | 4. E. Drouhet and P. Ravisse, "Entomophthoromycosis," in Current Topics in Medical Mycology, M. Borgers , R. Hay, and M. G. Rinaldi, Eds., vol. 5, Prous Science, Barcelona, Spain, 1994. | 5. S. Rane, A. Jayaraman, S. Puranik, S. Deshmukh, and V. Bapat, "Entomopthoromycosis-Report of four cases," Indian Journal of Dermatology, Venereology and Leprology, vol. 68, no. 5, pp. 296–297, 2002. | 6. Rippon, John Willard et al, Medical Mycology. 2nd ed. Philadelphia, 1982, W. B. Saunders Co. | 7. Francis W. Chandler, John C Watts et al, Anderson's Pathology. 9th ed. Saint Louis, 1990, Mosby Co.Repeat1 | 8. David H. Ellis et al, Topley & Wilson's Medical Mycology. 10th ed., London 2005,Hodder Arnold Co. | 9. H. C. Gugnani, "A review of zygomycosis due to Basidiobolus ranarum," European Journal of Epidemiology, vol. 15, no. 10, pp. 923–929, 1999. | 10. S. Chiewchanvit, C. Pruksachatkunakorn, N. Vanittanakom et al., "Entomophthoromycosis in Maharaj Nakorn Chiang Mai Hospital," Journal of the Medical Association of Thailand, vol. 85, no. 10, pp. 1089–1094, 2002. | 11. Clark B M 1968. The epidemiology of phycomycosis. In Wolstenholme G E and R Porter(eds.), Symposium on Systemic Mycosis. Boston, Little, Brown and Company, pp. 179-192. | 12. Edington G. M. 1964. Phycomycosis in Ibadan, West Nigeria. Trans. R. Soc. Trop. Med. Hyg., 58: 242-245 | 13. Fromentin H. and P. Ravisse. 1977. Les entomophthoromycosis tropicales. Acta Trop., 34: 375- 394. | 14. S. G. S. Krishnan, G. Sentamilselvi, A. Kamalam, K. A. Das, and C. Janaki, "Entomophthoromycosis in India - A 4-year study," Mycoses, vol. 41, no. 1-2, pp. 55–58, 1998. | 15. S. Sujatha, C. Sheeladevi, A. B. Khyriem, S. C. Parija, and D. M. Thappa, "Subcutaneous zygomycosis caused by Basidiobolus ranarum—a case report," Indian Journal of Medical Microbiology, vol. 21, no. 3, pp. 205–206, 2003. | 16. Z. U. Khan, M. Khoursheed, R. Makar, et al., "Basidiobolus ranarum as an etiological agent of gastrointestinal zygomycosis," Journal of Clinical Microbiology, vol. 39, no. 6, pp. 2360–2363,, 2001. | 17. Sivaraman, D. M. Thappa, Karthikeyan, and Hemanthkumar, "Subcutaneous phycomycosis mimicking synovial sarcoma," International Journal of Dermatology, vol. 38, no. 12, pp. 920–923, 1999. | 18. A.L. Bittencourt, G. Serra, and M. Sadigursky, "Subcutaneous zygomycosis caused by Basidiobolus haptosporus: presentation of a case mimicking Burkitt's lymphoma," American Journal of Tropical Medicine and Hygiene, vol. 31, no. 2, pp. 370–373, 1982. |