Research Paper Pediatrics

Testicular yolk sac tumor (mixed variety) in an three-month old child: A case report

Dr. Kavita Choudhary	PG resident, dept of pediatrics, GMC, Kota.
Dr.Priya Gupta	PG resident, dept of pediatrics, GMC, Kota.
Dr.R.K.Tanwar	HOD,dept of radiotherapy,GMC,Kota.
Dr.Laxmi Agrawal	Assistant Professor,dept of pathology,GMC,Kota.

ABSTRACT

Germ cell tumors are rare in children. This group of tumors in children is distinct from that in adults in terms of their behavior, histological nature, metastasis and the treatment needed. 85% of the yolk sac tumors in children present as clinical stage I disease as compared to 35% in adults. AFP can be used as a reliable tumor marker as the levels are increased in more than 90% of yolk sac tumors. In children inguinal orchidectomy followed by stringent surveillance for two years is the preferred treatment option. Combination chemotherapy may be reserved for metastatic disease or recurrence. Retroperitoneal Lymph Node Dissection (RPLND) is preferable in adults. In this case report we describe the clinical presentation, imaging findings, diagnosis and up-to-date management of yolk sac tumor in an three-month old child.

KEYWORDS germ cell tumor, yolk sac tumor, Alpha fetoprotein, chemotherapy, RPLND

INTRODUCTION

Yolk sac tumors are those that resembles the yolk sac, allantois, and extraembryonic mesenchyme. They are also known as endodermal sinus tumors. Yolk sac tumors (YSTs) can be seen in males and females, involving the testis, ovary, and other sites, such as the mediastinum. The etiology of yolk sac tumors (YSTs) is essentially unknown. It is speculated that hypermethylation of the *RUNX3* gene promoter and overexpression of GATA-4, a transcription factor that regulates differentiation and function of yolk sac endoderm, may play important roles in the pathogenesis of yolk sac tumors (YSTs)1. Yolk sac tumors (YSTs) of the testis are observed in 2 forms or age groups: pure YST in young children and mixed type in adults. YST can have a multitude of morphologic patterns including: reticular, endodermal sinus-like, microcystic(mc), papillary, solid, glandular, alveolar, polyvesicular vitelline, enteric and hepatoid.Testicular tumors are highly treatable and usually curable. These patterns do not relate to prognosis but can cause difficulty in distinguishing yolk sac tumors (YSTs) from other tumors or other subtypes of germ cell tumors[1]In children testicular tumors account for approximately 1 to 2% of all tumors, with an incidence of 0.05-2 per 100, 000 children. Among testicular tumors germ cell tumors have a bimodal age distribution. One peak occurs in the first two years of life and the second in young adults 15-35 years of age. Germ cell tumors account for 60% testicular tumors in children, but 95% of testicular tumors in adults. Adult germ cell tumors like seminoma and embryonal carcinoma are rare in children. Teratoma which are benign in children are often malignant in adults.

CASE REPORT

A mother brought an three-month old child to the J.K lon OPD with a painless left testicular swelling, which was noticed few weeks ago. This was the first clinic that the child had attended. On clinical examination swelling was non tender, skin overlying the testis was non pigmented , movable and no signs of inflammation. On Ultrasound examination left testis was 37.8*25.7mm in size, showing altered echotexture and increased vascularity. A hypoechoic mass 18.9*14.7mm is seen in left testis. Mediastinum of left testis and left epididymis are seen normal. Evidence of free fluid in left scrotal sacs is present. Right testis is normal in size, shape and echotexture and was 16.7*8.9mm in size. There was no family history of cancer and no significant birth history. Tumour markers estimation was done which showed elevated values of AFP(alpha feto protein) and normal level of b-hcG. Additionally, liver, spleen, gall bladder, pancreas, kidneys, major vessels and urinary bladder were found to be normal. No detectable masses or lymph nodes were seen in the abdomen. Both lung fields and C/P angles were clear on chest X-ray. Patient was referred to pediatric surgeon. Then patient underwent unilateral orchidectomy through inguinal approach. The left testis was removed together with all its coverings with maximum cord length up to the deep inguinal ring.H&E stained section of the tumour showed mixed variety of yolk sac tumour i.e solid microcystic, solid morphologic and heptoid varieties. Spermatic veins were observed to be dilated and tortuous. No fixity to skin was seen. The patient was discharged the next day and stitches removed.The post-operative period was uneventful. Then patient was referred to oncologist for further management. The patient is advised for strict follow up with AFP levels.

TUMOUR MARKERS

TUMOUR MARKER	OBSERVED VALUE	BIOLOGICAL NORMAL RANGE
AFP	5425 Iu/ml	<5.8 Iu/ml
B-hcG	0.5 mIu/ml	<imIu/ml

HISTOPATHOLOGICAL EXAMINATION :

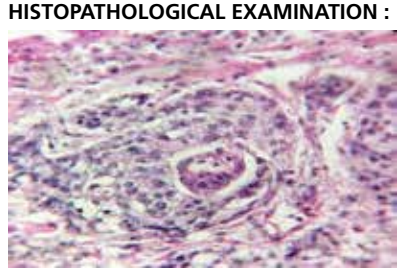

H&E staining showing the Schiller Duval body characteristic of yolk sac tumour.

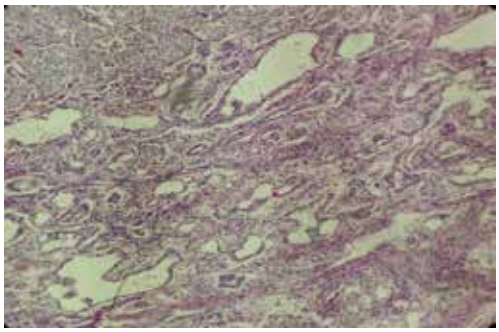

Solid microcystic pattern of YST.

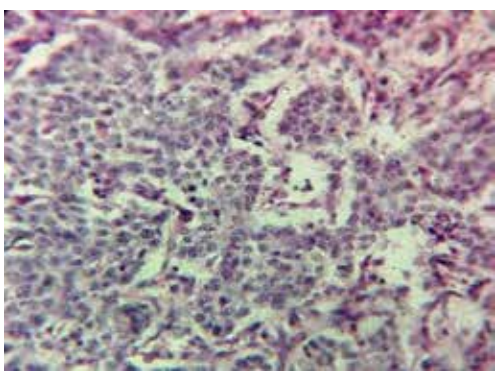

Solid morphologic pattern of YST.

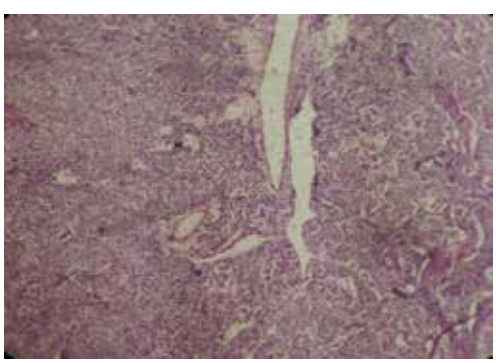

Heptoid morphologic pattern of YST.

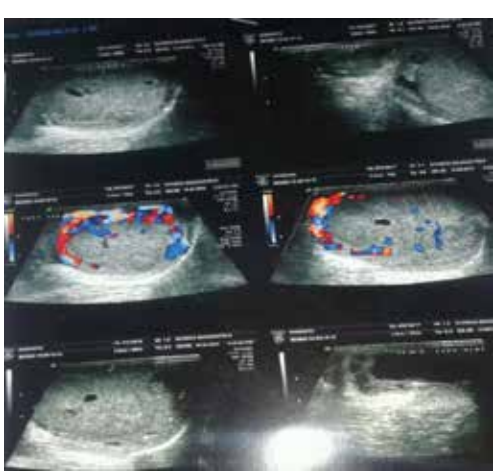

ULTRASOUND EXAMINATION OF TESTIS : Showing enlargement of left testis 37.8mm*25.7mm with altered echotexture and increased vascularity.

DISCUSSION

Germ cell tumors are most frequently found in the gonads. Only 2-5% of them arise in extragonadal regions such as mediastinum, retroperitoneum, pineal gland and sacral areas.

Germ cell tumors are of two types, seminomas and non-seminomas. Seminomas are extremely rare in prepubertal children In adults, yolk sac tumor (YST) presents as a component of mixed nonseminomatous germ cell tumor, with an age averaging 25-30 years.

Yolk sac tumor (YST) components are present in 40-50% of nonseminomatous germ cell tumors in the adult testis[2]. Among non-seminomatous germ cell tumors the most common are teratomas and yolk sac tumors which account for about 62% and 26% of testes tumor in infants and toddlers respectively[3] .

Teratomas are described in some series as constituting 50% of prepubertal testicular Tumors, however these are reported less because of their benign nature . In tumor registries, yolk sac tumors are mentioned more commonly than teratomas

Different risk factors have been described for testicular cancer in the early age group. They include pre-natal exposure to high estrogen levels during intrauterine life, gonadal dysgenesis, exposure of mother to chemical carcinogens and smoking, trauma, testicular atrophy due to torsion, and orchitis .Family history of cancer is an important risk factor in the early age groups.

Three clinical stages for the determination of extension of the tumor have been described [4].Stage I is where the tumor is confined to the testis. Invasion of epididymis tunica albuginea, spermatic cord or scrotum does not change tumor stage but increases the risk of nodal involvement and the risk of recurrence.In stage II the tumor has retroperitoneal lymph node metastasis. Stage III is characterized by supraclavicular lymph nodes, visceral involvement or persistently elevated tumor marker values.

The vast majority, 85%, of yolk sac tumors in children present as clinical stage I disease compared to 35% in adults[5]. AFP can be used as a reliable tumor marker as levels are increased in more than 90% of yolk sac tumors. Therefore patients can be safely managed with observation after orchidectomy. Chemotherapy is reserved for recurrence.

The nature of yolk sac tumor is different in children from that in post-pubertal adults. In young children yolk sac tumors are predominantly pure in histology and are not usually mixed with other histological types as may be encountered in adults. Histopathology and immunohistochemistry revealed that our patient had mixed yolk sac tumor.

Yolk sac tumors in children metastasize through the hematogenous route in more than half of the cases in comparison to adults where it is only 4-6%. This fact changes the treatment modality. It indicates that RPLND would not be adequate treatment in children and would result in complications like chylous ascities, post-operative bowel obstruction, wound infection and subsequently ejaculatory dysfunction.

CONCLUSION

Pre-pubertal testicular tumors are rare but result in great anxiety and burden on the family when they do occur. Testicular germ cell tumors in infants are distinct from those in adults. In recent years the prognosis of testicular tumors, even in metastatic disease, has changed dramatically with combination chemotherapy [6]:In stage I 99-100%; In stage II 95-98%; In stage III 45%-75%. Despite this good prognosis, the parents have many reservations regarding the treatment and its effects on the child's growth and particularly on future fertility.

REFERENCES

1. Kato N, Tamura G, Fukase M, Shibuya H, Motoyama T. Hypermethylation of the RUNX3 gene promoter in testicular yolk sac tumor of infants. Am J Pathol. Aug 2003;163(2):387-91. | 2. Talerman A. Endodermal sinus (yolk sac) tumor elements in testicular germ-cell tumors in adults: comparison of prospective and retrospective studies. Cancer. Sep 1 1980;46(5):1213- | 3. Huang H, KO SF, Chuang JH, Jeng YM, Sung MT, Chen WJ. Pprimary yolk sac tumor of the urachus; Arch Pathol Lab Med. 2002;126:1106-9. | 4. Yilmaz A, Bayraktar B, Sagiroglu J, Gucluer B. A case report: Giant seminoma in an undescended testis presenting as an abdominal wall mass | 5. Christopher SC. Prepubertal testicular and paratesticular tumors: Medscape reference.2011 web MD, LLC. | 6. Presti JC Jr. Genital tumors. 17th ed. In: Tanagho EA, McAnich JW, editors. Smith's general urology. New York: McGraw Hill. 2008. p. 375-87. |