Research Paper Medical Science

Ticking Abdominal Bomb: Primary Volvulus of the Small Intestine

Dr.Anil Kumar M.S	PROF OF SURGERY JSS HOSPITAL MYSORE
Dr. RAXITH SRINGERI R	SENIOR RESIDENT DEPT OF SURGERY JSS HOSPITAL, RAMANUJA ROAD MYSORE.
DR. HARISH S	ASSOCIATE PROF DEPT OF SURGERY JSS HOSPITAL MYSORE
Dr. SAI SARATH CHANDRA	POST- GRADUATE JSS HOSPITAL, MYSORE
DR.SINDHURI K	POST- GRADUATE JSS HOSPITAL, MYSORE

ABSTRACT

Small bowel volvulus is an occasional cause of mechanical intestinal obstruction in our practice causing diagnostic problems. We report a case of primary small bowel volvulus with gangrene. A 35-year-old female who presented with features of acute intestinal obstruction, which at laparotomy revealed a primary small bowel volvulus with a gangrenous loop of ileum. The patient was resuscitated and had exploratory laparotomy; with operative findings of a twisted loop of gangrenous ileum adjoining the ileocecal valve.

KEYWORDS volvulus, small bowel, gangrene bowel

INTRODUCTION:

- The causes of intestinal obstruction are mechanical and functional. Among the mechanical causes, volvulus is classified among the miscellaneous causes .
- It is a relatively rare condition in the western world but is more common in the African and Asian population. The annual incidence is around 24 to 60 per one lakh population.
- There are two types; primary and secondary. The typical patient of primary small bowel volvulus is a young adult male, who is muscular, a farmer from a rural area whose diet is mainly cereal and high fiber. Among the predisposing factors to primary small bowel volvulus are, the presence of long mobile mesentery and a short mesenteric base, which makes the bowel loop susceptible to twisting.
- We present a case of primary small bowel volvulus (SBV) which is rare entity.

CASE REPORT

- 35-year-old female patient presented to the hospital with complaints of abdominal distension and pain in the central abdomen with obstipation for 5 days and breathlessness since 2 days. She had 2 normal deliveries previously. There was no history suggestive of any eating disorders or any previous abdominal surgeries.
- Examination of the abdomen revealed moderate distension, with minimal movement on respiration and marked guarding preventing further palpation. There was marked Right iliac fossa tenderness and the bowel sounds were diminished.
- An erect abdominal x-ray showed multiple air-fluid levels and ultrasonography suggested a small bowel obstruction
- Exploratory laparotomy and the findings at operation included a segment of ileum about 30 cm black in color twisted 360° on its mesentery. Gangrenous loop of twisted loop of ileum... Segmented resection and anastamosis done
- Postoperatively the patient recovered well. The bowel sounds were heard in 48 hours and the quantity of the Ryle's tube aspiration decreased, oral feeding was started. The drain tube was removed on the fourth postoperative day and the sutures were removed on the eighth postoperative day.

DISCUSSION:

- The origin of the word volvulus is from the Latin term volvere which means to turn or roll. Volvulus is the twisting of a hollow organ about its mesentery which results in obstruction and hampered venous return followed by ischemia.
- The incidence of small bowel volvulus compared to caecal and sigmoid volvulus is very low. The reported annual incidence ranges from 1.5 to 5.7 per one lakh population in the Western world as compared to 24 to 60 per lakh population (0.024-0.06%) in Africa and Asia.
- The symptoms of abdominal pain, distention and vomiting are nonspecific and common to other causes of upper intestinal obstruction. No specific diagnostic clinical signs or abnormalities in the laboratory or radiologic findings are typical of primary small bowel volvulus.
- A popular theory for SBV is that rapid filling of the proximal intestines with high bulky chyme pulls it down into the pelvis and pushes the empty distal bowel loops upward, thereby initiating a twist or volvulus.
- Immediate laparotomy is advocated in these patients, and there is no room for conservative management because the twisted loop of bowel carries a high risk of gangrene. Early diagnosis and surgical intervention offers the only possibility for minimizing an otherwise excessive mortality. Resection and primary anastomosis is reported to be a safe procedure.

CONCLUSION:

- Primary small bowel volvulus, a rare cause of small bowel obstruction; has no clear predisposing factors and no specific signs and symptoms, nor clear diagnostic imaging or laboratory parameters.
- Diagnosis is that of exclusion of the common causes of acute abdomen in the particular environment. Surgeons should always consider it in patients with features of acute abdominal pain due to upper intestinal obstruction and offer the patients immediate laparotomy based on that.

• Resection and primary anastomosis of the involved segment is the treatment of choice with a good prognosis

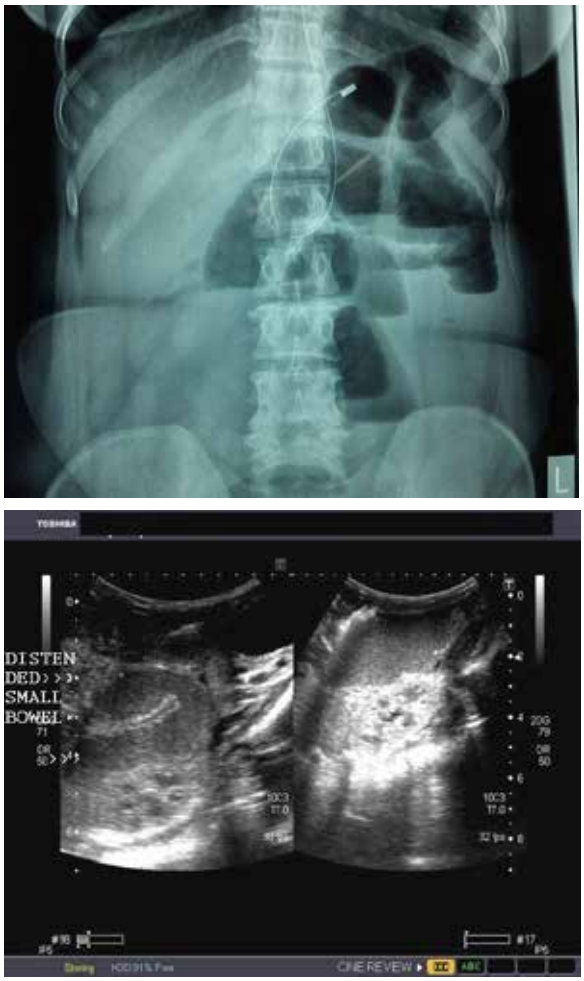

Fig 1: erect abdomen x-ray and USG abdomen.



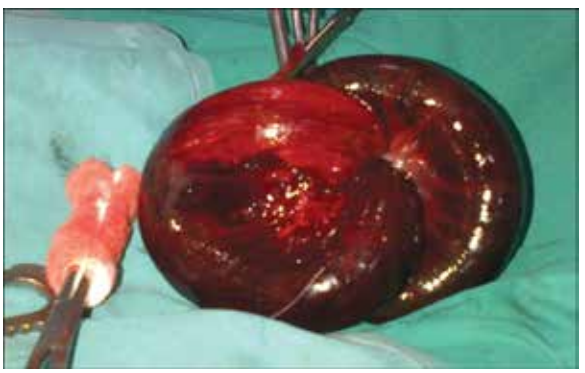

Fig2: showing specimen of ileal volulus.

REFERENCES

• Holder WD., Jr Intestinal obstruction. Gastroenterol Clin North Am. 1988 Jun;17(2):317–340. | • Frazee RC, Mucha P, Jr, Farnell MB, van Heerden JA. Volvulus of the small intestine. Ann Surg.1988 Nov;208(5):565–568. | • Agrawal RL, Misra MK. Volvulus of the small intestine in Northern India. Am J Surg. 1970 Sep;120(3):366–370 | • De Souza LJ. Volvulus of the small bowel. Br Med J. 1976 May 1;1(6017):1055–1056. | • Duke JH, Jr, Yar MS. Primary small bowel volvulus: cause and management. Arch Surg. 1977 Jun;112(6):685–688. | • Gulati SM, Grover NK, Tagore NK, Taneja OP. Volvulus of the small intestine in India. Am J Surg. 1973 Nov;126(5):661–664. | • Saidi F. The high incidence of intestinal volvulus in Iran. Gut. 1969 Oct;10(10):838–841. | • Tiwari VS, Gupta HC, Varma MM, Garg RK. Volvulus of the small intestine. Int Surg. 1982 Oct-Dec;67(4 Suppl):476–478. |