Research Paper Surgery

Traumatic Intraperitoneal Rupture of Urinary Bladder:Imaging and Operative Photographs .

Annu Babu	Department of Surgery ,Jai Prakash Narayan Apex Trauma Center ,AIIMS, New Delhi ,India
Harshit Garg	Department of Surgery ,Jai Prakash Narayan Apex Trauma Center ,AIIMS, New Delhi ,India
Amit Gupta	Department of Surgery ,Jai Prakash Narayan Apex Trauma Center ,AIIMS, New Delhi ,India
Subodh Kumar	Department of Surgery ,Jai Prakash Narayan Apex Trauma Center ,AIIMS, New Delhi ,India
Maneesh Singhal*	Department of Surgery ,Jai Prakash Narayan Apex Trauma Center ,AIIMS, New Delhi ,India

KEYWORDS

The urinary bladder present deep in bony pelvis is generally protected from external trauma.However, most bladder injuries still result from rapid-deceleration motor vehicle collisions. The other mechanisms may include fall from height, crush injuries, assault and blows to lower abdomen. Bladder injuries in a trauma setting rarely occur as isolated injuries-80-94% injuries are associated with non-urological injuries also. The most commonly associated injury is pelvic fracture associated to the extent of 83-95%.The mortality in these patients is per se not due to urological injuries but due to overall severity of multiple injuries. However, the urological injuries may still lead to high morbidity.

Bladder rupture can be extraperitoneal or intraperitoneal. Extraperitoneal bladder rupture is commonly associated with pelvic fracture while intraperitoneal bladder rupture is more commonly associated with penetrating injuries or burst fracture at the dome by direct blow to a full bladder.The clinical suspicion of bladder injury should arise if the patient has suprapubic pain or tenderness, inability to void or decreased urine output, enlarged scrotum with ecchymosis and abdominal distension or ileus. Immediate catheterization should be performed when blunt bladder rupture is suspected because the most reliable indicator is gross haematuria.In case catheterization is difficult or there is blood at meatus, retrograde urethrogram should be done to rule out concomitant urethral injury. The investigation of choice for bladder rupture is cystography. CT cytsogram is often used in trauma setting to characterize bladder injury.The extraperitoneal rupture of bladder is seen as dense,-flame shaped collection of contrast material in pelvis while intraperitoneal bladder rupture is identified as intraperitoneal extravasation of contrast outlining the loops of small bowel and/or the lower lateral portion of peritoneal cavity.The uncomplicated extraperitoneal bladder rupture can be managed conservatively with urethral catheter drainage alone. However, if a patient has any complicating features leading to fistula, abscess, or prolonged leak OR the patient is undergoing exploratory laparatomy for other associated injuries, surgical repair of bladder at the same sitting is desirable. Moreover, the intraperitoneal rupture of bladder should be managed by immediate operative repair.

The images shown below are from a 35 year old gentleman who presented to emergency Department after blunt trauma abdomen. Airway was patent, breathing was normal with Respiratory Rate-18/min and bilateral air entry equal. Patient was haemodynamically stable-Pulse Rate-89/min, BP-110/70mm Hg and FAST was positive.Pelvic Compression Test was positive. Patient was conscious and GCS was 15/15. Patient had multiple abrasions over left forearm and bilateral foot with a degloving injury of skin over right thigh and right leg.Patient complained of suprapubic tenderness and inability to void. Foley's catheterization, showed gross haematuria. Pelvic X ray revealed free fluid in peritoneal cavity and fracture of left superior and inferior pubic ramii with displacement of anterior column. Patient underwent CT cystogram which not only showed intraperitoneal extravasation of contrast lining the bowel but the presence of Foley's bulb inside peritoneal cavity. Patient underwent exploratory laparotomy and a 5cm defect in postero-superior wall of bladder was identified for which primary repair was done along with suprapubic catheterization. Suprapubic catheter removed on day 7 and per urethral catheter removed on day 21 .

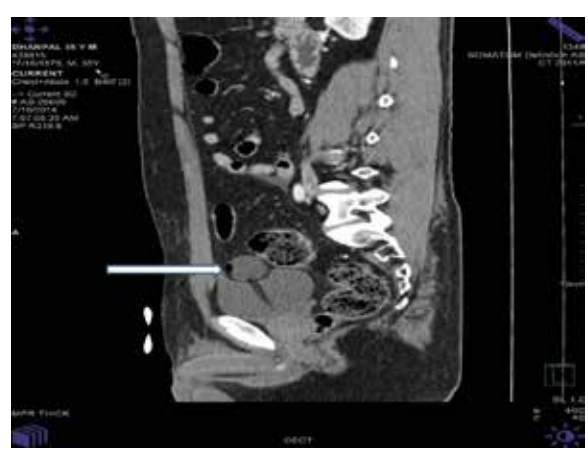

[Fig 1 Sagittal section of CT abdomen showing bulb of Foley's Catheter intraperitoneally]



[Fig 2 Coronal section of CT cystometrogram showing bulb of Foley's catheter intraperitoneally with contrast leak]

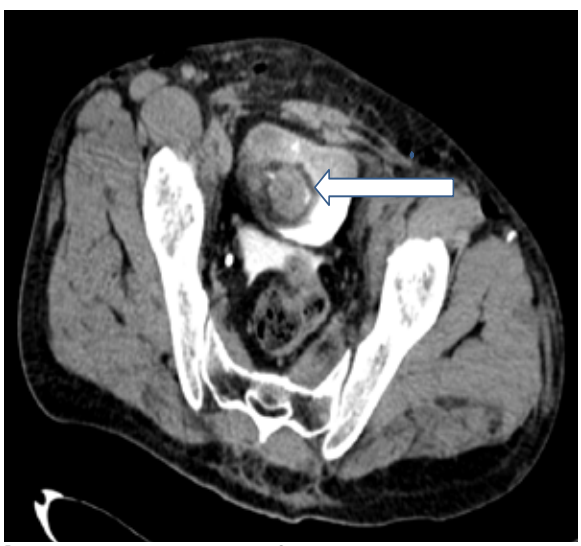

[Fig 3 Transverse section of CT cystometrogram showing bulb of Foley's catheter with contrast leak]

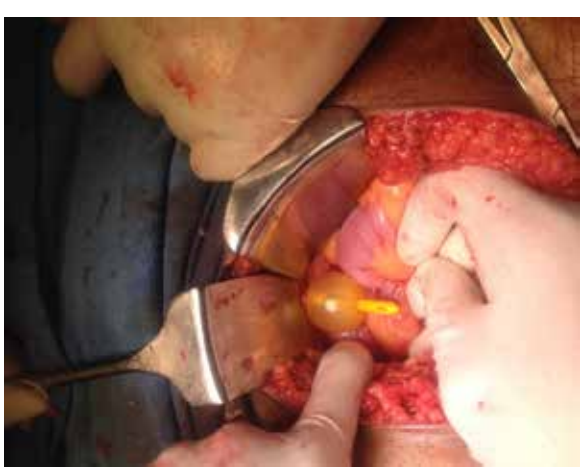

[Fig 4 Intraoperative photograph showing Bulb of Foley's Catheter in peritoneal cavity escaping through bladder rent]



[Fig 5 Intraoperative photograph Showing Intraperitoneal rupture of bladder]