Research Paper Medical Science

Treatment of an Unsual Case of Thick, Broad Frenum – A Case Report

Dr. Priyanka Agrawal	Dept. Of Periodontics, Assistant Professor, Bharati Vidyapeeth Deemed University Dental College and Hospital, Pune-43
Dr Amita Mali	Dept. Of Periodontics, HOD, Professor, Bharati Vidyapeeth Deemed University Dental College and Hospital, Pune-43.
Dr Amit Thareja	Dept. Of Prosthodontics, Associate Professor, Bharati Vidyapeeth Deemed University Dental College and Hospital, Pune-43.

ABSTRACT

An abnormal maxillary labial frenum interferes with normal function of the upper lip and oral hygiene and causes compromised esthetics. When an abnormal frenum is present frenectomy is advised. The present article presents a technique in which free gingival graft along with frenectomy was used to achieve a zone of attached gingiva at the site of abnormal frenum.

KEYWORDS frenum, free gingival graft, frenectomy

INTRODUCTION

Frena, which are triangle-shaped folds found in the maxillary and mandibular alveolar mucosa, are located between the central incisors and canine, premolar area. Frena may be long and thin, or short and broad. Labial frenum attachments have been described as mucosal, gingival, papillary, and papilla penetrating.[1] Sometimes frena is present as a thick, broad fibrous attachment and thus interferes with normal function of the upper lip and oral hygiene and causes compromised esthetics, diastema formation and gingival recession.[2]

Since the procedure of frenectomy was first proposed, a number of modifications have been developed to solve the problem caused by an abnormal labial frenum. The present article presents a technique in which free gingival graft along with frenectomy was used to achieve a zone of attached gingiva at the site of abnormal labial frenum.

CASE REPORT

A 22 year old male patient was referred from the Department of Oral Medicine and Diagnosis for an abnormal upper labial frenum. The patient had a history of fall from bike 1 year before he reported to the Bharati Vidyapeeth Dental College and Hospital in which he lost his both maxillary central incisors. The patient was well aware and concerned about the abnormal attachment of the frenum. Examination revealed a hypertrophied, thick, broad labial frenum of papillary type attachment. An adequate amount of attached gingiva was present at the maxillary anterior region without any mucogingival problems except between two central incisors where an unsually thick frenum was present which can hinder the prosthesis placement.

A technique of frenectomy was planned considering the patient's concern for esthetics. Free gingival graft along with frenectomy was planned considering patient's abnormally thick frenum which could compromise width of attached gingiva. Hematologic investigations were carried out and results were within normal limits. Medical history was non contributory.

SURGICAL TECHNIQUE

The maxillary anterior region was anesthetized with 1:200,000 lidocaine hydrochloride with adrenaline (Xylocaine 2% Adrenaline, Astra Zeneca) by local infiltration on the buccal and palatal aspects.

A V-shaped full thickness incison was placed at the gingival base of the frenal attachment with an external bevel. Tissue along with periosteum was separated from underlying bone. The initial incision resulted in a V shaped defect on the gingival side. Fibrous tissue attached to the lip was dissected with scissors, and undermining of the labial mucosa was done.

An aluminium foil template of the recipient site was made and placed over the donor site in the palate to harvest free gingival graft. The harvested Free Gingival Graft (FGG) from the palate was then placed at the recipient site and sutured by 4-0 silk suture at the lateral borders and to the underlying periosteum. The graft was firmly held in place using digital pressure for 2 minutes and Coe-pak was placed at the surgical site both at donor site and over the graft. Antibiotics and Analgesics were prescribed. 0.2% Chlorhexidine mouthwash was prescribed after two days of surgery for 2 weeks during the post operative period. Post operative instructions were given. Sutures were removed on the 14th day and the patient was scheduled for follow up recall visits at 1, 2 and 3 months.

The 3 month follow up revealed a zone of attached gingiva in the area previously covered by the thick abnormal frenum. Normal healing was seen without any visible complication. 3 months post operative results showed adequate width of attached gingiva for proper placement of prosthesis and maintenance of good oral hygiene.



Fig. 1. Maxillary thick broad labial frenum before frenectomy



Fig.2. Excison of the maxillary frenum

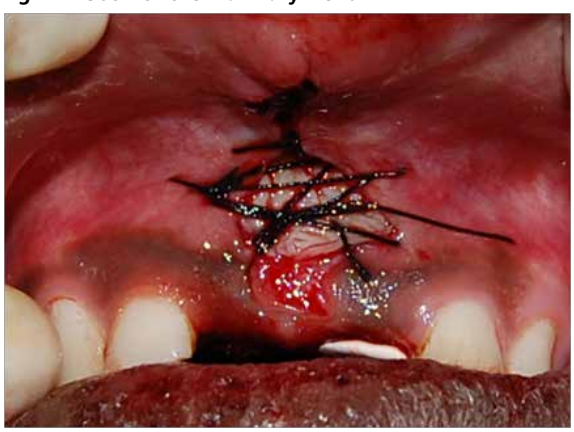

Fig.3. Free gingival graft in place, with connective tissue side against the recipient bed

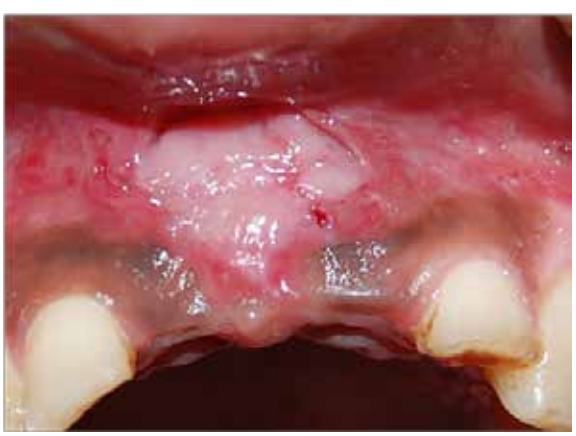

Fig. 4. 14 days Post operative result



Fig.5. 3 months Post operative result with temporary prosthesis

DISCUSSION

Various surgical techniques have been proposed for the correction of an abnormal maxillary labial frenum. Some of these produce unsatisfactory results; for example a simple frenectomy that is made with a V- shaped incision that leaves a longitudinal surgical incision and scarring, which may lead to periodontal problems and an unesthetic appearance.[1]

Several other procedures have combined frenectomy with a lateral pedicle graft, semilunar flap. The lateral pedicle graft technique also positions the unilateral pedicle at the midline but prevents complete coverage of the wound. In the technique presented, a free gingival autograft was harvested from the palate, which completely covered the V- shaped defect on the gingiva and act as a tissue dressing, thus facilitating healing by primary intention and minimizing any chance of scar formation.[3]

Techniques like simple excision and modification of V- rhomboplasty fail to provide satisfactory esthetic results in the case of thick, braod, hypertrophied frenum. This may be due to an inability to achieve primary closure at the centre, consequently leading to secondary intention healing at the wide exposed wound. It may be a matter of concern in the case of a high smile line exposing anterior gingiva.[4]

The technique presented here where free gingival graft was placed after frenectomy provides many advantages, such as gain in attached gingiva in the region previously covered by the frenum, healing by primary intention, minimal scar formation, and prevention of coronal reformation. Disadvantage of placing free gingival graft in maxillary frenum is color mismatch but in cases of thick broad frenum where gain in width of attached gingiva is required this technique is preferable.[5] The technique is reliable and easy to perform and provides excellent results in cases of thick, broad frenum.

REFERENCES

1. Huang WJ, Creath CJ. A midline diastema: A review of its etiology and treatment. Pediatr Journal, 1995;17:171-179. | 2. Camargo PM, Melnick PR. The use of free gingival grafts for aesthetic purposes. Perio 2000; vol 27,2001:72-76. | 3. Hiatt WH. Free gingival graft or frenectomy? J Colo Dent Assoc 1968, Mar:46(2):7-9. | 4. Bagga S, Bhat M. Esthetic management of the upper labial frenum: A novel frenectomy technique. Quintessence Int 2006;37:819-823. | 5. Serge Dibart, Mamdouh K. Labial frenectomy alone or in combination with a free gingival autograft.practical periodontal plastic surgery; Chapter 11: 53-55. |