Research Paper Medical Science

Trichilemmal Carcinoma- A Case Report

Dr. Naveen. T	Associate Professor Department Of Radiation Oncology Kidwai Memorial Institute Of Oncology
Dr..Karthikeyan. S	Department of Radiation Oncology, Kidwai Memorial Institute of Oncology, Dr. M . H. Marigowda road, Bangalore – 560 029
Dr. Siddanna R P	Department of Radiation Oncology, Kidwai Memorial Institute of Oncology, Dr. M . H. Marigowda road, Bangalore – 560 029
Dr. Sridhar. P	Department of Radiation Oncology, Kidwai Memorial Institute of Oncology, Dr. M . H. Marigowda road, Bangalore – 560 029
Dr.Govardhan.H.B	Department of Radiation Oncology, Kidwai Memorial Institute of Oncology, Dr. M . H. Marigowda road, Bangalore – 560 029
Dr.Lokesh V	Department of Radiation Oncology, Kidwai Memorial Institute of Oncology, Dr. M . H. Marigowda road, Bangalore – 560 029
Dr.Tanvir Pasha	Department of Radiation Oncology, Kidwai Memorial Institute of Oncology, Dr. M . H. Marigowda road, Bangalore – 560 029
Dr.Sugashwaran J	Department of Radiation Oncology, Kidwai Memorial Institute of Oncology, Dr. M . H. Marigowda road, Bangalore – 560 029

ABSTRACT

Trichilemmal carcinoma (TLC) is a rare adnexal tumour related to the external hair sheath and only few cases are reported in literature. We describe the case of TLC on the scalp treated with surgery and radiotherapy.

KEYWORDS Trichilemmal carcinoma, Adnexal tumor, Surgery, Radiotherapy

TINTRODUCTION:

The term trichilemmal carcinoma (TLCA) was originally described as a clinical entity by Headington in 1976. It is considered a carcinoma of low malignancy for presenting low frequency and rare metastases[1] . As a rule, it appears as a solitary lesion after the fifth decade of life[2].

The diagnosis is established by means of histopathological examination using hematoxylin-eosin

staining which, when necessary, is complemented by immunohistochemistry of the lesion. The treatment may be Mohs' technique or simple lesion excision. We report the case of a patient with recurrent trichilemmal carcinoma on the same location treated with surgery and radiotherapy.

CASE REPORT:

A 28 year old woman admitted to our hospital with scalp ulceroproliferative tumor. She gives history of swelling over the past 4 years with twice excision of the tumor. The tumor was gradually progressive in nature. On thorough medical evaluation, she was observed to be in good general condition with a Karnofsky performance score of 90. Local examination revealed the lesion is on the occipital area of the scalp measuring 10x10 cms, with irregular and nodular margins. The edges are everted. Rest of the clinical examination was insignificant.

To evaluate the underlying bone involvement and the exact extent of tumour, radiological workup was done with X-ray skull and computed tomography (CT) scan which showed a soft tissue mass with no bone involvement (Fig 1-2). On histopathological examination of the biopsy specimen revealed hyper chromatic tumor cells with scanty cytoplasm, separated by fibrous septa with well circumscribed margins and abrupt keratinisation (Fig 3-4). The final diagnosis of trichilemmal carcinoma was made.

An ample lesion resection was performed. Owing to the recurrent nature of the tumor the patient

was subjected to adjuvant radiotherapy with a total dose of 6000cGy. The patient has been on regular follow up for the last 3 years and is asymptomatic with no evidence of recurrence clinically.

DISCUSSION:

TLC is very rare tumor and it is considered to be malignant counter part of trichilemmal tumor.TLC was first proposed by Headington to describe a histologically invasive and cytologically atypical clear cell malignancy of adnexal keratinocytes. It originates from the external root sheath of the hair follicle and clinically, it may be mistaken for a squamous cell

carcinoma, basal cell carcinoma, nodular melanoma or keratoacanthoma[1,6]. It usually occurs in sun exposed part of older individuals. Usually these lesions present as nodular , ulcerated ore exophytic with kertotic or crusted appearance[1,2,3,4].Its clinical course is more of locally aggressive, recurs locally but few reports of metastasis are reported .Excision is the treatment of choice.[4] In big lesions like our case biopsy will be sufficient for diagnosis.





Fig 1 & 2: Computed tomography (CT) scan showing a soft tissue mass with no bone involvement in left parietal region

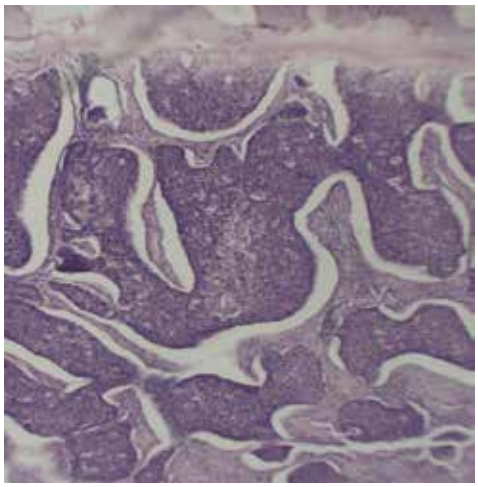

Fig : 3
An ulcerated neoplasm composed of solid blocks with a lobular growth pattern reaching as far as the deep dermis

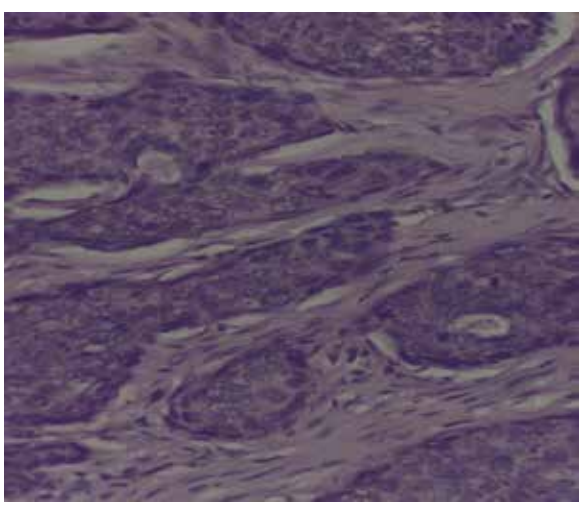

Fig:4
A circumscribed, although infiltrative epithelial neoplasm showing hyper chromatic tumor cells with scanty cytoplasm, separated by fibrous septa with abrupt keratinisation

REFERENCES

1. Nemetz MA, Cunha RM, Reeck P, Carreirão Neto W, Moreira MTS, Coelho MS.Carcinoma triquilemal: relato de um caso. Rev Bras Otorrinolaringol 2004;70:832-5. | | 2. Garrett AB, Scott KA. Trichilemmal carcinoma: a case report of a rare skin cancer occurring in a renal transplant patient. Transplantation. 2003;76:1131. | | 3. Lai TF, Huilgol SC, James CL, Selva D. Trichilemmal carcinoma of the upper eyelid. | Acta Ophthalmol Scand. 2003;81:536-8. | | 4. Peryassú BC, Peryassú RC, Peryassú MA, Maceira JP, Ramos-E-Silva M. Trichilemmal carcinoma - a rare tumor: case report. Acta Dermatovenerol Croat.2008; 16:28-30. | | 5. Garrett AB, Azmi FH, Ogburia KS. Trichilemmal carcinoma: a rare cutaneous malignancy: a report of two cases. Dermatol Surg. 2004;30:113 | | 6. Chan KO, Lim IJ, Baladas HG, Tan WT. Multiple tumour presentation of trichilemmal carcinoma. Br J Plast Surg. 1999;52:665-7. | | 7. Fillipou DK et al: Malignant proliferating trichilemmal tumour of the scalp. Report of a case and a short review of the literature. Ann Ital Chir. 2006 Mar-Apr;77(2):179-81. | | 8. Allee JE et al:Multiply recurrent trichilemmal carcinoma with perineural invasion and cytokeratin 17 positivity. Dermatol Surg :2003 Aug;29(8):886-9