Research Paper Obstetrics and gynaecology

Wernicke's Encephalopathy – A Rare Complication of Hyperemesis Gravidarum

Dr Thaj M | Assistant professor, Travancore medical college, Umayanalloor , Kollam, Kerala

ABSTRACT

Wernicke's encephalopathy (WE) is a rare but known complication of severe hyperemesis gravidarum caused by thiamine deficiency. This article presents an unusual case that occurred at our institution .18 years old G2P0L0A1 presented at our medicine opd with neurologic symptoms .she gave history of prolonged vomiting..With futher evaluation and the characteristic MRI findings, our patient was diagnosed as a case of WE . The patient was treated with thiamine and her condition improved from the next day. The diagnosis of WE is clinical and can be rapidly confirmed by magnetic resonance imaging. We emphasize the importance of thiamine supplementation to women with prolonged vomiting in pregnancy, especially before intravenous or parenteral nutrition. We also underline the necessity to promptly replace vitamin B1 when neurologic symptoms and/or signs develop in a patient with hyperemesis gravidarum.

KEYWORDS

History
18 Year old second gravida with 19 wks pregnancy her first pregnanacy was vesicular mole evacuation

done 1 year back no history of follow up.

Admitted in medical ward on 09/09/13 with history of

Blurred vision

General weakness since one week

Instability to walk

She gives h/o hyperemesis was on IV fluids and without polybion most of the time.

. Examination
O/E pt conscious, well oriented, vitals normal

Nystagmus ++ with Ataxic gait

CBC,LFT,RFT was normal except hypokalemia

Ophthalmology & Neurology consultation done

Blurred disc margins and Peripapillary oedema+

MRI brain showed hyper intensity of mamillary bodies suggestive of WE

Treatment
Treated with injection Thiamine ,IV fluids with polybion & potchlor

Patient condition improved from second day onwards and on day 5 nystagmus verymuch improved and gait became better

Anomaly scan done on 11/09/13 showed less than 2mm intracardiac echogenic area in both ventricle and echogenic bowel . So adviced karyotyping .

Discussion



Figure 1

Etiology Normally …
- Thiamine plays a vital role in the metabolism of carbohydrates as a cofactor for several essential enzymes in the Krebs cycle & the pentose phosphate pathway (include alpha-ketoglutarate dehydrogenase, pyruvate dehydrogenase, & transketolase).

At thiamine deficiency, thiamine-dependent cellular systems begin to fail, resulting eventually in cell death.

Thiamine-dependent enzymes à essential role in cerebral energy utilization , deficiency propagates brain tissue injury by inhibiting metabolism in brain regions with higher metabolic demands & high thiamine turnover.

Causes of thiamine deficiency
- Chronic alcoholism, because it affects thiamine uptake & utilization
- Prolonged starvation
- Hyperemesis gravidarum
- Bariatric surgery
- Hemodialysis with end stage renal disease

Diagnosis of WE
- WE can be diagnosed in pts with 2 or more main symptoms noted in Figure 1
- Erythrocyte transketolase levels
- (0-15% is normal, 15-25% indicated thiamine deficiency, >25% severe deficiency).
- Blood pyruvate & lactate measurements.

- EEG
- Biomarker: assay for thiamine
- MRI – Brain (Figure 2)
- contrast enhancement in the thalamus and the mammillary bodies
- periventricular, periaqueductal and mamillary body oedema.
- small vessel ischemic lesions.
- dilatation of the ventricular system.

MRI images

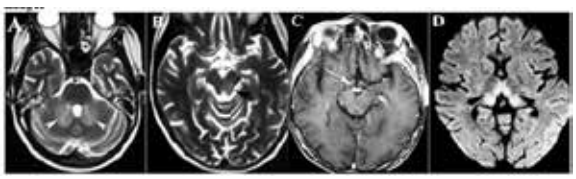

Figure 2

Treatment

Thiamine should be started immediately

- iv or im
- therapeutic response is often dramatic from 1st day
- Administration of thiamine can improves the patient's condition in almost all cases; hwever, persistent neurologic dysfunction is common.
- High doses of TH 500 mg given 8th hourly for 2-3 days followed by 250 mg per day once daily until the patient tolerates oral TH.

Complications

Complications of Wernicke's encephalopathy may include the following:

- Korsakoff psychosis
- Alcohol withdrawal
- Acute precipitation of Wernicke encephalopathy
- Congestive heart failure
- Gastrointestinal beriberi[3]
- Lactic acidosis[4

Prognosis

Administration of thiamine improves the patient's condition

Among patients surviving, develop Korsakoff psychosis, only about 20% eventually recover completely during long-term follow-up care.

Typical residual finding : nystagmus, gait ataxia, Korsakoff syndrome

A worse outcome may be expected in late-stage Wernicke encephalopathy, which is associated with elevated spinal fluid protein levels & diffuse slowing of postsynaptic potentials on EEG.

Alcoholics have worst prognosis than non alcoholics. Death or persistent sequelae have also been reported to occur in non alcoholic patients, especially in those with hyperemesis gravidarium.

Conclusion

Since WE is commonly assosciated with chronic alcoholism, its possibility in the context of pregnancy is not usually discovered. The disease may complicate other neurologic disorders due to nutritional deficiency, but can be prevented by the timely administration of parenteral thiamine.

Learning Objectives: After completion of this article, the reader should be able to list the signs and symptoms of Wernicke encephalpathy associated with hyperemesis gravidarum, outline the methods to make a clinical diagnosis, and recall the importance of thiamine supplementation in patients with prolonged hyperemesis gravidarum. Wernicke's Encephalopathy: A rare but Predictable and preventable Complication of Hyperemesis Gravidarum.

Acknowledgemaent:

Dr N Syamala , Professor and HOD, OBG Dept, Travancore medical college, Kollam

Dr Sundeep Asisstant Professor, Dept of General Medicine, Travancore Medical college,Kollam