



Advances and New Approaches in Endodontic Surgery - A Review

Emre İriboz	Marmara University Faculty of Dentistry. Department of Endodontics.
Burçin Arıcan Öztürk	Marmara University Faculty of Dentistry. Department of Endodontics.
Bilge Tarçın	Marmara University Faculty of Dentistry. Department of Restorative Dentistry.

ABSTRACT

Endodontic surgery has now evolved into endodontic microsurgery. By using enhanced equipment, instruments and materials that match biological concepts, we believe that microsurgical approaches produce predictable outcomes in the healing of lesions of endodontic origin. The classic view that endodontic surgery is a last resort is based on past experience with accompanying unsuitable surgical instruments, inadequate vision, frequent postoperative complications, and failures that often resulted in extraction of the tooth. As a consequence, the surgical approach to endodontic therapy, or surgical endodontics, was taught with minimum enthusiasm at dental schools and was practiced by very few in private practices. Stated simply, endodontic surgery was not considered to be important within the endodontist's domain. Fortunately, this changed when the microscope, microinstruments, ultrasonic tips, and more biologically acceptable root-end filling materials were introduced in the last decade. The concurrent development of better techniques has resulted in greater understanding of the apical anatomy, greater treatment success and a more favorable patient response. Our ultimate goal in this study is to assertively teach the future generation of graduate students and also train our colleagues to incorporate these techniques and concepts into everyday practice.

KEYWORDS

Apical resection, hemisection, microsurgery, operating microscope, ultrasonic tips.

Introduction

By Surgical Endodontics one refers to that branch of Dentistry that is concerned with the diagnosis and treatment of lesions of endodontic origin that do not respond to conventional endodontic therapy or that cannot be treated by conventional Endodontic therapy. The purpose of Surgical Endodontics is to achieve the three dimensional cleaning, shaping and obturation of the apical portion of the root canal system which is not treatable via an access cavity, but only accessible via a surgical flap [1]. For this reason it is preferable to use the term Surgical Endodontics rather than Endodontic Surgery, in as much as the procedure should be planned and carried out as an endodontic procedure via surgical access and not a surgical procedure done for endodontic reasons.

Once a diagnosis of Endodontic failure has been made, it is necessary to understand what the cause of the failure was so that successively the possibility of correcting the failure by orthograde retreatment can be evaluated. Only in the case where this possibility does not exist or better still after failure of the non-surgical therapy carried out to resolve the problem, only then is one authorized to intervene surgically. Apical Surgery in other words is not a substitute for incomplete debridement and poor endodontics [2].

During the past 20 years, endodontics has seen a dramatic shift in periradicular surgery and the part it plays in the delivery of endodontic services. Previously it was considered the treatment of choice when nonsurgical treatment had failed or there was the presence of large or intruding periapical lesions, overfilled canals, incomplete apical formation, or destruction of the apical constrictor by overinstrumentation. Today, a more conservative approach solves many of these problems sans surgery [3].

Currently the technique and instruments for clinical retreatment of endodontic failures are so refined that the cases that

for certain have to be treated surgically because they cannot be retreated by orthograde means are becoming fewer. Often a high level of Surgical Endodontics experience masks the operators inability to carry out a correct cleaning, shaping and three dimensional obturation of the root canal system by non-surgical means [4].

The Differences between Traditional and Microsurgical Techniques

Success rates for contemporary endodontic therapy are in excess of 90%, depending on the skill of the clinician and the teeth involved. Surgical endodontic procedures are usually undertaken when conventional (orthograde) endodontics has failed. However, the chances of successful re-treatment of a tooth with a failed root filling are higher when non-surgical endodontics is repeated (wherever possible) rather than by undertaking a surgical approach. Surgical endodontics may therefore not be the first option when conventional root canal treatment fails [5]. Endodontic surgery is perceived as difficult because the surgeon must often approximate the location of anatomical structures such as large blood vessels, the mental foramen, and the maxillary sinus. Although the chances of damage to these structures are minimal, traditional endodontic surgery does not have a positive image in the dental profession because of its invasive nature and questionable outcome [6, 7].

If we accept the premise that the success of endodontic surgery depends on the removal of all necrotic tissue and complete sealing of the entire root canal system, then the reasons for surgical failure by the traditional approach become clear. Examination of failed clinical cases and extracted teeth by surgical operating microscopes reveal that the surgeon cannot predictably locate, clean, and fill all the complex apical ramifications with traditional surgical techniques. These limitations can only be overcome with the use of the microscope with magnification and illumination and the specificity of micro-

surgical instruments, especially ultrasonic instruments. Endodontic microsurgery, as it is now called, combines the magnification and illumination provided by the microscope with the proper use of new microinstruments [7-10].

Endodontic microsurgery can be performed with precision and predictability and eliminates the assumptions inherent in traditional surgical approaches. The advantages of microsurgery include easier identification of root apices, smaller osteotomies and shallower resection angles that conserve cortical bone and root length. In addition, a resected root surface under high magnification and illumination readily reveals anatomical details such as isthmuses, canal fins, microfractures, and lateral canals. Combined with the microscope, the ultrasonic instrument permits conservative, coaxial root-end preparations and precise root-end fillings that satisfy the requirements for mechanical and biological principles of endodontic surgery [6, 10]. Table 1 shows the primary differences between the traditional and microscopic approach to endodontic surgery.

Table 1 shows the primary differences between the traditional and microscopic approach to endodontic surgery [21].

	Traditional	Microsurgery
1. Osteotomy size	Approx. 8–10 mm	3-4 mm
2. Bevel angle degree	45–65 degrees	0 - 10 degrees
3. Inspection of resected root surface	None	Always
4. Isthmus identification & treatment	Impossible	Always
5. Root-end preparation	seldom inside canal	always within canal
6. Root-end preparation instrument	Bur	Ultrasonic tips
7. Root-end filling material	amalgam	MTA
8. Sutures	4x0 silk	5x0, 6x0 monofilament
9. Suture removal	7 days post-op	2–3 days post-op
10. Healing Success (over 1 yr)	40–90%	85–96.8%

Table 1. Differences between traditional and microsurgical approaches.

Indications and Contraindications for Endodontic Surgery

Several factors have resulted in a significant impact on the indications for and the application of endodontic surgery [11]. Apical surgery belongs to the field of endodontic surgery that also includes incision and drainage, closure of perforations, and root or tooth resections. The objective of apical surgery is to surgically maintain a tooth that has an endodontic lesion which cannot be resolved by conventional endodontic (re-) treatment. Even though the success rate of nonsurgical endodontic treatments is high, failures do occur. Many retrospective studies have established endodontic success rates, ranging from a high of 96% to a low of 53%. Additionally, in recent years, there has been an increasing interest in endodontic retreatment procedures. Studies reporting the success rate for nonsurgical retreatment indicate successes as low as 62% to as high as 98% [12-16]. This emphasis on nonsurgical re-treatment of endodontic failures has probably had the single greatest impact on the indications for surgical intervention in the treatment of endodontic pathosis. The evaluation of a case referred for apical surgery must always include a careful weighing of the advantages and disadvantages of surgical and non-surgical intervention. Advantages and disadvantages of all procedures should be discussed with the referring dentist and the patient. Written informed consent must be obtained from the patient prior to apical surgery. The indication for apical surgery must be based on a careful and thorough clinical and radiographic examination.

Few absolute contraindications to endodontic surgery exist. Most contraindications are relative, and they are usually limited to three areas: the patient's medical status, anatomic considerations, and the dentist's skills and experience. Contraindications for endodontic surgery include the following: the tooth has no function (no antagonist, no strategic importance serving as a pillar for a fixed prosthesis), the tooth cannot be restored, the tooth has inadequate periodontal support, or the tooth has a vertical root fracture. Additional general contraindications may be an uncooperative patient or a patient with a compromised medical history for an oral surgical intervention. Advances in medicine have dramatically increased life expectancy and the survival rate from most of today's diseases. Dentists are, with increasing frequency, being asked to treat medically compromised patients. When considering performing any surgical procedure on a patient who reports a major systems disorder (cardiovascular, respiratory, digestive, hepatic, renal, immune, or skeletomuscular), a thorough medical history is mandatory. Following the identification of all potential medical complications and a review of the patient's current drug regimen, a consultation with the primary care physician or specialist may be in order. The dentist should explain to the physician the needed endodontic surgical treatment, including a brief description of the procedure, anesthetic agents and other drugs to be used, the approximate length of time required for the procedure, and the expected length of recovery [17]. In this way, the physician can more adequately assess the medical risks involved and can assist the dentist in determining appropriate treatment modifications. These modifications may be preoperative (alteration of drug therapy, sedative or hypnotic, systemic antibiotics), intraoperative (nitrous oxide, intravenous sedation), or postoperative (reinstatement of drug therapy, sedatives, and analgesics).

Majority of the anatomic considerations present contraindications that must be addressed for each individual patient. The major anatomic considerations of importance to endodontic surgery involve the nasal floor, the maxillary sinus, the mandibular canal and its neurovascular bundle, the mental foramen and its neurovascular bundle, and anatomic limitations to adequate visual and mechanical access to the surgical site. A skilled surgeon with the needed armamentarium is usually able to circumvent these anatomic limitations and accomplish successful endodontic surgery [18]. It is imperative that dental professionals keep in mind that all treatment rendered by them to their patients must be in the patients' best interest and at the highest quality possible. As a professional, one has an obligation to know one's limitations of clinical skills and to confine treatment efforts to be consistent with those limitations. Unless the general practitioner has had extensive surgical training and experience, the majority of endodontic surgical procedures should be done by trained endodontic specialists. When receiving care of a specialized nature, patients need and deserve treatment that meets the standard of care delivered by competent practitioners who are trained as specialists [19]. The standard of care in dentistry is that practiced by the specialist in any given dental discipline [20].

Use of Operating Microscope for Microsurgery

For years, many dental practitioners have benefited from the use of vision-enhancement devices, such as loupes, surgical telescopes, and head-mounted surgical fiber-optic lamps. It is generally accepted that the better the visual access to the operating field, the higher the quality of treatment that can be accomplished.

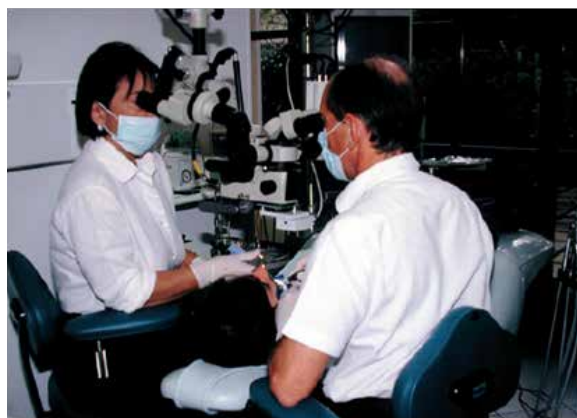One of the most significant developments in the past decade in endodontics has been the use of the operating microscope for surgical endodontics [21]. The medical disciplines incorporated the microscope into practice 20 to 30 yr ahead of us. It is now inconceivable that certain procedures in medicine would be performed without the aid of the microscope.

Microscopy is a young specialty in a great and continuous evolution, not only in the field of application, but also in the development of new instruments and techniques. Dentistry rests

its quality standard on the realization of the higher possible precision. Concepts based on evolution, advanced technology applications, characteristics of perfected materials have brought major improvement on long-term results and an excellent predictability in the surgical techniques. In particular, the extensive use of the operating microscope in conventional endo has enlarged the indications for the positive treatment of failures and restricted the indications for surgical treatment[22].

The operating microscope provides important benefits for endodonticmicrosurgery in the following ways:

1. The surgical field can be inspected at high magnification so that small but important anatomical details, e.g. the extra apex or lateral canals, can be identified and managed. Furthermore, the integrity of the root can be examined with great precision for fractures, perforations, or other signs of damage.
2. Removal of diseased tissues is precise and complete.
3. Distinction between the bone and root tip can easily be made at high magnification, especially with methylene blue staining.
4. At higher magnification the osteotomy can be made small (3-4 mm) and this results in faster healing and less postoperative discomfort.
5. Occupational and physical stress is reduced since using the microscope requires an erect posture. More importantly, the clinical environment is less stressful when clinicians can clearly see the operating field (Fig. 1).



6. The number of radiographs may be reduced or may be eliminated because the surgeon can inspect the apex or apices directly and precisely.
7. Video recordings or digital camera recordings of procedures can be used effectively for education of patients and students.
8. Communication with the referring dentists is improved significantly [23].

Figure 1. A modern clinical environment in which the microscope provides not only a clinical but also an ergonomic advantage.

Given these clinical as well as occupational advantages, performing apical surgery without magnification is no longer adequate or defensible. It is disadvantageous for the treating endodontist as well as for the patient. It is interesting that there is a substantial difference in surgery outcome between studies using the microscope [24] and those that do not [25, 26]. Although these are not randomized controlled studies directly comparing these two approaches, we believe that surgical outcomes are improved when the clinician can examine the resected root surface carefully, and that omission of this most critical step in microsurgery has a direct effect on the outcome of the surgery. Some may argue that using loupes is good enough. However, the fact is that inspecting the resected root

surface with the highest magnification of the microscope is not even good enough. To completely see all the critical anatomical details of the root surface it has to be stained with methylene blue. Using loupes is the first step and a welcome change from unaided vision, but effective magnification and illumination requires the operating microscope.

Hemostasis

The main purpose of anesthetics in clinical dentistry, in particular endodontics, is for local anesthesia. In endodontic surgery, however, local anesthesia has two distinct purposes: anesthesia and hemostasis. Thus, a high concentration of vasoconstrictor containing anesthetic such as epinephrine, is preferred to obtain effective vasoconstriction for lasting hemostasis [27, 28]. Some claim that the amount of epinephrine in an infiltration or block injection in dental procedures produces little or no systemic effects [29, 30]. Others believe that the amount of epinephrine given as local anesthetic causes systemic effects [31, 32]. Virtually all of the adverse effects associated with epinephrine are dose dependent. Currently recommended maximum dosage of epinephrine 1:50,000 in local anesthetics 2% lidocaine for adults for good hemostasis is 5.5 cartridges to reach 0.2 mg [33]. The use of this dosage is recommended for local anesthesia in the majority of cases. With severe cardiac patients, a consultation with his or her physician before the surgery is highly recommended and should be routine in the surgery protocol.

Because many anesthetics are vasodilators the use of anesthetics without vasoconstrictors, such as plain mepivacaine (e.g. 3% Carbocaine), is not recommended as this will lead to excessive bleeding during surgery.

Topical hemostats or local hemostatic agents are useful adjuncts for hemostasis. Once an incision has been made and the flap is reflected, topical hemostats, in many situations, play an important role in achieving hemostasis. They can be broadly classified by their mechanism of action [34]: There are numerous agents on the market (Table 2). Some of the popular, effective and frequently used agents are bone wax, epinephrine cotton pellet, ferric sulphate and thrombin.

Table 2. Hemostatic agents by mechanism of action.

Mechanical agents	Bone wax
Chemical agents	Vasoconstrictors (epinephrine) Ferric sulfate
Biological agents	Thrombin
Resorbable agents	Calcium sulfate Gelfoam Absorbable collagen Microfibrillar collagen Surgicel

Soft Tissue Management

The establishment of good surgical access, both visual and operative, is a requirement for all surgical procedures. Visual access enables the endodontic surgeon to see the entire surgical field. Operative access allows the surgeon to perform the needed surgical procedure(s) with the highest quality and in the shortest amount of time. This will result in the least amount of surgical trauma and a reduction in postsurgical morbidity [35].

The incision technique and flap design should be chosen according to clinical and radiographic parameters. Clinical issues include: the patient's esthetic demands; condition, biotype and width of gingival tissues, and presence of a restoration margin. Radiographic parameters consist of location and extent of the periapical lesion and status of the marginal periodontium. All surgical procedures require the intentional wounding of specific tissues, and the subsequent wound healing depends on the type of tissues wounded and the type of wound inflicted. The surgeon's goal must always be to minimize trauma to both the soft and hard tissues involved in the surgical procedure. Most periradicular surgical procedures require the raising of a mucoperiosteal flap [36].

The following management procedures have changed from

the traditional techniques. First, the semilunar incision, the most popular flap design technique with anterior teeth, is no longer recommended because of inadequate access and scar formation [37]. Second, the removal of sutures is done within 48 to 72 h, not a week [6, 10]. Third, new suture materials are monofilament, gauge 5.0 or 6.0 to provide rapid healing [6, 10]. Fourth, the papilla base incision (PBI) has been developed to prevent loss of interdental papilla height with sulcular incisions [38]. Fifth, flap retraction during the surgery is facilitated by making a resting groove in the bone, especially during mandibular posterior surgery, to ensure retraction [6]. Fundamentally, the flap designs are very similar to those of the traditional techniques: the sulcular full-thickness flap, the muco-gingival flap and vertical releasing incisions [39, 40]. The once popular semilunar flap design and the Lübeck-Ochsenbein flap design are no longer recommended.

It has been customary to remove 4.0 silk sutures after 1 wk. With the microsurgery technique, monofilament sutures are removed within 48 to 72 h for best results [6, 10]. This is enough time for reattachment to take place and the suture removal is easy and painless. Suture materials often used now are the thinner monofilament polyamide with smaller needles. The 5.0 and 6.0 sutures are ideal for microsurgery and polypropylene sutures (6/0 or 7/0) are also popular [41] (Fig. 2). The use of 4.0 silk sutures is no longer acceptable because the silk is braided and causes accumulation of plaque causing delayed healing or secondary inflammation [6].

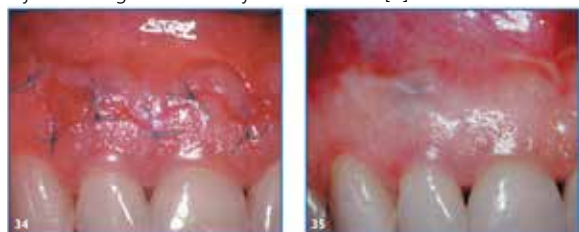

Figure 2. Micro-suturing with 5.0 and 6.0 monofilament sutures; suture removal after 48 h.

Osteotomy

Following reflection and retraction of the mucoperiosteal flap, surgical access must be made through the cortical bone to the roots of the teeth. Once the mucoperiosteal flap has been raised, the cortical bone over the root end is removed and the root end is located. The periapical pathological tissue is curetted out to enhance access and visibility of the surgical field. Where cortical bone is thin, as in the maxilla, a large periradicular lesion may result in the loss of buccal or labial cortical plate, or if a natural root fenestration is present, the tooth root may be visible through the cortical plate. In other cases, the cortical bone may be very thin, and probing with a small sharp curette will allow penetration of the cortical plate. The most difficult and challenging situation for the endodontic surgeon occurs when several millimeters of cortical and cancellous bone must be removed to gain access to the tooth root, especially when no periradicular radiolucent lesion is present [42, 43].

There is an argument about the size of the apical lesion making any difference on healing for a long time. Many studies concluded that the size of the lesion matters as well as the removal of one, or both cortical plates. These studies suggest that the larger the defect, the smaller the chance that complete healing will take place [44-47]. A recent study on healing, as evidenced by radiographic changes, showed that there is a direct relationship between the size of the osteotomy and the speed of healing: the smaller the osteotomy, the faster the healing. For instance, a lesion smaller than 5mm would take on average 6 months, a 6 to 10mm size lesion takes 7 months and larger than 10 mm requires 11 months to heal [8]. Thus, the osteotomy should be as small as possible but as large as necessary to accomplish the clinical objective. There is a tendency during surgery to enlarge the osteotomy towards the coronal margin, away from the apex. This tendency results

in excessive removal of healthy bone around the neck of the crown easily causing a perio-endo communication. When this happens, the long-term prognosis for the tooth is poor. With the microsurgical techniques, the size of the osteotomy is significantly smaller, just 3 to 4 mm in diameter.

This is just larger than an ultrasonic tip of 3 mm in length, yet allows the tip to vibrate freely within the bone cavity (Fig. 3).

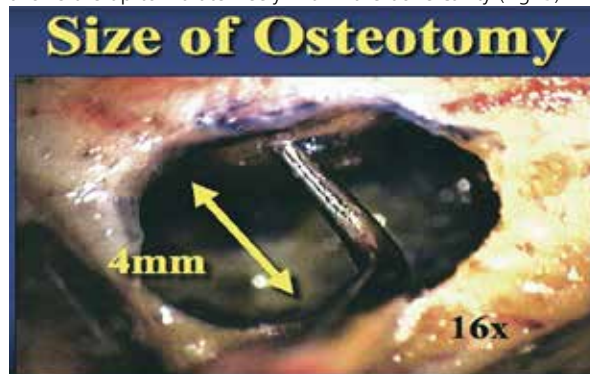

Figure 3. The ideal osteotomy measures 4 mm in diameter allowing a 3 mm ultrasonic tip to move freely within the bone crypt.

Root-End Resection

Root-end resection is a common yet controversial component of endodontic surgery. Historically, many authors have advocated periradicular curettage as the definitive treatment in endodontic surgery without root-end resection. Their rationale for this approach centered primarily around the perceived need to maintain a cemental covering on the root surface and to maintain as much root length as possible for tooth stability [48, 49]. According to Gutmann and Harrison, no studies are available to support either of these concerns. The rationale for periradicular curettage as a terminal procedure to protect root length and to ensure the presence of cementum is, therefore, highly questionable, especially if the source of periradicular irritant is still within the root canal system [49]. Other authors have stated that periradicular curettage per se, without root-end resection and root-end filling, should never be considered a terminal treatment in periradicular surgery unless it is associated with concurrent orthograde root canal treatment [50-52].

There is no complete agreement as to how much of the root has to be resected to satisfy biological principles. Gilheany et al. [53] suggests that at least 2 mm be removed to minimize bacterial leakage from the canals. Our anatomical study of the root apex shows that at least 3 mm of the root-end must be removed to reduce 98% of the apical ramifications and 93% of the lateral canals [6]. As these percentages are very similar at 4 mm from the apex, we recommend root-end amputation of 3 mm, since this leaves on average of 7 to 9 mm of the root, providing sufficient strength and stability.

A root-end amputation of less than 3mm does, most likely, not remove all of the lateral canals and apical ramifications, therefore, posing a risk of reinfection and eventual failure (Fig. 4).




Figure 4. Frequency of apical ramifications and lateral canals. A 3-mm apical resection was needed to eliminate the majority of apical ramifications and lateral canals.

Once a root tip is resected perpendicular to the long axis of the root, proper identification of anatomical details and their management are some of the most important and unique steps in microsurgery and are critical for the success of the treatment [6, 10]. Unfortunately, this surgical procedure cannot be done adequately and precisely with unaided vision or even with loupes. Only the high magnification of a microscope provides the light and the magnification to completely see the anatomical details of the resected root surface [6, 10, 54, 55]. One of the fundamental drawbacks of the traditional root-end resection technique without magnification and microinstruments is the inability to manage and to adequately inspect the anatomical details of the rootsurface. In contrast, with the bright illumination and the range of magnification of the operating microscope from 4x to 25x, the resected root surface can be examined in great detail. Yet, a complete and critical inspection of the resected root surface requires staining of the surface with a contrasting medium, such as methylene blue, that stains the PDL and pulp tissues selectively [10, 54]. With the aid of micromirrors placed at 45 degrees to the surface, the reflected view of the root surface shows every anatomical detail of the canal system, which is critical for a successful surgery(Fig. 5).

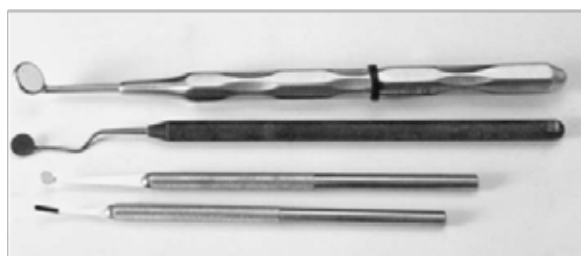

Figure 5. Variety of small front surface micro-mirrors for viewing rootend resection and root-end preparation through the microscope.

As pointed out earlier, the anatomical details of the resected root surface are complex. All types of shapes and forms can be found in the canal system. When cutting the root perpendicular to its long axis, round, oval, horseshoe shaped, S-shaped, two to five small round and oval shaped canals and isthmuses, and so forth, can be observed (Fig. 6).

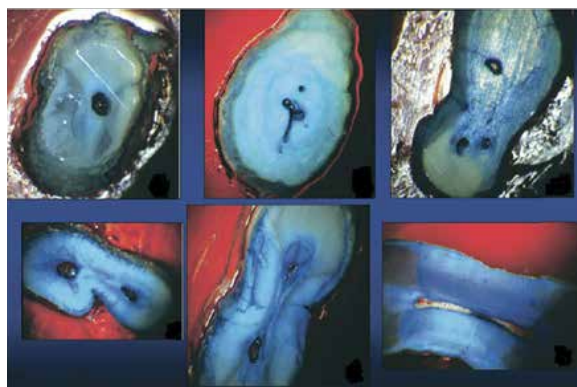


Figure 6. Inspection of resected root surfaces of extracted teeth reveals many different types and shapes of isthmi.

This important step in microsurgery is not considered at all in the traditional surgical technique.

The smoothest surface and the least amount of gutta-percha disturbance were produced by a plain fissure bur in a low-speed handpiece. On the other hand, a multi-purpose bur produced the smoothest and most uniplanar resected root-end surface with the least root shattering compared to a plain fissure bur. The conventional root-end cavity preparation technique using rotary burs in a micro-handpiece poses several problems for the surgeon [6, 10, 22, 56, 57]:

1. Access to the root-end is difficult, especially with limited working space
2. There is a high risk of a perforation of the lingual root-end or cavity preparation, when it does not follow the original canal path
3. There is insufficient depth and retention of the root-end filling material
4. The root-end resection procedure exposes dentinal tubules
5. Necrotic isthmus tissue cannot be removed

These clinical dilemmas were never questioned in the past, rather it was an accepted fact, because the standard tools at that time were too large for the surgical site and the true complexity of the root-end anatomy was not known. The aim of the root-end preparation is to remove the intracanal filling material and irritants and to create a cavity that can be properly filled. The ideal root-end preparation can be defined as a class 1 cavity at least 3mm into root dentine, with walls parallel to and coincident with the anatomic outline of the root canal space [22, 58] (Fig. 7).



Figure 7. Microsurgical root-end preparation with ultrasonic diamond coated tip.

Ultrasonic devices were developed to cut bone atraumatically using ultrasonic vibrations and to provide an alternative to the mechanical and electrical instruments used in conventional oral surgery. Indications for ultrasonic instruments are increasing in oral and maxillofacial surgery, as in other disciplines, such as endodontic surgery. Key features of ultrasonic instruments include their ability to selectively cut bone without damaging adjacent soft tissue, to provide a clear operative field, and to cut without generating heat. Despite the advantages of using ultrasonics, Saunders et al. [55], while experimentally using the ENAC system (smooth stainless steel tips) on extracted teeth reported crack formation in the walls of the cavity, which may increase the chance of apical leakage. However, Layton et al. [56] suggested that the cracks might be a result of the experiment design, because the previous study used demineralized and dehydrated the teeth, which may have predisposed towards crack formation.

Most ultrasonic instruments used in prior studies were smooth, stainless steel tips. Diamond coated ultrasonic surgical instruments have been introduced in recent years in hopes of minimizing dentinal fractures through their ability to abrade dentine more quickly, thus minimizing the time that the instrument is in contact with the root-end [59, 60]. Various studies [61-66] comparing the diamond-coated tips with stainless steel tips have concluded that neither tip produced a significant number of microcracks. However, the diamond coated tips cut much faster, and left a more grooved or rough cavosurface. It is not considered a clinical problem, instead it may be an advantage(Fig. 8).

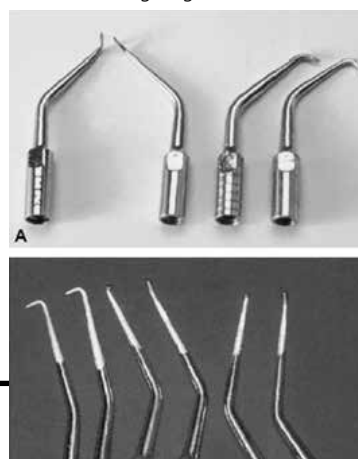


Figure 8. Ultrasonic tips. A, Ultrasonic tips with plain or diamond-coated tips. B, Ultrasonic tips coated with zirconium nitride for faster dentin cutting with less ultrasonic energy.

In summary, ultrasonic tips have fundamentally changed apical surgery. Ultrasonic instruments are still being improved upon, and new, different types of coating would make a difference in cutting efficiency while minimizing microfractures.

The search for the most efficient ultrasonic instruments will continue, and their application together with the microscope and microinstruments will make endodontic microsurgery even more effective (Fig. 9, 10).

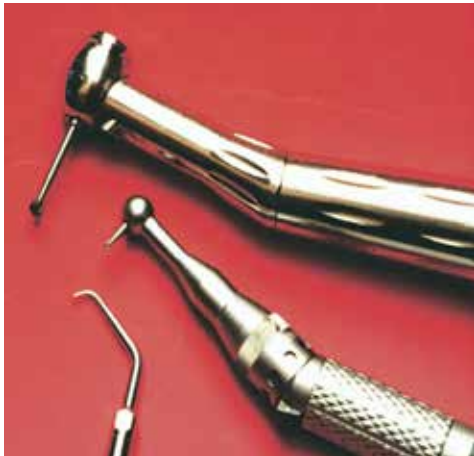

Figure 9. Traditional root-end preparation instruments with burs and modern ultrasonic instrument.




Figure 10. Comparison between bur and ultrasonic root-end preparations. A, Bur preparation shows large cavity prepared obliquely to the canal. B, Ultrasonic preparation shows clean preparation parallel to the canal.

Root-End Filling Materials

The purpose of a root-end filling is to establish a seal between the root canal space and the periapical tissues. According to Gartner and Dorn, a suitable root-end filling material should be: (1) able to prevent leakage of bacteria and their by-products into the periradicular tissues, (2) nontoxic, (3) noncarcinogenic, (4) biocompatible with the host tissues, (5) insoluble in tissue fluids, (6) dimensionally stable, (7) unaffected by moisture during setting, (8) easy to use, and (9) radiopaque [63].

Numerous materials have been suggested for use as root-end fillings, including gutta-percha, amalgam, Cavit, intermediate restorative material (IRM), Super EBA, glass ionomers, composite resins, carboxylate cements, zinc phosphate cements, zinc oxide-eugenol cements, and mineral trioxide aggregate (MTA). The suitability of these various materials has been tested by evaluating their microleakage (dye, radioisotope, bacterial penetration, fluid filtration), marginal adaptation, and cytotoxicity and clinically testing them in experimental animals and humans [67].

There are several root-end filling materials now used in conjunction with apical surgery. Amalgam has been and still is to some extent a widely used material. However, in the past decade amalgam has slowly given way to ZOE containing materials, such as IRM and SuperEBA as a favorite root-end filling materials. Numerous studies show that these ZOE containing materials are superior to amalgam in terms of sealability and biocompatibility [68-71]. More recently, mineral trioxide aggregate (MTA) has been suggested as having many of the properties of the ideal root-end filling material [72] (Fig. 11).

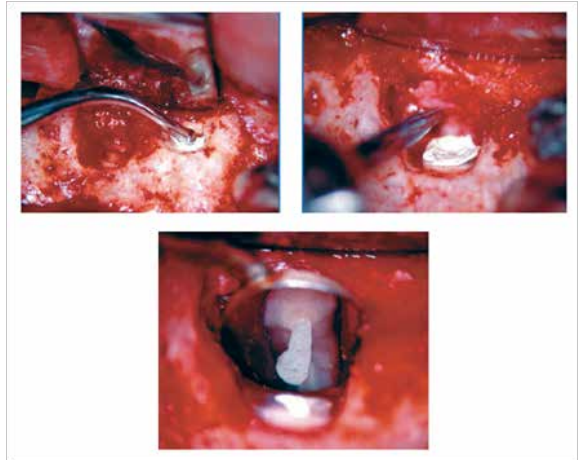


Figure 11. The integrity of the retrofilling is examined at magnification.

The main ingredients of MTA are tricalcium silicate, tricalcium aluminate, and tricalcium oxide. Because of its superior sealing ability and biocompatibility over conventional filling materials, MTA is gaining popularity among endodontists [73-74]. In comparison to amalgam and SuperEBA as root-end filling materials, MTA consistently resulted in regeneration of periapical tissues including periodontal ligament and cementum [74]. However, the use of MTA alone does not guarantee clinical success. MTA cannot overcome deficiencies in techniques that are inherent in the traditional apical preparation.

Clinical studies show that healing of cases sealed with MTA is much better, but not significantly different than IRM, provided that modern microsurgical or, at least, ultrasonic preparation techniques were employed [23]. Good surgical techniques and protocol are as important for better results as are the materials. Given the development of contemporary microsurgical techniques and tissue inductive root-end filling materials, the continued use of traditional surgical techniques with amalgam fillings has been questioned [22, 23].

Conclusion

Surgery is a very important aspect of endodontics. Endodontic surgery has now evolved into endodontic microsurgery. By using ultimate equipment, instruments and materials that match biological concepts with clinical practice, we believe that microsurgical approaches produce predictable outcomes in the healing of lesions of endodontic origin. We must consistently learn and teach microsurgery to all endodontists so that they can treat nonsurgical as well as surgical endodontic cases with equal ease and skill. With a high percentage of successful treatment outcomes of conventional endodontics together with high success of surgical endodontics almost all teeth with endodontic lesions can be successfully treated.

We believe that endodontic microsurgery with MTA is a predictable procedure to save teeth. We must teach the future generation of graduate students, and also train our colleagues to incorporate these techniques into everyday clinical practice.

The preservation of our natural teeth must be our ultimate goal. To accomplish this goal, endodontists have developed new techniques, materials and instruments. Enhanced illumina-

nation and magnification have greatly improved what practitioners can perform. Developments in root-end filling materials have increased both quality and biocompatibility of apical seals. Together, these advances have significantly improved the state of the art and science of endodontic surgery, giving a second chance to a tooth that was considered for extraction.

REFERENCES

- Torabinejad M, Corr R, Handysides R, Shabahang S. Outcomes of Nonsurgical Retreatment and Endodontic Surgery: A Systematic Review. *J Endod*. 2009; 35(7): 930-937.
- Song M, Kim SG, Lee SJ, Kim B, Kim E. Prognostic Factors of Clinical Outcomes in Endodontic Microsurgery: A Prospective Study. *J Endod*. 2013; 39(12): 1491-1497.
- Tsesis I, Rosen E, Taschieri S, Strauss Y, Ceresoli V, Del Fabbro M. Outcomes of Surgical Endodontic Treatment Performed by a Modern Technique: An Updated Meta-analysis of the Literature. *J Endod*. 2013; 39(3): 332-339.
- Lieblisch SE. Endodontic Surgery. *Dent Clin N Am*. 2012; 56(1): 121-132.
- Briggs PF, Scott BJ. Evidence-based dentistry: endodontic failure - how should it be managed? *Br Dent J*. 1997; 183: 159-164.
- Kim S, Pecora G, Rubinstein R. Comparison of traditional and microsurgery in Endodontics (Color atlas of microsurgery in endodontics. Philadelphia: WB Saunders, 2001, 5-11).
- Kim S. Principles of endodontic microsurgery. *Dent Clin North Am*. 1997; 41: 481-497.
- Rubinstein RA, Kim S. Short-term observation of the results of endodontic surgery with the use of a surgical operation microscope and Super-EBA as root-end filling material. *J Endod*. 1999; 25: 43-48.
- Carr GB. Microscope in endodontics. *J Calif Dent Assoc*. 1992; 20: 55-61.
- Carr GB. Surgical endodontics (Cohen S, Burns R, eds. Pathways of the pulp, 6th ed. St Louis: Mosby, 1994, 531).
- Song M, Jung IY, Lee SJ, Lee CY, Kim E. Prognostic factors for clinical outcomes in endodontic microsurgery: A retrospective study. *J Endod*. 2011; 37(7): 927-933.
- Friedman S. Retreatment of failures. (Principles and practice of endodontics. 2nd ed. Philadelphia: WB Saunders, 1996.)
- Bergenholtz G, Lekholm U, Milthron R. Retreatment of endodontic fillings. *Scand J Dent Res*. 1979; 87: 217-224.
- Allen RK, Newton CW, Brown CE. A statistical analysis of surgical and nonsurgical retreatment cases. *J Endod*. 1989; 15: 261-266.
- Van Nieuwenhuysen JP, Aouar M, D'Hoore V. Retreatment or radiographic monitoring in endodontics. *Int Endod J*. 1994; 27: 75-81.
- Hepworth MJ, Friedman S. Treatment outcome of surgical and nonsurgical management of endodontic failures. *J Can Dent Assoc*. 1997; 63: 364-371.
- Kim E, Song JS, Jung IY, Lee SJ, Kim S. Prospective clinical study evaluating endodontic microsurgery outcomes for cases with lesions of endodontic origin compared with cases with lesions of combined periodontal-endodontic origin. *J Endod*. 2008; 34(5): 546-551.
- Taschieri T, Weinstein G, Rosano M, Del Fabbro M. Morphological features of the maxillary incisors root and relationship with neighbouring anatomical structures: possible implications in endodontic surgery. *Int J Oral Maxillofac Surg*. 2012; 41(5): 616-623.
- Luebke RG, Glick DH, Ingle JI. Indications and contraindications for endodontic surgery. *Oral Surg*. 1964; 18: 97-113.
- Pecora G, Andreana S. Use of dental operating microscope in endodontic surgery. *Oral Surg Oral Med Oral Pathol*. 1993; 75: 751-758.
- Kim S, Kratchman S. Modern Endodontic Surgery Concepts and Practice: A Review. *J Endod*. 2006; 32: 601-623.
- Pecora GE, Pecora CN. A New Dimension in Endo Surgery. *Micro Endo Surgery J Conserv Dent*. 2015; 18: 7-14.
- Chong BS, Pitt Ford TR, Hudson MB. A prospective clinical study of Mineral Trioxide Aggregate and IRM when used as root-end filling materials in endodontic surgery. *Int Endod J*. 2003; 36: 520-526.
- Testori T, Capelli M, Milani S, Weinstein RL. Success and failure in periradicular surgery: a longitudinal retrospective analysis. *Oral Surg Oral Med Oral Pathol Oral Radiol Endod*. 1999; 87: 493-498.
- Wang N, Knight K, Dao T, Friedman S. Treatment outcome in endodontics: the Toronto Study. Phases I and II: apical surgery. *J Endod*. 2004; 30: 751-761.
- Buckley JA, Ciancio SG, McMullen JA. Efficacy of epinephrine concentration on local anesthesia during periodontal surgery. *J Periodontol*. 1984; 55: 653-657.
- Guttmann JL. Parameters of achieving quality anesthesia and hemostasis in surgical endodontics. *Anesth Pain Control Dent*. 1993; 2: 223-226.
- Holroyd SV, Watts DT, Welch JI. The use of epinephrine in local anesthetics for dental patients with cardiovascular disease: a review of the literature. *J Oral Surg Anesth Hosp Dent Serv*. 1960; 18: 492-503.
- Malamed S. Handbook of local anesthesia (1st ed. St. Louis: C.V. Mosby Co., 1980).
- Dionne RA, Goldstein DS, Wirdzek PR. Effects of diazepam premedication and epinephrine-containing local anesthetic on cardiovascular and plasma catecholamine responses to oral surgery. *Anesth Analg*. 1984; 63: 640-646.
- Premerspoon DE, Guttmann JL. Hemostasis in periradicular surgery. *Int Endod J*. 1996; 29: 135-149.
- Kim S, Rethnam S. Hemostasis in endodontic microsurgery. *Dent Clin North Am*. 1997; 41: 499-511.
- Vy CH, Baumgartner JC, Marshall JG. Cardiovascular effects and efficacy of a hemostatic agent in periradicular surgery. *J Endod*. 2004; 30: 379-383.
- Song M, Shin SJ, Kim E. Outcomes of Endodontic Micro-surgery: A Prospective Clinical Study. *J Endod*. 2011; 37(3): 316-320.
- Kramper BJ, Kaminski EJ, Osetek EM, Heuer MA. A comparative study of the wound healing of three types of flap design used in periapical surgery. *J Endod*. 1984; 10: 17-25.
- Velvart P. Papilla base incision: a new approach to recession-free healing of the interdental papilla after endodontic surgery. *Int Endod J*. 2002; 35: 453-480.
- Guttmann JL, Harrison JW. Surgical Endodontics (Blackwell Scientific Publications, Boston, 1991).
- Lubow RM, Wayman BE, Cooley RL. Endodontic flap design: analysis and recommendations for current usage. *Oral Surg*. 1984; 58: 207-212.
- Velvart P, Ebner-Zimmermann U, Ebner JP. Comparison of long-term papilla healing following sulcular full thickness flap and papilla base flap in endodontic surgery. *Int Endod J*. 2004; 37: 687-693.
- Guttmann JL. Principles of endodontic surgery for the general practitioner. *Dent Clin North Am*. 1984; 28: 895-908.
- Lui JN, Khin MM, Krishnaswamy G, Chen NN. Prognostic Factors Relating to the Outcome of Endodontic Microsurgery. *J Endod*. 2014; 40(8): 1071-1076.
- Boyne P, Lyon H, Miller C. The effects of osseous implant materials on regeneration of alveolar cortex. *Oral Surg Oral Med Oral Pathol*. 1961; 369-378.
- Hjorting-Hansen E. Studies on implantation of anorganic bone in cystic jaw lesions, doctoral thesis, Munksgaard, Copenhagen, 1970.
- Hjorting-Hansen E, Andreasen JO. Incomplete bone healing of experimental cavities in dog mandibles. *Br J Oral Surg*. 1971; 9: 33-40.
- Song M, Kim SG, Shin SJ, Kim HC, Kim E. The influence of bone tissue deficiency on the outcome of endodontic microsurgery: a prospective study. *J Endod*. 2013; 39(11): 1341-1345.
- Pearson HH. Curette or resect? *J Can Dent Assoc*. 1949; 14: 508.
- Wakely JW, Simon WJ. Apical curettage or apicoectomy? *Dent Assist*. 1977; 46: 29-33.
- Guttmann JL, Pitt Ford TR. Management of the resected root end: a clinical review. *Int Endod J*. 1993; 26: 273-283.
- Guttmann JL, Harrison JW. Posterior endodontic surgery: anatomical considerations and clinical techniques. *Int Endod J*. 1985; 18: 8-34.
- Gilheary PA, Figdor D, Tyas MJ. Apical dentin permeability and microleakage associated with root end resection and retrograde filling. *J Endod*. 1994; 20: 22-26.
- Setzler FC, Kohli MR, Shah SB, Karabucak B, Kim S. Outcome of endodontic surgery: a meta-analysis of the literature—part 2: Comparison of endodontic microsurgical techniques with and without the use of higher magnification. *J Endod*. 2012; 38(1): 1-10.
- Fabbro MD, Taschieri S. Endodontic therapy using magnification devices: A systematic review. *J Dent*. 2010; 38(4): 269-275.
- Carr GB. Ultrasonic root end preparation. *Dent Clin North Am*. 1997; 41: 541-544.
- Von Arx T, Kurt B. Root-end cavity preparation after apicoectomy using a new type of sonic and diamond-surfaced retropip: a 1-year follow-up study. *J Oral Maxillofac Surg*. 1999; 57: 656-661.
- Saunders WP, Saunders M, Guttmann JL. Ultrasonic root end preparation: part 2—microleakage of EBA root end fillings. *Int Endod J*. 1994; 27: 325-329.
- Layton CA, Marshall G, Morgan L, Baumgartner C. Evaluation of cracks associated with ultrasonic root end preparations. *J Endod*. 1996; 22: 157-160.
- Navarre SW, Steiman R. Root-end fracture during retropreparation: a comparison between zirconium nitride-coated and stainless steel microsurgical ultrasonic instruments. *J Endod*. 2002; 28: 330-332.
- Abela F, de Ribot J, Doria G, Duran-Sindreu F, Roig M. Applications of piezoelectric surgery in endodontic surgery: a literature review. *J Endod*. 2014; 40(3): 325-332.
- Setzler FC, Shah SB, Kohli MR, Karabucak B, Kim S. Outcome of endodontic surgery: a meta-analysis of the literature—part 1: Comparison of traditional root-end surgery and endodontic microsurgery. *J Endod*. 2010; 36(11): 1757-1765.
- Peters CI, Peters OA, Barbakow F. An in vitro study comparing root-end cavities prepared by diamond coated and stainless steel ultrasonic retropips. *Int Endod J*. 2001; 34: 142-148.
- Brent PD, Morgan LA, Marshall JG, Baumgartner JC. Evaluation of diamond-coated ultrasonic instruments for the root-end preparation. *J Endod*. 1999; 25: 672-675.
- Zuolo ML, Ferreira MO, Guttmann JL. Prognosis in periradicular surgery: a clinical prospective study. *Int Endod J*. 2000; 33: 91-98.
- Gartner AH, Dorn SO. Advances in endodontic surgery. *Dent Clin North Am*. 1992; 36: 357-378.
- Jou YT, Pertl C. Is there a best retrograde filling material. *Dent Clin North Am*. 1997; 41: 555-561.
- Szeremeta-Brower TL, VanCura JE, Zaki AE. A comparison of the sealing properties of different retrograde techniques: an autoradiographic study. *Oral Surg Oral Med Oral Pathol*. 1985; 59: 82-87.
- Bondra DL, Hartwell GR, MacPherson MG, Portell FR. Leakage in vitro with IRM, high copper amalgam, and EBA cement as retrofilling materials. *J Endod*. 1989; 15: 157-160.
- Pitt Ford TR, Andreasen JO, Dorn SO, Kariyawasam SP. Effect of IRM root-end fillings on healing after replantation. *J Endod*. 1994; 20: 381-385.
- Pitt Ford TR, Andreasen JO, Dorn SO, Kariyawasam SP. Effect of Super EBA as a root-end filling on healing after replantation. *J Endod*. 1995; 21: 13-15.
- Torabinejad M, Pitt Ford TR, Abedi HR, et al. Tissue reaction to implanted root-end filling materials. *J Endod*. 1998; 24: 468-471.
- Torabinejad M, Hong CU, Pitt Ford TR, Kettering JD. Cytotoxicity of four root end filling materials. *J Endod*. 1995; 21: 489-492.
- Torabinejad M, Hong CU, Pitt Ford TR, Kariyawasam SP. Tissue reaction to implanted super-EBA and mineral trioxide aggregate in the mandible of guinea pigs: a preliminary report. *J Endod*. 1995; 21: 569-571.
- Torabinejad M, Rastegar AF, Kettering JD, Pitt Ford TR. Bacterial leakage of mineral trioxide aggregate as a root-end filling material. *J Endod*. 1995; 21: 109-112.
- Torabinejad M, Chivian N. Clinical applications of mineral trioxide aggregate. *J Endod*. 1999; 25: 197-205.
- Baek SH, Plenk H Jr, Kim S. Periapical tissue responses and cementum regeneration with amalgam, SuperEBA, and MTA as root-end filling materials. *J Endod*. 2005; 31: 444-449.