



Metastatic deposits of Acute Lymphoblastic Leukemia in the Breast -A case report.

Dr.B.V.Rama Reddy	Associate Professor, Department of Pathology, Rangaraya Medical College, Kakinada, Andhra Pradesh.
Dr.P.Sree devi	Assistant Professor.Department of Pathology, Rangaraya Medical College,Kakinada, Andhra Pradesh.
Dr.R.Rajeswari	Assistant Professor.Department of Pathology, Rangaraya Medical College,Kakinada, Andhra Pradesh.
Dr.V.Rajani	Assistant Professor.Department of Pathology, Rangaraya Medical College,Kakinada, Andhra Pradesh.

ABSTRACT

Leukemic infiltration (Extramedullary) of the breast in acute lymphoblastic leukemia is rare.We report a case of acute lymphoblastic leukemia present as breast lump diagnosed on fine needle aspiration cytology.A 16yr old girl presented with lump in the left breast of two months duration.Patient was on treatment for acute lymphoblastic leukemia until 6 months back.Aspiration of the breast lump showed infiltration of lymphoblasts.

KEYWORDS

Fine needle aspiration,Acute lymphoblastic leukemia, Infiltration.

Introduction :

Infiltration by leukemic cells of the breast is rare or present as extramedullary manifestation⁽¹⁾.Breast involvement was diagnosed on fine needle aspiration.The case is reported because of its rarity.

Case report :

A 16 yr old girl came to surgical outpatient department with the history of a painless lump in the left breast of two months duration. Previously she was a patient of acute lymphoblastic leukemia (L2 type) and took treatment for one year. The patient is positive for Abelson gene BCR-ABL in 96% of cells. The patient taken chemotherapy by UK ALL XII protocol. The patient responded well and on remission for the last six months.

On examination, there was 2cm,painless,mobile,firm lump in the left breast .No lymphnodal involvement in the axillary region. Total white blood cell count is 9000 cells/cu.m($9.0 \times 10^3/\text{mm}^3$).Hemoglobin percentage is 12 gms% and platelet count is 2lakhs/ mm^3 ($200 \times 10^3/\text{UL}$).Mammography showed diffuse nodular infiltration (Fig 1).Initially diagnosed as fibroadenoma clinically .Fine needle aspiration was done and stained with May- Grunewald Giemsa stain .

On microscopic examination,highly cellular smears,showing diffuse infiltration by roundcells with scanty cytoplasm and less prominent nucleoli – lymphoblasts. Abundant mitotic figures were present (Fig 2& 3). The cytological findings were consistent with those of leukemic infiltrates of acute lymphoblastic leukemia.

Discussion :

Infiltration by leukemic cells of the breast is very rare. It may occur as an isolated tumor or as an extra medullary manifestation in systemic disease ^(2,3). Rarely there will be primary manifestation of acute lymphoblastic leukemia ⁽³⁾. Involvement of the breast in extra medullary relapse is infrequent ⁽⁴⁾. Malignancy of the breast is uncommon in children and adolescent

females⁽⁵⁾.Patients present with a circumscribed and rapidly growing mass. It may be bilateral or multi nodular looking like a fibroadenoma ⁽³⁾.

The mammographic findings are variable-normal or an enlarged breast with diffusely coarse breast parenchyma.

Various aspirates exhibit dispersed monomorphic blastic cells from small and medium to large,having a high N:C ratio. Inconspicuous nucleoli with scanty cytoplasm. Mitotic figures maybe present and variable in number^(6,7). 90% are T- cell neoplasms and remaining 10% are B-cell type. Acute lymphoblastic leukemia shows Td T positivity⁽⁸⁾.

Differential diagnosis:

Other small round cell tumors such as Non Hodgkin's Lymphoma,rhabdomyosarcoma, granulocytic sarcoma,lobular carcinoma,neuroblastoma and endocrine carcinoma⁽⁶⁾ will be considered .

In this case,cellular aspirate of small to medium size round cells, with immature chromatin,inconspicuous nucleoli and scanty cytoplasm. The case is positive for B-cell CALLA and BCR-ABL gene.

Conclusion :

Leukemic cell infiltration of the breast in acute lymphoblastic leukemia is rare.It should be considered in the differential diagnosis of breast lumps of sudden onset. Fine needle aspiration gives an easy and early diagnosis. With help of flowcytometry and immunocytochemistry an accurate diagnosis can be made by avoiding an excision biopsy and allowing early treatment.

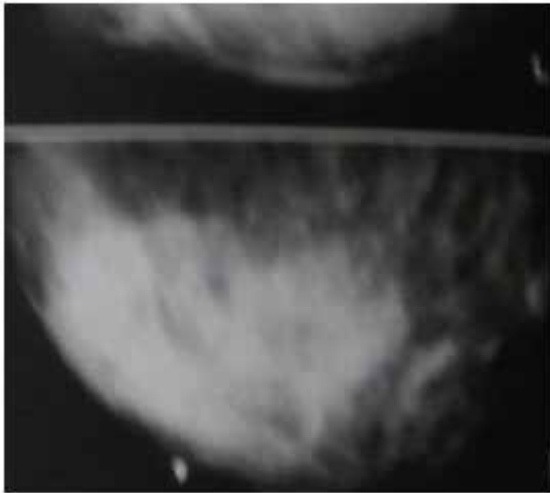


Fig :1 Mammography showing diffuse dense area of left breast

Fig 2: Smear showing abundant round cells with scanty cytoplasm amidst benign ductal epithelial cells (MGG x400)

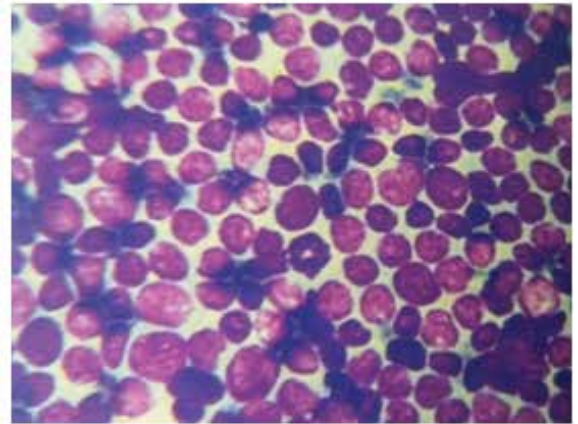
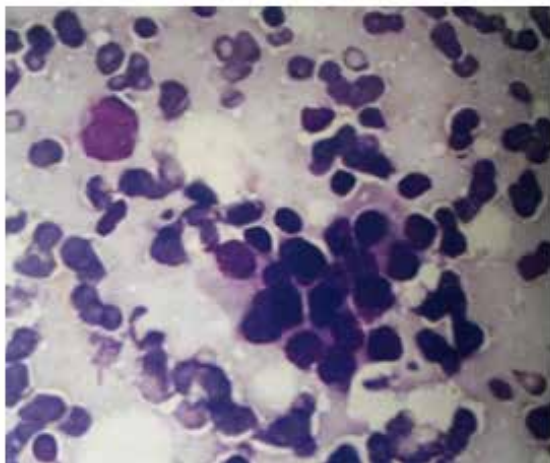


Fig 3: Smear showing plenty of lymphoblasts with few mitotic figures (MGG x400)



REFERENCES

1. Karbasian-Esfahani M,Wiernik PH,Yeddu M , Abebe L –Leukemic infiltration of the breast in acute lymphoblastic leukemia. *Hematology* 2008;13:101-106. | 2. Bayrak IK , Yalin T, Ozmen Z , Aksoz T, Doughanji R –Acute lymphoblastic leukemia presented as multiple breast masses. *Korean J radiol* 2009; 10: 508-510. | 3. Mandal S ,Jains,Khurana N-Breast lump as an initial manifestation in Acute lymphoblastic leukemia ; an unusual presentation.A case report . *Hematology* 2007;12: 45-47. | 4. Thanka J,Krishnarathinam K ,Rajendiran S. Extra medullary relapse of acute lymphoblastic leukemia in breast.A rare presentation *Indian J pathol microbial* 2010;53:155-156. | 5. West KW , Rescorla FJ,Scherer LR 3rd,Grosfeld JL- Diagnosis and treatment of symptomatic | breast masses in the pediatric population. *J Pediatr Surg* 1995 ; 30 :185-187. | 6. Driss M , Salem A , Mrad K, Abbas I,Sassis, Ben Romdhane K –Acute lymphoblastic leukemia relapse in the breast.Fine needle aspiration cytology diagnosis of a rare presentation. *Acta- cytol* 2010;54:361-364. | 7. Vigliar E, Cozzolino I , Fernandez LV , Di pietto L, Riccardi A ,Picardi M ,etal. Fine needle cytology and flow cytometry assessment of reactive and lymphoproliferative processes of the breast,*Actacytol* 2012; 56:130-138. | 8. Brunnig RD,Borowitz M ,Matutes E, Head D- Precursor B Lymphoblastic leukemia. WHO classification of tumors : pathology& genetics of tumors of hematopoietic & lymphoid tissues 2001 P.111-114.