



## Spinal Tuberculosis

<b>Yagnesh N Bakrania</b>	Resident Doctor, Dept. of orthopaedics, B.J. Medical college, Civil-Hospital, Asarwa, Ahmedabad
<b>Gaurav H. Mehta</b>	Resident Doctor, Dept. of orthopaedics, B.J. Medical college, Civil-Hospital, Asarwa, Ahmedabad
<b>Parthiv J. Raval</b>	Resident Doctor, Dept. of orthopaedics, B.J. Medical college, Civil-Hospital, Asarwa, Ahmedabad
<b>Ashish D. Yadav</b>	Resident Doctor, Dept. of orthopaedics, B.J. Medical college, Civil-Hospital, Asarwa, Ahmedabad
<b>Mohit M. Patel</b>	Resident Doctor, Dept. of orthopaedics, B.J. Medical college, Civil-Hospital, Asarwa, Ahmedabad
<b>Harshad A. Patel</b>	Resident Doctor, Dept. of orthopaedics, B.J. Medical college, Civil-Hospital, Asarwa, Ahmedabad
<b>Akash J. Shah</b>	Resident Doctor, Dept. of orthopaedics, B.J. Medical college, Civil-Hospital, Asarwa, Ahmedabad

### ABSTRACT

15 year old male with k/c/o dorsal kochs spine came to Civil hospital Amdavad/ B.J.M.C. with acute onset paraplegia and on further evaluation clinically and radiologically dorsal kochs spine was confirmed. Patient was operated with removal of caseous material and immediate post op there was improvement in neurology. patient was given AKT and on further follow up there was significant improvement in neurology and bowel/ bladder control was achieved.

### KEYWORDS

Dorsal Kochs, Decompression, Post op improvement

### Introduction

Spinal tuberculosis is a frequently encountered extrapulmonary form of the disease. In developed nations, most cases of spinal tuberculosis are seen primarily in immigrants from endemic countries. Because the epidemic of human immunodeficiency virus (HIV) infection caused resurgence in all forms of tuberculosis, increased awareness about spinal tuberculosis is necessary. Despite its common occurrence and the high frequency of long-term morbidity, there are no straightforward guidelines for the diagnosis and treatment of spinal tuberculosis. Early diagnosis and prompt treatment is necessary to prevent permanent neurological disability and to minimize spinal deformity.<sup>1,2</sup>

Spinal tuberculosis is one of the oldest diseases known to mankind and has been found in Egyptian mummies dating back to 3400 BC.<sup>3</sup> The disease is popularly known as Pott's spine. The name traces back its origin from the description of tuberculous infection of the spine by Sir Percival Pott in his monograph in 1779.<sup>4</sup> The majority of his patients were infants and young children. The classic destruction of the disk space and the adjacent vertebral bodies, destruction of other spinal elements, severe and progressive kyphosis subsequently became known as Pott's disease. Currently, the term 'Pott's disease/Pott's spine' describes tuberculous infection of the spine and the term 'Pott's paraplegia' describes paraplegia resulting from tuberculosis of the spine.

This review focuses on the various aspects of spinal tuberculosis. An extensive review of the literature published in English

was carried out using the PubMed and Google Scholar databases. The search terms included tuberculosis, skeletal tuberculosis, spinal tuberculosis, Pott's disease, Pott's paraplegia, and central nervous system tuberculosis.

### Case report

Bharat Singh M rathod, 15 years/M r/o Shivgadh, shirohi, Rajasthan, k/c/o dorsal kochs since 1 year, on AKT since 5 months, came to Civil hospital Ahmedabad with acute onset paraplegia and bowel bladder involvement.

### PHYSICAL EXAMINATION

#### 1. GPE:

A young aged male, lying in bed

His vitals are;

- Pulse: 85/min
- B.P: 130/80 mm of Hg
- Oxygen Sat: 96%
- Temp: Afebrile

Rest of GPE unremarkable

### NEUROLOGICAL EXAMINATION

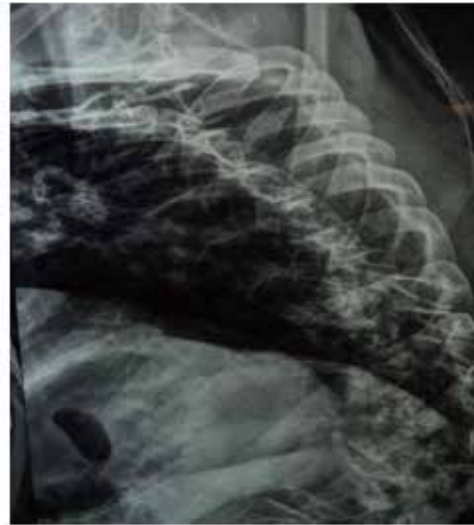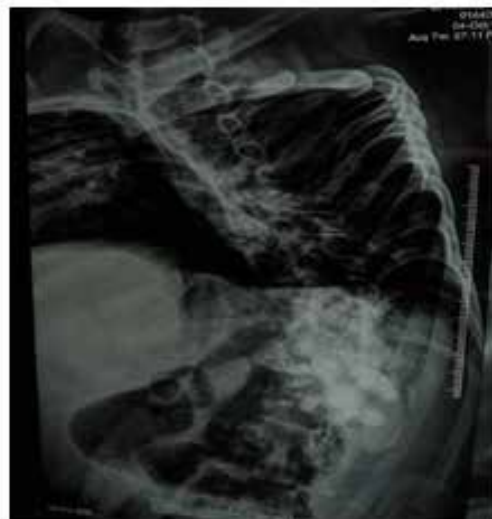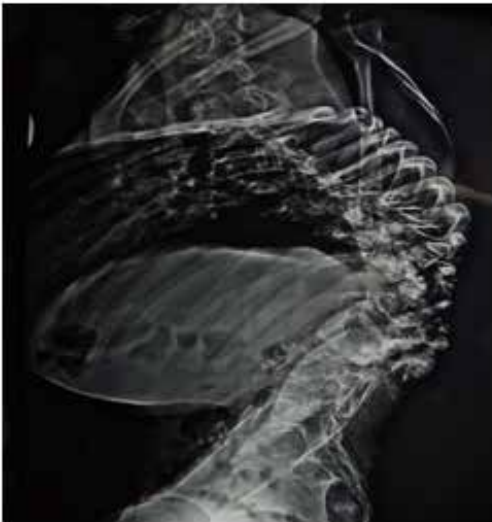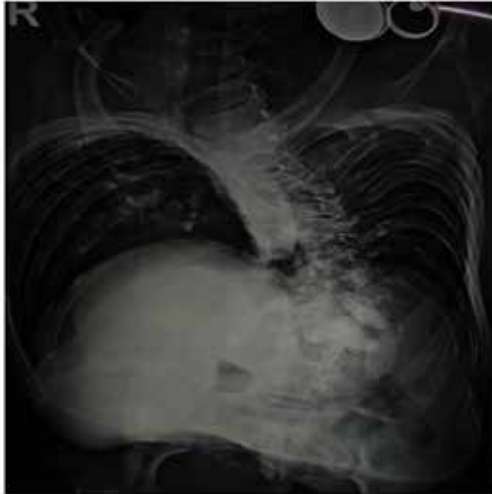- Kyphosis and scoliosis present.
- Tenderness in the Dorsal spine (D5, D6)
- Sensory system normal
- Motor system Paraplegia
- Reflexes Absent

- Plantars Absent
- Bowel/Bladder Involved
- FRANKEL'S Grade-B

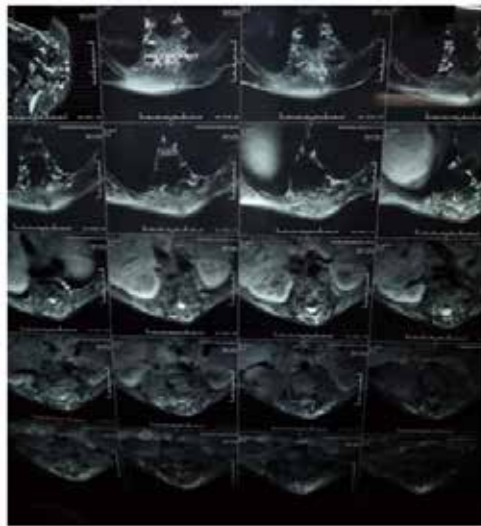
Investigations on the day of admission

- Blood CP
- ESR
- LFTs
- X-ray Dorso-Lumbar Spine

**Pre op x-ray**

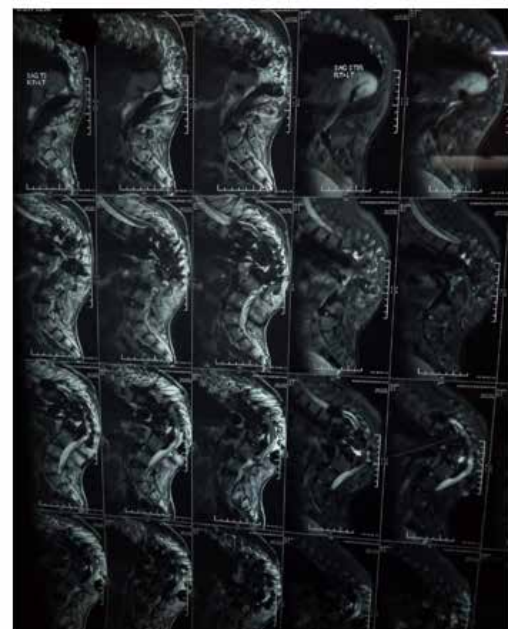

Pre contrast MRI axial

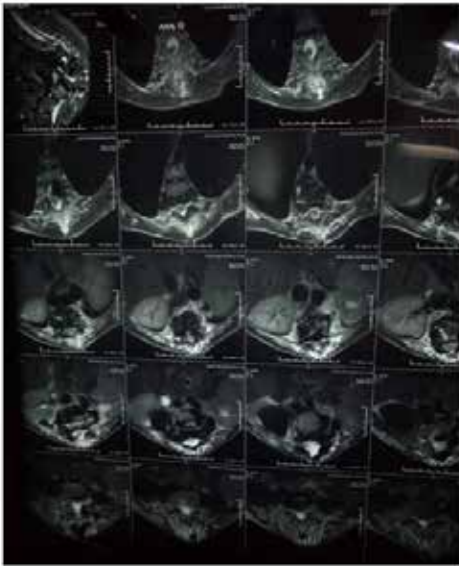


Pre op MRI

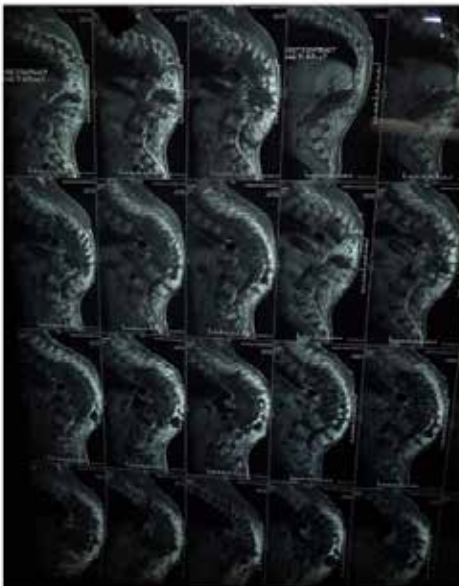
T2 Sagittal



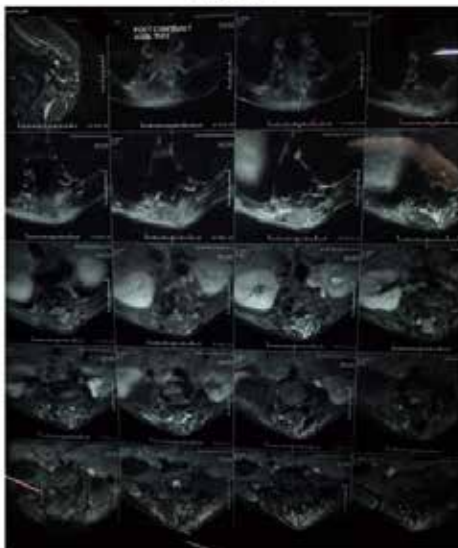
Pre op T2 Axial



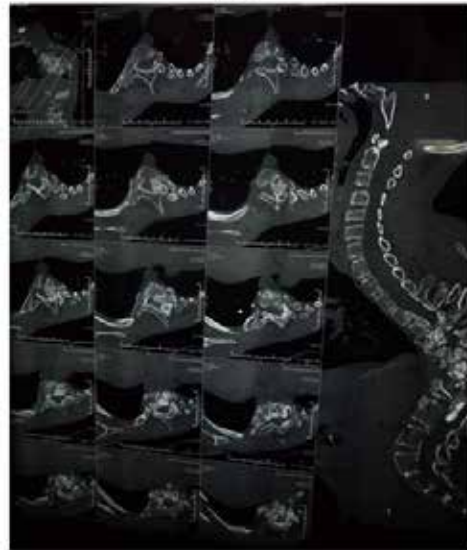Pre op T1W



Post operation MRI



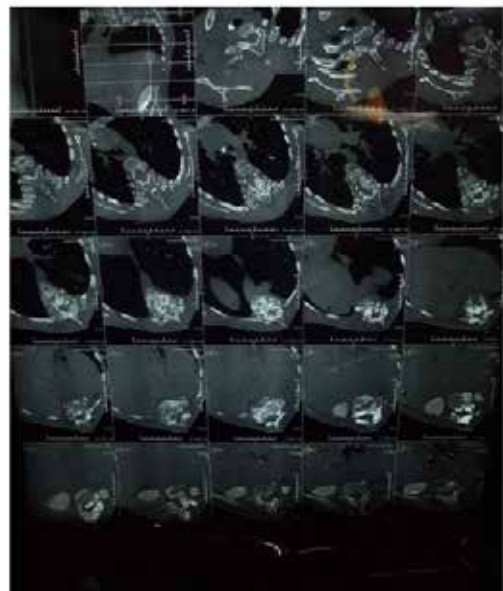CT scan



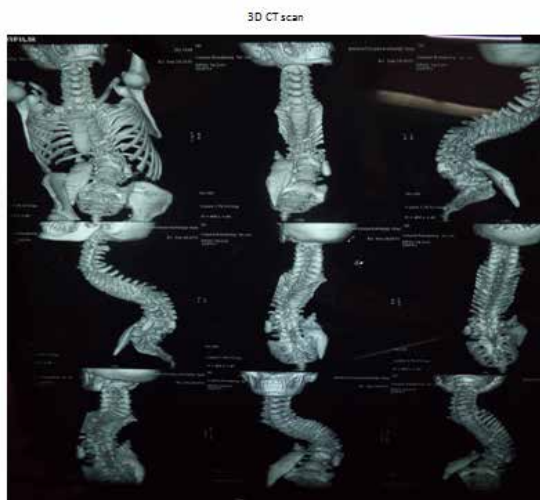
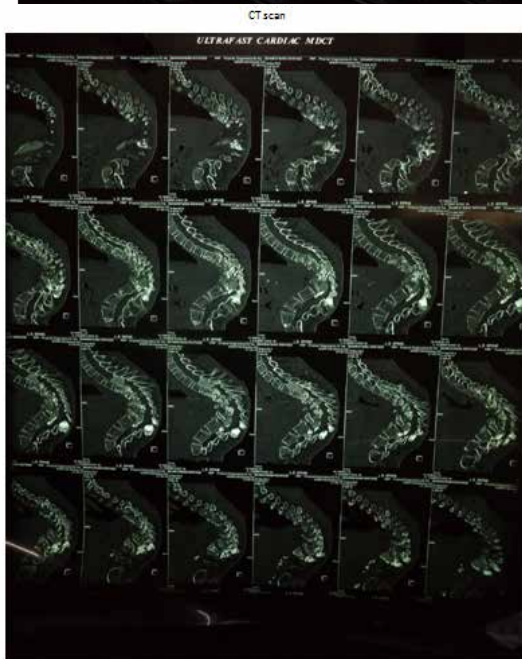
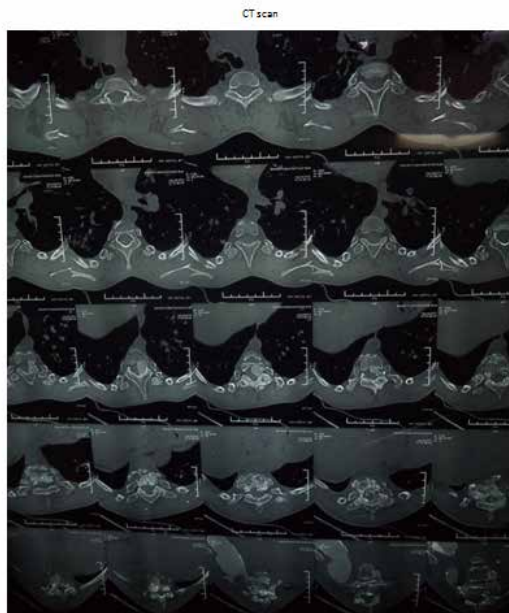
CT scan



CT scan







- Considering acute onset weakness it was decided to operate the patient
- Patient was operated from posterolateral approach
- All the caseous material was removed and decompression was done
- So clinically and radiologically the provisional diagnosis of Spinal Tuberculosis was made and patient was operated for decompression by posterolateral approach.
- All the caseous material removed and adequate decompression was achieved and sample sent for histopathological examination.
- Final Diagnosis was confirmed by Histopathological examination.
- Patient was again started for AKT cat-2 and patient was discharged after thorough rehabilitation(all the physiotherapy, spine care, bowel bladder care, DLSO brace). On Follow up there was improvement of power and bowel/bladder control.
- After 5 months patient regained full power of both the lower limbs and bowel/bladder function.

### Discussion

According to WHO(2010), about one third of the world's population is infected by Mycobacterium TB, and 9 million individuals develop TB each year. One third of total TB population is in South-East Asia. Three percent are suffering from skeletal TB. Vertebral TB is the most common form of skeletal TB and accounts for 50% of all cases of skeletal TB. The mortality rate is 27/100,000 of the population. Neurological complications are the most crippling complications of spinal TB (Incidence : 10 to 43%). Spinal tuberculosis is usually a secondary infection from a primary site in the lung or genitourinary system. Spread to the spine is hematogenous in most instances. Delayed hypersensitivity immune reaction. The basic lesion is a combination of osteomyelitis and arthritis.... Affects the anterior part of vertebra...

### On X – ray

- Typical tubercular spondylitic features in long standing paraspinal abscesses
- produce concave erosions around the anterior margins of the vertebral bodies producing a scalloped appearance called the Aneurysmal phenomenon.
- fusiform paraspinal soft tissue shadow with calcification in few .
- Skip lesions as involvement of non contiguous vertebrae (7 – 10 % cases).
- **DEFORMITIES:**
  1. Anterior wedging
  2. Gibbous deformity.
  3. Vertebra plana = single collapsed vertebra .

Measures that are helpful in minimizing the increase in kyphosis include recumbency in the early active stage of the disease and prolonged protection of the spine with suitable braces in later stages. Most experts believe that kyphosis greater than 30° is likely to generate back pain and may deteriorate further, and hence, requires surgical correction. Aspiration or surgical drainage was carried out for some patients with large cold abscesses because it was thought to improve the patient's general condition, and prevent rapid progression of the abscess along the spine. This has been shown to be ineffective, however, and surgical drainage of a cold abscess alone is no longer recommended. Abscesses usually resolve with medical therapy as antituberculosis drugs penetrate very well

Prognosis is generally good in patients without neurologic deficit and deformity. Various studies show that 82–95% cases respond to medical treatment alone in the form of pain relief, improving neurologic deficit, and correction of spinal deformity. 23,108 In a recently published study among patients with neurologic deficit, significant recovery occurred in 92%, with 74% improving from nonambulatory to ambulatory status. This study included 82 patients; 52% of patients presented in a nonambulatory state, 21% had mild neurologic deficits, and 27% had intact neurologic function. 110 In a study from an endemic country, the majority (79 patients, 61%) of

patients had severe motor and sensory impairment. Imaging revealed multiple vertebral involvements in 90 patients (80%). All patients were managed using antituberculous treatment; however, 33 patients required operative treatment as well. Marked clinical improvement was seen in 91 patients (70%) within 6 months of treatment.

**Conclusion**

The prognosis for spinal tuberculosis is improved by early diagnosis and rapid intervention. A high degree of clinical suspicion is required if patients present with chronic back pain, even in the absence of neurological symptoms and signs. Medical treatment is generally effective. Surgical intervention is necessary in advanced cases with marked bony involvement, abscess formation, or paraplegia. Spinal tuberculosis affects young people, so efforts should be made for its effective prevention. Controlling the spread of tuberculosis is only way available to prevent spinal tuberculosis.