



## Alpha-foetoprotein (AFP)-producing ovarian tumour in an elderly woman: case report of a primitive endodermal tumour.

<b>Giuseppe Loverro</b>	Department of Obstetrics and Gynecology, University, Medical School, Bari, Italy
<b>Leonardo Resta</b>	Department of Emergency and Organ Transplantation, Section of Pathology, University, Medical School, Bari, Italy
<b>Alessandra Punzi</b>	Department of Emergency and Organ Transplantation, Section of Pathology, University, Medical School, Bari, Italy
<b>Federica Pezzuto</b>	Department of Emergency and Organ Transplantation, Section of Pathology, University, Medical School, Bari, Italy
<b>Edoardo Di Naro</b>	Department of Emergency and Organ Transplantation, Section of Pathology, University, Medical School, Bari, Italy
<b>Teresa Marrano</b>	Department of Emergency and Organ Transplantation, Section of Pathology, University, Medical School, Bari, Italy
<b>Gabriella Serio</b>	Department of Emergency and Organ Transplantation, Section of Pathology, University, Medical School, Bari, Italy

### ABSTRACT

Yolk sac tumours of the ovary (YST) are rare and highly malignant tumours occurring in children and young adults. Cases of pure or mixed endodermal sinus tumours of the ovary arising in post-menopausal women are exceptional. Prognosis is good in the early stage, with a 5-year survival rate of 95%. After surgery, chemotherapy (bleomycin, etoposide, cisplatin) is the current standard therapy. Serum alpha-foeto protein (AFP) is a useful marker in the diagnosis and management of YST. We present a case of a tumour producing alpha-foetoprotein (AFP) that affected a 77-year-old woman, treated with combined chemotherapy, and who is disease-free at 18 months after diagnosis (the last follow-up).

### KEYWORDS

Ovary, YST, elderly woman

### 1. Introduction

A primitive endodermal tumour (Yolk sac tumour) is a germ cell tumour with a variety of distinctive patterns which may exhibit differentiation into endodermal structures, ranging from the primitive gut and mesenchyme to derivatives of extra-embryonal (secondary yolk sac and allantois) and embryonal somatic tissues (intestine, liver and mesenchyme). Consequently, it includes a multifaceted group of neoplasms, for which the term *primitive endodermal tumours* would be more appropriate. After dysgerminomas, YST is the second most common ovarian germ cell malignant tumour (approximately 20–25%) and is frequently a *pure* tumour.<sup>1,2</sup>

The human yolk sac is an organ of paramount importance in early development, and hence its many functions are reflected in the production of numerous substances such as AFP and glypican-3 (GLP3) that regulate cellular growth and apoptosis, and that can potentially be present in the neoplastic counterpart. In fact, serum levels of alpha-foetoprotein (AFP) are used as typical neoplastic markers and are correlated with pathological features. Clinically, AFP is the gold standard marker for YSTs, although it can be produced by many non-germ cell tumours, especially of the female genital tract, and also by tumours of other organs, usually of endodermal origin and frequently with a hepatoid component.<sup>2,3</sup>

We present a tumour producing alpha-foetoprotein (AFP) that

affected a 77-year-old woman, treated with combined chemotherapy, and who is disease-free at 16 months after diagnosis (the last follow-up).

### 2. Case report

A 77-year-old woman, gravida 2, para 2, menopause at 50 years, with a history of diabetes and hypothyroidism, consulted our hospital for abdominal pain and frequent urination. Physical examination demonstrated a moderate abdominal enlargement. Pelvic transabdominal ultrasound revealed a heterogeneous right ovarian mass, measuring about 16 cm in diameter, as well as moderate ascites. The tumour featured numerous septa, abundantly vascularized with a low resistance flow, bordering cysts of various sizes containing finely corpusculated matter (Figure 1). Subsequent abdominal and pelvic computerized tomography (CT scan) confirmed the ultrasound findings and also showed an increased size of the left ovary (6.5 cm in diameter). Some pericentric lymphadenopathies were observed in the pelvic and paracaval regions. Free fluid in the right pleural cavity, with ipsilateral pulmonary parenchymal atelectasia, were also reported. Hysteroscopy showed an atrophic endometrium associated with microcalcifications. Laboratory tests revealed an elevated serum AFP level, 56.944 ng/ml; CA125, 1267.6 U/ml; Ca19.9, 79 U/ml. The patient underwent total hysterectomy, bilateral salpingo-oophorectomy, appendectomy, and omentectomy. Informed consent to the use of her data was obtained from the patient.

### Pathology Findings

Gross examination showed a large ovarian tumour, 17x15.5 cm in diameter, weighing 1250 gr. The external surface was smooth and the sectioned surface was solid and cystic and composed of soft, friable, yellow to grey tissue (Figure 2). Areas of haemorrhage and necrosis were present. Frozen section examination was suggestive of an ovarian epithelial carcinoma (serous vs clear cell carcinoma). The definitive microscopic examination showed characteristics consistent with a YST. Malignant solid and hepatoid areas were observed, and glandular structures with a clear cytoplasm floating within abundant myxoid stroma, as well as secondary structures consistent with Schiller-Duval bodies. The tumour cells were strongly immunopositive for keratin AE1/AE3, AFP, HepPar-1 (Figure 3). Focal immunopositivity for EMA was also detected. Moreover, focal areas of serous epithelial differentiation were observed. Five days after surgery, the  $\alpha$ FP value had dropped to 15.964 (ng/ml). Adjuvant treatment consisting of 4 cycles of combined chemotherapy according to standardized protocols (BEP regimen) was administered (cisplatin 20mg/mq; etoposide 100mg/mq; bleomycin 18mg/mq). At 18 months from the end of treatment, the clinical examination, blood marker measurements (AFP normal, 4.3 ng/ml) and imaging (PET and CT-scan) demonstrated complete remission.

### 3. Discussion

Ovarian YST generally develops in adolescents or young women (median age 19-20 years), in whom preservation of fertility is a necessary goal.<sup>4,5</sup> Only exceptionally has the tumour been observed in elderly women.<sup>6-8</sup>

The common presenting symptoms are a rapidly enlarging abdominal or pelvic mass, and pain. Some women were pregnant at presentation.<sup>9</sup> Elevated serum alpha-foeto-protein (AFP) levels are observed preoperatively at diagnosis, and are generally greater than 1000 ng/ml; subsequently this marker can be used to check complete remission or tumour recurrence. Increased levels of CA125 and carcinoembryonic antigen (CEA) are not infrequent.

Preoperative radiological diagnostic methods [ultrasound, CT scan or magnetic resonance imaging (MRI)] are not specific to distinguish YST from other ovarian masses. At laparotomy, mainly in young women, the disease is limited to one ovary in 55% of cases (FIGO stage I), confined to the pelvis (FIGO stage II) in about 5%, 25-30% being stage III and 10% stage IV (11). At presentation, bilateral ovarian involvement or distant metastases are rare.

Before the advent of combination multi-agent chemotherapy, the prognosis of OYST was extremely dismal and patients died of disease progression within 3 years after diagnosis.

Histologically, YST is characterized by a variety of distinctive microscopic patterns i.e. a reticular, polyvesicular-vitelline, hepatoid and intestinal or endometrioid-like pattern.<sup>1</sup> Because of their rare occurrence in older females, YSTs may be confused with a variety of other tumours, and differential diagnosis from clear cell carcinoma, as well as between endometrioid or hepatoid carcinomas, can be difficult. Cases of YST described in postmenopausal women had a worse prognosis than in younger women, mainly when an epithelial tumour component was observed.<sup>8,10</sup> The introduction of BEP chemotherapy has clearly improved the survival rate of this cancer, even if diagnostic and prognostic aspects are still under debate. Although many aspects have been largely studied, we still have some loose ends to tie up, mainly as regards diagnostic modalities and prognostic aspects of fertility-sparing surgery. Preoperative instrumental diagnosis is based on the combination of ultrasound and/or magnetic resonance imaging (MRI) with FP results. Ultrasound findings reveal a large ovarian tumour, mainly solid with multicystic spaces, bordered by a small, thin, abundantly vascularized septum, about 2.5mm thick.<sup>11</sup> Color Doppler mapping reveals a highly vascularized tumour containing numerous low resistance flow vessels in the septa, as well as in solid portions of the malignancy.

Our ultrasonographic findings confirmed this heterogeneous appearance, as the tumour was predominantly solid at the periphery, mixed with cystic areas. The round appearance of the cystic space and presence of low resistance vessels in the septa were characteristic of a large YST.

The cystic pattern might be due to cystic degeneration or necrosis and reflects the rapid growth of the tumour. MRI highlights the haemorrhagic spots and confirms the hypervascularity in T1-weighted sequences.<sup>11,12</sup> Therefore, peculiar imaging findings of YST include a large, complex ovarian mass, multiple highly vascularized septa with multiple small RI arterioles, areas of necrosis and haemorrhagic spots, sometimes accompanied by the presence of ascites.

The role of CT scan has not been well studied, although it could be useful mainly in the identification of images suggestive of relapse. If a pelvic mass with such imaging suggestive of this type of malignancy is seen, the serum AFP level should be evaluated, as a typical marker to exclude a YST. From a prognostic point of view, very high  $\alpha$ FP values, the stage, histological subtype and response to chemotherapy are important prognostic factors.

Serum AFP levels <1000 ng/mL are in the good prognostic category, while levels >10,000 ng/mL are poor. The stage is the most important prognostic factor, although in recent studies the administration of BEP chemotherapy has remarkably improved 5 year survival in stages III and IV, from 30-25% to 65%.<sup>13-15</sup> Although a volume (<100 ml) of ascitic fluid, the residual tumour, and alpha FP level are considered as specific prognostic factors, their importance has diminished since the advent of BEP chemotherapy. Moreover, further studies did not confirm a correlation between preoperative  $\alpha$ FP and survival since this marker could reflect the presence of vitelline components. Finally, the prognostic value of histology is not correlated to a pure or mixed character of the tumour, but could be correlated to the number of histological variants, being better if more than two variants are present. From a therapeutic point of view, conservative surgical treatment does not influence the prognosis of YST.<sup>14,15</sup>

Of the documented cases of pure endodermal sinus tumours in post-menopausal women, final outcomes have not been consistently reported, but mixed cases usually have a poor prognosis. Patients often experienced a laboratory response but subsequently died of disease, several months after the initial diagnosis.<sup>16</sup>

Mixed tumors represent an aggressive ovarian malignancy variant, associated with a rapid growth pattern, advanced stage at diagnosis, poor response to cisplatin-based chemotherapy regimens, frequent recurrence of the disease and early death.<sup>8</sup>

Fertility-sparing surgery is a consolidated procedure, from the reproductive point of view, and safe from the disease-free survival point of view, in early stage ovarian cancers. Its efficacy has been demonstrated in borderline tumours, ovarian serous tumours and ovarian germ cells tumours. In the latter, annexectomy has the same therapeutic value as radical surgery.<sup>8,10</sup> In our experience, although fertility-sparing surgery is preferred, it is invariably comprehensive of all suspected lesions, and includes peritoneal cytology, omentectomy and random biopsies, in order to prevent a growing teratoma.

Moreover, conservative surgery associated with adjuvant chemotherapy can be performed in high grade or more advanced stages than IA ovarian tumors, with an acceptable long term reproductive performance (30%) and without recurrence at 70 months follow-up.

The presence of YST associated with an epithelial tumour in older women supports the concept that they may originate from these epithelial neoplasms, which can be considered precursor lesions of YST, especially in this age group. Of the 24

cases described up to now, 18 were associated with an epithelial tumour, and survival rate at two years was 66%. The most common precursor lesion is endometrioid carcinoma, although other epithelial tumours such as mucinous, serous, clear cell carcinoma and malignant Müllerian mixed tumours or endometrioid cysts and adenofibromas can be associated. The diagnosis of YST in postmenopausal women is associated with a poor prognosis, in mixed cases (66%) as well in pure cases (83%).<sup>1,16-18</sup>

On the other hand, it is possible that postmenopausal cases could represent a distinct disease from those observed in young patients and, therefore, that it should be treated aggressively since it is less responsive to chemotherapy.

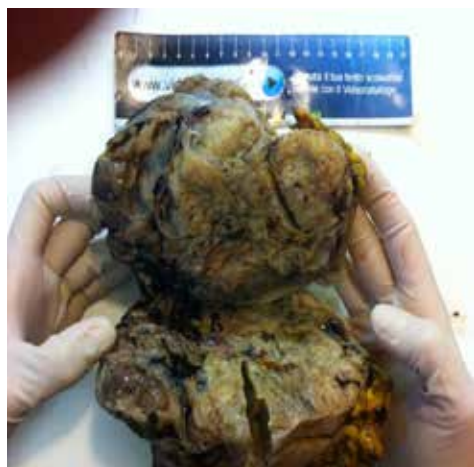
Acknowledgment: We are grateful to Mary V. Pragnell, BA, for language assistance.

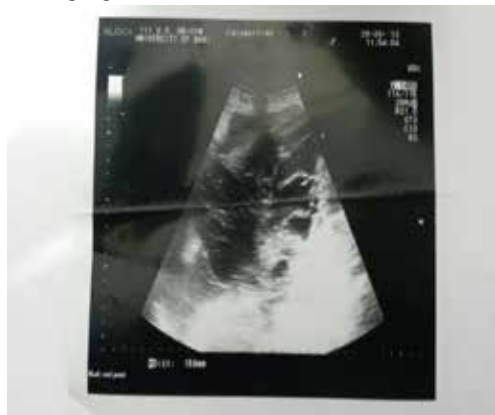
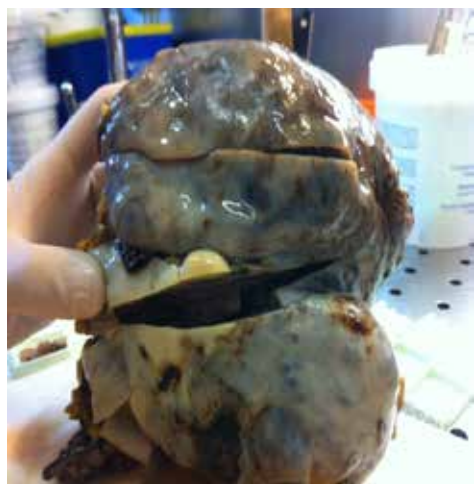
Figure 1. Transvaginal ultrasound YST of the ovary.

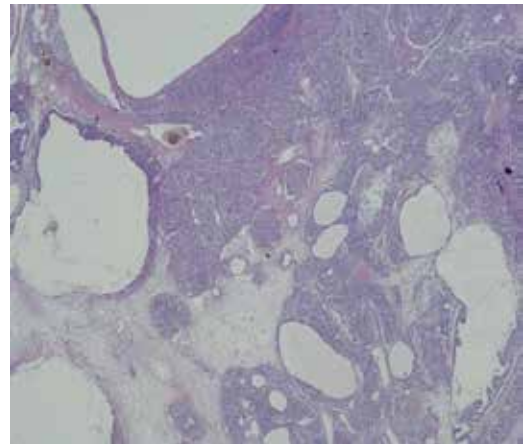


A

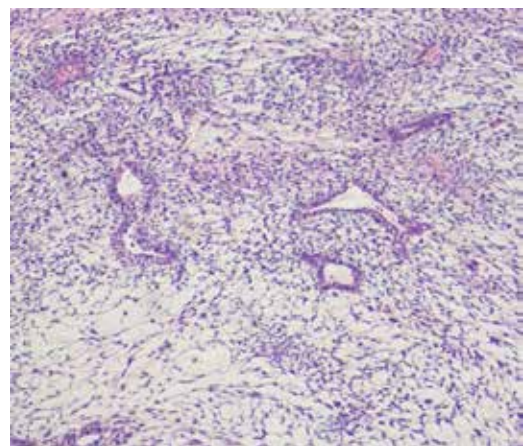


B

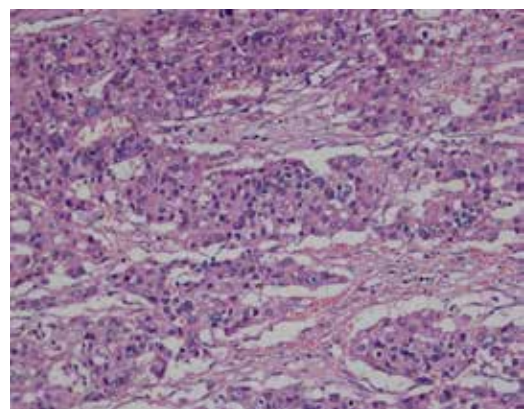
Figure 2. A) Macroscopic aspect of the ovary and B) cut surface of the tumour.



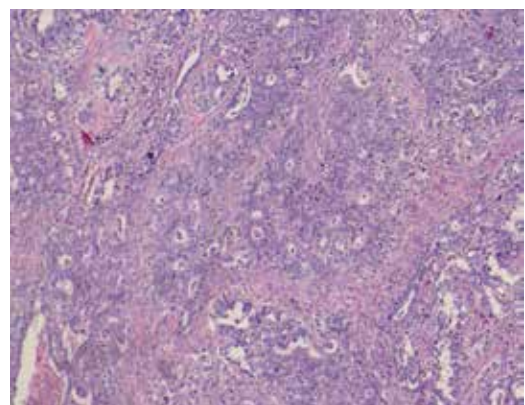
A



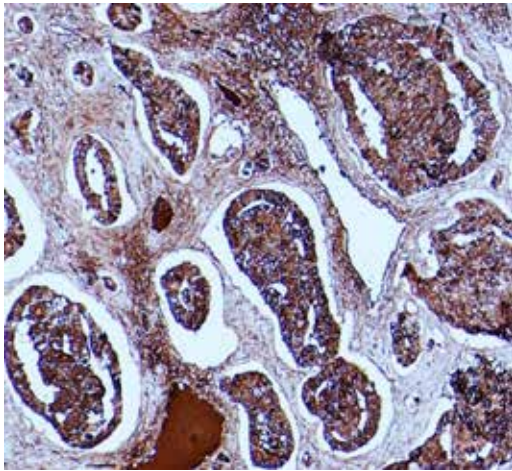
B



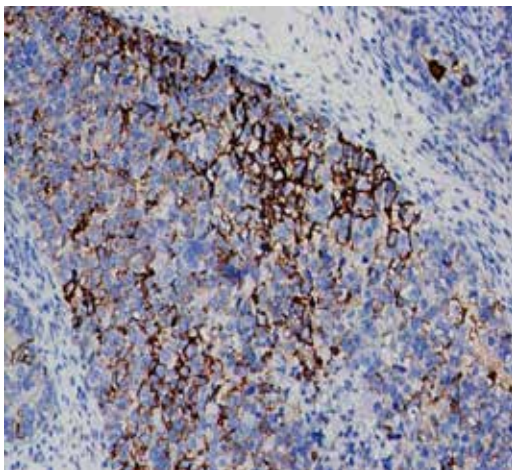
C



D



E



F

Figure 3. A) Multicystic polyvitelline pattern (HE, original magnification x100). B) Myxomatous pattern (HE, original magnification x100). C) Hepatoid pattern (HE, original magnification x100). D) Cribriform/tubular pattern (HE, original magnification x100). E) Immunopositivity for AFP (original magnification x200); F) Hepatocyte paraffin antigen 1 immunopositivity (original magnification x100).

## REFERENCES

1. WHO Classification of Tumours of Female Reproductive Organs. 4th Edition. Ed. Kurman RJ, Carcangiu ML, Herrington CS, Young RH. Lyon, 2014. | 2. Nogales FF, Dulcey I. The secondary human yolk sac has an immunophenotype indicative of both hepatic and intestinal differentiation. *Int J Dev Biol* 2012;56(9):755-60. | 3. El-Bahrawy M: Alpha-fetoprotein-producing non-germ cell tumours of the female genital tract. *J Eur J Cancer* 2010;46(8):1317-22. | 4. Abdullah NA, Wang PN, Huang KG, Adlan AS, Casanova J. Sustainable complete remission in recurrence yolk sac tumor patient treated with tandem high-dose chemotherapy and autologous stem cell. *Eur J Gynaecol Oncol* 2013;34(2):183-85. | 5. Kojimahara T, Nakahara K, Takano T, Yaegashi N, Nishiyama H, Fujimori K et al. Yolk sac tumor of the ovary: a retrospective multicenter study of 33 Japanese women by Tohoku Gynecologic Cancer Unit (TGCU). *Tohoku J Exp Med* .2013;230(4):211-17. | 6. Kammerer-Doak D, Baurick K, Barbo DM, Smith HO. Endodermal sinus tumor and embryonal carcinoma of the ovary in a 53-year-old woman. *Gynecologic Oncology* 1996;63:133-37. | 7. Lange S, Livasy C, Tait DL. Endodermal sinus tumor of the ovary in an 86 year old woman. *Gynecol Oncol Case Rep* 2012;2(2):65-6. | 8. Meguro S, Yasuda M. -Fetoprotein-producing ovarian tumor in a postmenopausal woman with germ cell differentiation. *Ann Diagn Pathol* 2013;17(1):140-44. | 9. Farahmand SM, Marchetti DL, Asirwatham JE, Dewey MR. Ovarian endodermal sinus tumor associated with pregnancy: review of the literature. *Gynecol Oncol* 1991;41(2):156-60. | 10. Nawa A, Obata N, Kikkawa F, Kawai M, Nagasaka T, Goto S, et al. Prognostic factors of patients with yolk sac tumors of the ovary. *Am J Obstet Gynecol* 2001;184(6):1182-88. | 11. Yamaoka T, Togashi K, Koyama T, Ueda H, Nakai A, Fujii S, et al. Yolk sac tumor of the ovary: radiologic-pathologic correlation in four cases. *J Comput Assist Tomogr* 2000;24(4):605-09. | 12. Howe FA, Robinson SP, McIntyre DJ, Stubbs M, Griffiths JR. Issues in flow and oxygenation dependent contrast (FLOOD) imaging of tumours. *NMR Biomed* 2001;14(7-8):497-506. | 13. de La Motte Rouge T, Pautier P, Rey A, Duvillard P, Kerbrat P, Troalen F, et al. Prognostic factors in women treated for ovarian yolk sac tumour: A retrospective analysis of 84 cases. *Eur J Cancer* 2011 Jan;47(2):175-82. | 14. Cicin I, Saip P, Guney N, Eralp Y, Ayan I, Kebudi R, Topuz E. Yolk sac tumours of the ovary: evaluation of clinicopathological features and prognostic factors. *Eur J Obstet Gynecol Reprod Biol* 2009;146(2):210-14. | 15. Satoh T, Aoki Y, Kasamatsu T, Ochiai K, Takano M, Watanabe Y, et al. Administration of standard-dose BEP regimen (bleomycin+etoposide+cisplatin) is essential for treatment of ovarian yolk sac tumour. *Eur J Cancer* 2015;51(3):340-51. | 16. Roth LM, Talerman A, Levy T, Sukmanov O, Czernobilsky B. Ovarian yolk sac tumors in older women arising from epithelial ovarian tumors or with no detectable epithelial component. *Int J Gynecol Pathol* 2011;30(5):442-51. | 17. Varia M, McCluggage WG, Oommen R. High grade serous carcinoma of the ovary with a yolk sac tumour component in a postmenopausal woman: report of an extremely rare phenomenon. *J Clin Pathol*. 2012;65(9):853-54. | 18. Nogales FF, Bergeron C, Carvia RE, Alvaro T, Fulwood HR. Ovarian endometrioid tumors with yolk sac tumor component, an unusual form of ovarian neoplasm. Analysis of six cases. *Am J Surg Pathol* 1996;20(9):1056-66. |