



Left Atrial Myxoma Excision

Dr. Suraj Wasudeo Nagre

Assistant Professor c.v.t.s. Grant medical college, mumbai

ABSTRACT

Left atrial myxomas remain the most common benign primary cardiac tumors, and these cardiac growths can masquerade as mitral stenosis, infective endocarditis and collagen vascular disease. Atrial myxomas are found in approximately 14-20% of the population and can lead to embolization, intercardiac obstructions, conduction disturbances and lethal valve obstructions. We describe a case of an asymptomatic young female who presented with history of giddiness and two episodes of syncopal attacks in past two months. After echocardiography diagnosed to have large left atrial myxoma intermittently obstructing mitral valve outflow requiring urgent excision.

KEYWORDS

Introduction

Cardiac myxoma are uncommon tumours found in 0.5 million population per year with left atrium being the predominant site. They vary widely in size, and very little is known about their growth rate. The reported growth rates of left atrial myxomas from several published case reports appears to vary from no growth, to between 1.3 to 6.9 mm/month in diameter within patients with established myxoma who have not undergone surgery. The prevalence of cardiac tumors at autopsy ranges from 0.001% to 0.3%, more than 50% of benign cardiac tumors are myxomas. In 7%, it has genetic origin and rises as a component of a heritable disorder with some clinical manifestations. Over 72% of primary cardiac tumors are benign. In adults, the majority of benign lesions are myxomas [4,5].

The origin can be explained through different theories. Myxomas are currently thought to originate from entrapped entrapped embryonic foregut, and hence they are derived from multipotent mesenchymal cells capable of both neural and epithelial differentiation. Histologically, these tumors are composed of scattered cells within a mucopolysaccharide stroma. Myxomas produce vascular endothelial growth factor (VEGF), which probably contributes to the induction of angiogenesis and the early stages of tumor growth [6,7].

On a macroscopic level, typical myxomas are pedunculated and gelatinous in consistency; the surface may be smooth, villous, or friable. Tumors vary widely in size, ranging from 1 to 15 cm in diameter, and weighing between 15 and 180 g. About 35 percent of myxomas are friable or villous, and these tend to present with emboli. Larger tumors are more likely to have a smooth surface and to be associated with cardiovascular symptoms [8].

Systemic embolisation and sudden death are common, which warrant an early surgical intervention. Although quite rare, left atrial myxomas account for 80% of all cardiac tumors. Diagnosis is often difficult due to the wide array of presenting symptoms. Atrial myxomas are associated with systemic embolization in 30 to 40% of cases [3]. These intracardiac growths may masquerade as mitral stenosis, infective endocarditis, and collagen vascular disease, which can further impede accurate diagnosis. Constitutional symptoms (e.g., fever, weight loss) are seen in around 30 percent of patients. Laboratory abnormalities (e.g., anemia and elevations in the erythrocyte sedimentation rate, C-reactive protein, or globulin level) are present in 35 percent, usually those with systemic symptoms [9].

There are several mechanisms by which cardiac tumors may cause symptoms. The obstruction of the circulation through

the heart or heart valves produce symptoms of heart failure. Atrial myxoma may interfere with heart valves causing regurgitation. The direct invasion of the myocardium may result in impaired contractility, arrhythmias, heart block, or pericardial effusion with or without tamponade. The invasion of the adjacent lung may cause pulmonary symptoms and may mimic bronchogenic carcinoma. Finally, left atrial tumors may release tumor fragments or thrombi into the systemic circulation, leading to embolization which is usually systemic but can be pulmonary. The most serious complications of such embolization are neurologic. The rate of growth is unknown, as myxomas are mostly managed with surgical resection and only very rarely are medically managed due to contraindications to surgery [10]. The discriminatory marker for an atrial myxoma is often a tumor 'plop' heard upon auscultation at the apex of the heart. This is a report of such tumour with surgical and pathological confirmation of the echocardiographic diagnosis.

Case

32 years old female patient presented with history of giddiness and two episodes of syncopal attacks in past two months. The patient had no prior history of heart murmurs, shortness of breath, or chest pain. Further physical examination revealed a soft grade 1/6 systolic murmur at the left sternal border, with no diastolic murmur present. There was no evidence of a tumor 'plop'. Transthoracic echo suggestive of left atrial myxoma protruding into mitral valve obstructing flow across it [FIGURE 1].

Cardiac catheterization showed eccentric mitral regurgitation, defining the posterior border of the large atrial mass. Transesophageal echocardiography, carried out at the time of surgery, revealed a large myxoma prolapsing through the mitral valve leaflets into the left ventricle

Surgery was performed via a standard midline sternotomy. After going on cardiopulmonary bypass with bicaval cannulation, the myxoma and tumour was removed via right atrium approach. Stab is made in interatrial septum at site of PFO.

The myxoma was held gently with artery or Babcock's forceps avoiding crushing it and dissection was carried by making plane with artery forceps, stab knife and scissor [FIGURE 2]. Left atrial myxoma was excised intact along with part of interatrial septum where stalk of myxoma attached. Surgical resection was performed, revealing a mass with a smooth grey, brown surface suggestive of atrial myxoma [FIGURE 3]. Histopathology was confirmatory showing characteristic polygonal and stellar tumor cells.

Defect so created was closed with pericardial patch .Four weeks postoperatively, the patient stated that the original complaint of 'dizziness upon standing' had disappeared, with Postoperative course was uneventful .Our patient has remained asymptomatic for two years after surgery, with no recurrence of myxoma on TTE.

Discussion

Atrial myxoma is the most common benign tumor of the heart and has a greater predilection to the left atrium. Embolic phenomena is thought to be caused by either tumor detachment or clot embolization. Patients can present with dyspnea on exertion, palpitations, or congestive heart failure. Autoimmune features include: constitutional symptoms, fatigue, fever, myalgia, arthralgia, muscle weakness, rash, and weight loss. Activation of pro-inflammatory cytokines such as: IL-6 and Tumor Necrosis Factor alpha (TNF α) have been implicated.^[11] Often thrombolysis is given to patients presenting with stroke prior to diagnosing atrial myxoma. Although, randomized clinical data is lacking, managing this challenging scenario has resulted in variable results including: clinical improvement, persistent neurological deficits, or death.^[12]

Common symptoms and signs of dyspnea, orthopnea, paroxysmal nocturnal dyspnea, pulmonary edema, cough, hemoptysis, edema, and fatigue lead to a wide differential diagnosis, making it critical for clinicians to be consider atrial myxoma. The goals of the initial evaluation are to ascertain whether or not a cardiac tumor is present, the location of the lesion within the heart and, to the extent possible, whether a tumor is benign or malignant. This information is vital in planning further evaluation and management. Echocardiography, cardiac MRI, and ultra-fast CT provide complementary information to address these questions.

Echocardiography

Echocardiography is widely available and provides a simple, noninvasive technique for the initial evaluation. Echocardiography images both the myocardium and the cardiac chambers can usually identify the presence of a mass. In addition, echocardiography may provide information about any obstruction to the circulation, as well as the likelihood that the tumor could be a source of emboli [13].

Although Transthoracic Echocardiography (TTE) is simple and usually can identify a tumor, Transesophageal Echocardiography (TEE) may be more informative. The superior diagnostic utility of TEE is due to the proximity of the esophagus to the

heart, the lack of intervening lung and bone, and the ability to use high-frequency imaging transducers that afford superior spatial resolution. In our patient, the TTE was sufficient in confirming the diagnosis [13].

Treatment and prognosis

Once a presumptive diagnosis of myxoma has been made on imaging studies, prompt resection is required because of the risk of embolization or cardiovascular complications, including sudden death. The results of surgical resection are generally very good, with most series reporting an operative mortality rate under 5 percent [14]. Cardiac transplantation has been reported for other tumors and might be considered for multiple, recurrent atrial myxomas [15].

Postoperative recovery is generally rapid. However, atrial arrhythmias or atrioventricular conduction abnormalities were present postoperatively in 26 percent of patients in one series. In addition, patients are at risk for recurrence of the myxoma or the development of additional lesions. In one large series, 5 percent developed recurrent myxoma, suggesting the need for careful follow-up. Development of a second primary myxoma may be more common in patients with a family history of myxoma [16,17].

Conclusion

Rapidly growing myxoma may be mistaken for thrombus, and may require urgent surgical excision to reduce the risk of associated complications such as thrombo-embolic events, sudden cardiac death and removal of a possibly malignant tumor. The potential for rapid growth should be considered if there is a plan to delay surgery. Our experience suggests that surgery for atrial myxoma is safe and simple by precautions to protect from embolisation like minimal handling of heart before going on bypass and use of heamofilter during cardiopulmonary bypass . Early surgical intervention after diagnosis can significantly reduce the possibility of sudden death and other embolic complications. Although atrial myxomas are usually benign or asymptomatic, there is the possibility of diastolic embolization [2], conduction alterations and disturbances, and lethal valve obstructions occurring [1]. Since surgical excision has been reported to alleviate symptoms associated with cardiac myxomas, early identification and removal is preferable.

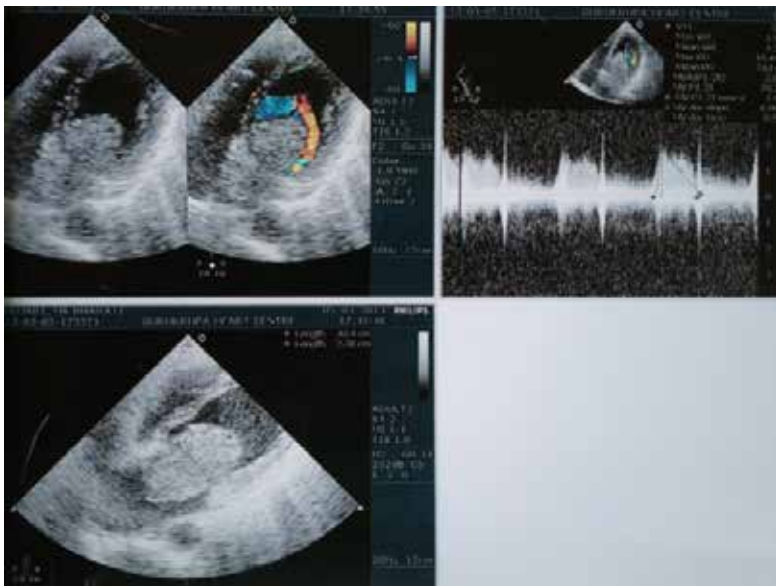


Figure 1 Transthoracic echo suggestive of left atrial myxoma protruding into mitral valve obstructing flow across it .

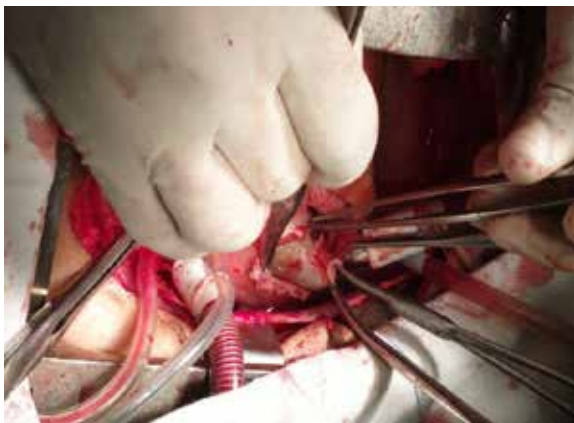


Figure 2 The myxoma was hold gently with artery or babcocksforcep avoiding crushing it and dissection was carried by making plane with artery forcep ,stab knife and scisser .

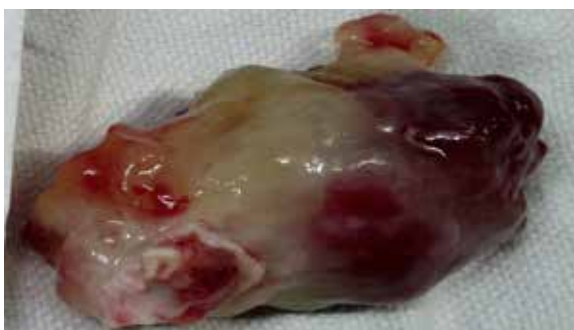

Figure 3 Excised specimen a mass with stalk a smooth grey, brown surface suggestive of atrial myxoma .

REFERENCES

- Colucci WS, Schoen FJ: Chapter 49. In Primary Tumors of the Heart. Heart Disease: A Textbook of Cardiovascular Medicine. Volume 2. 6th edition. Edited by Braunwald E, Zipes D, Libby P. Philadelphia, Pennsylvania, USA: W.B. Saunders Company; 2001:1809-1819. | 2. Braun S, Schrotter H, Reynen K, Schwencke C, Strasser RH: Myocardial infarction as complication of left atrial myxoma. *Int J Cardiol* 2005, 101(1):115-121. PubMed Abstract | Publisher Full Text | 3. Burke AP, Virmani R: Cardiac myxoma: a clinicopathologic study. *Am J ClinPathol* 1993, 100:671-680. PubMed Abstract | 4. Yu K, Liu Y, Wang H, Hu S, Long C. Epidemiological and pathological characteristics of cardiac tumors: a clinical study of 242 cases. *Interact CardiovascThorac Surg.* 2007;6(5):636-639. | [Medline][CrossRef] | 5. Amano J, Kono T, Wada Y, Zhang T, Koide N, Fujimori M, Ito K. Cardiac myxoma: its origin and tumor characteristics. *Ann ThoracCardiovasc Surg.* 2003;9(4):215-221. | [Medline] | 6. Mallick SR, Das P, Shukla B, Kothari S, Devagourou V, Ray R. Right atrial myxoma with glandular differentiation: A rare entity in pediatric age group. *Ann PediatrCardiol.* 2010;3(2):159-162. | [Medline] | 7. Lloreta J, Juanpere N, Riverola A, et al. Cardiac myxoma with glandular differentiation: an immunohistochemical and ultrastructural Study. *Ultrastructural Pathology, Ahead of Print:*1-6. | 8. Pinede L, Duhaut P, Loire R. Clinical presentation of left atrial cardiac myxoma. A series of 112 consecutive cases. *Medicine (Baltimore).* 2001;80(3):159-172. | [Medline][CrossRef] | 9. Aggarwal SK, Barik R, Sarma TC, Iyer VR, Sai V, Mishra J, Voleti CD. Clinical presentation and investigation findings in cardiac myxomas: new insights from the developing world. *Am Heart J.* 2007;154(6):1102-1107. | [Medline][CrossRef] | 10. Burke AP, Gomez-Roman JJ, Loire R, et al. World Health Organization: Tumours of the lung, pleura, thymus and heart. IARC Press 2004. | 11. Mendoza, C. E., M. F. Rosado, et al. (2001). "The role of interleukin-6 in cases of cardiac myxoma. Clinical features, immunologic abnormalities, and a possible role in recurrence." *Tex Heart Inst J* 28(1): 3-7. | 12. Nagy, C. D., M. Levy, et al. (2009). "Safe and effective intravenous thrombolysis for acute ischemic stroke caused by left atrial myxoma." *J StrokeCerebrovasc Dis* 18(5): 398-402 | 13. Yoo M, Graybeal DF. An echocardiographic-confirmed case of atrial myxoma causing cerebral embolic ischemic stroke: a case report. *Cases J.* 2008;1(1):96. | [Medline] | 14. Rahmanian PB, Castillo JG, Sanz J, Adams DH, Filsoufi F. Cardiac myxoma: preoperative diagnosis using a multimodal imaging approach and surgical outcome in a large contemporary series. *Interact CardiovascThorac Surg.* 2007;6(4):479-483. | [Medline][CrossRef] | 15. Reardon MJ, Malaisrie SC, Walkes JC, Vaporciyan AA, Rice DC, Smythe WR, DeFelicce CA, et al. Cardiac autotransplantation for primary cardiac tumors. *Ann Thorac Surg.* 2006;82(2):645-650. | [Medline][CrossRef] | 16. Castells E, Ferran V, Octavio de Toledo MC, Calbet JM, Benito M, Fontanillas C, Granados J, et al. Cardiac myxomas: surgical treatment, long-term results and recurrence. *J CardiovascSurg (Torino).* 1993;34(1):49-53. | [Medline] | 17. Vohra HA, Vohra H, Patel RL. Cardiac myxoma with three recurrences. *J R Soc Med.* 2002;95(5):252-253. | [Medline][CrossRef]