



A Rare Case of Glomus Tumour

| | |
|------------------|---|
| Dr. Rohin Bhatia | Associate Prof. Deptt. Of Neurosurgery Mahatma Gandhi Medical College |
| Dr. Rishabh Soni | 1st year resident Deptt. Of Orthopaedics Mahatma Gandhi Medical College , Jaipur (Raj.) |
| Dr. Abhishek | 2nd year resident Deptt. Of Orthopaedics Mahatma Gandhi Medical College , Jaipur (Raj.) |

| | |
|----------|--|
| ABSTRACT | <p>☞ The glomus tumour is a rare benign neoplasm that arises from the neuroarterial structure called a glomus body, which accounts for 1 % to 4.5 % of tumors in the hand.</p> <p>☞ The normal glomus body is located in the stratum reticulare throughout the body, but is more concentrated in the digits.</p> <p>☞ They are believed to function in thermal regulation. The average age at presentation is from 30 to 50 years of age, although can occur at any age.</p> |
|----------|--|

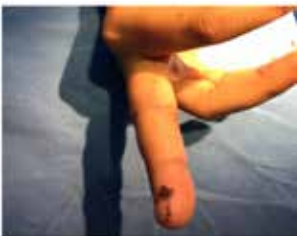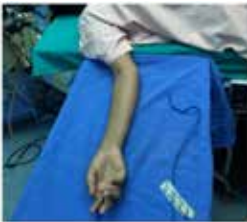| | |
|----------|--|
| KEYWORDS | |
|----------|--|

CASE DESCRIPTION :

- ☞ We are presenting a case of a 30yr old female with pain on the volar tip of middle finger of right hand.
- ☞ Pain was of On-Off nature firstly but was contionous and sharp from last 5 years.

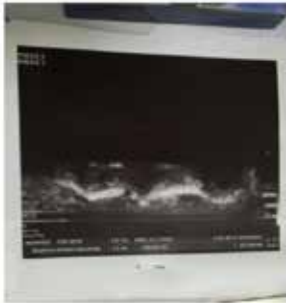
EXAMINATION:

- ☞ Tenderness which was severe present on the medial aspect of tip of middle finger of right hand.
- ☞ Skin was soft and shiny although no discoloration was present.
- ☞ Temperature was slightly raised as compared to the normal body temperature.
- ☞ No mass was felt on the tip although patient complained of sensation of some grainy mass sometimes.
- ☞ No swelling was present on the volar aspect of the tip of finger.



LABORATORY TEST :

- ☞ Patient was advised for **Duplex Ultrasonography** of the finger.
- ☞ RESULT-A well defined hypoechoic lesion measuring 33*16 mm without any obvious vascular uptake on colour doppler study was noted on ulnar aspect of distal phalynx of right middle finger.
- ☞ FINDINGS-GLOMUS TUMOUR/PARAGANGLIOMA

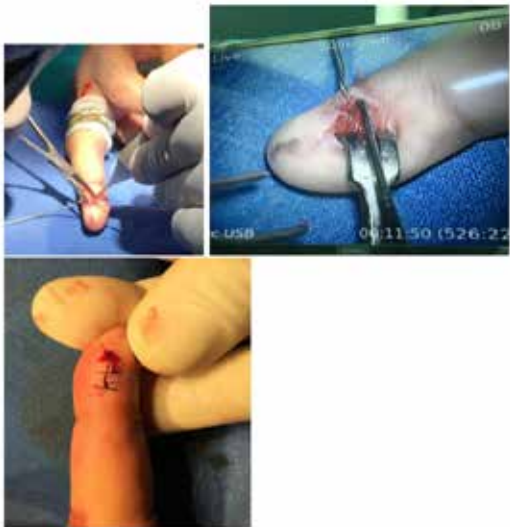

USG Report :

A well defined hyper echoic lesion 33*16mm is without any obvious vascular uptake on colour Doppler Study . Sugg astive of Glomus tumour .

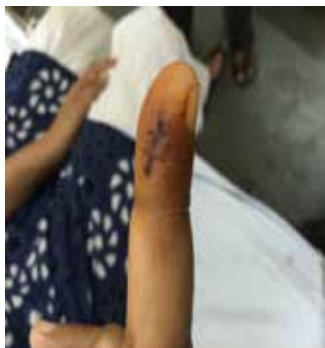SURGICAL MANAGEMENT:

- ☞ Excision remains the first line treatment for glomus tumour.
- ☞ Patient was operated on17/6/2015 under local anasthesia(ring block)
- ☞ Complete excision was done under microscope and 2 skin sutures were applied.



FOLLOW UP :

- ☞ Patient was advised to review after 7 days.
- ☞ Patient presented on 24/6/2015 and suture removal was done .
- ☞ Patient was complaining of slight pain which was mainly due to wound.

**FOLLOW UP AFTER 4 WEEKS :**

- ☞ Patient presented after 4 weeks with absolutely no complaint of pain.

REFERENCES

1. Carroll RE, Berman AT. Glomus tumors of the hand. J Bone Joint Surg. 1972;54A(4):691–703. [PubMed] || 2. Fornage BD. Glomus tumors in the fingers: Diagnosis with US. Radiology. 1988;167(1):183–185. [PubMed] || 3. Heys SD, Brittenden J, Atkinson P, Eremin O. Glomus tumor: An analysis of 43 patients and the review of the literature. Br J Surg. 1992;79:345–347. [PubMed] || 4. Matloub HS, Muoneke VN, Prevel CD, Sanger JR, Yousif NJ. Glomus tumor imaging: use of MRI for localization of occult lesions. J Hand Surg. 1992;17A:472–275. [PubMed] || 5. Mohler DG, Lim CK, Martin B. Glomus tumor of the plantar arch: A case report with magnetic resonance image findings. Foot & Ankle Int. 1997;18(10):672–674. [PubMed] || 6. Rettig AC, Strickland JW. Glomus tumor of the digits. J Hand Surg. 1977;2A(4):261–265. [PubMed]