Research Paper medical science

# An article onimaging of posterior fossa mass lesions in adults

**Dr.C.Nellaiappan** Associate professor of radiodiagnosis department,Tirunelveli medical college hospital,tirunelveli,Tamilnadu

**Dr.S.Nancydora** Associate professor of radiodiagnosis department,Tirunelveli medical college hospital,tirunelveli,Tamilnadu

**ABSTRACT**

Posterior fossa mass lesions in adults are multiple. Cerebellopontine angle lesions are common.cerebellar parenchymal lesions can also occur. In this article we discuss about differential diagnosis of posterior fossa mass lesions in adults.cerebellar gangliocytoma,meningioma are discussed in detail.

**KEYWORDS** computrisedtomography, magnetic resonance imaging, cerebellopontineangle, gangliocytoma, meningioma

## INTRODUCTION

Radiologic assessment of posterior fossa tumors may be achieved with several imaging techniques. computed tomography (CT),MRI are the standard techniques. Nuclearscan,-PETscan ,angiography are sometimes used.. The radiographic features of calcification, are usually well demonstrated on CT scan. MRI is particularly useful in distinguishing intra axial from extra axial lesions.The location and extent ofmasses can be defined using C Tand MRI. In this article, we discuss two mass lesionsin the posterior fossa in adults.

**Case 1:**

38 years female admitted in our hospital with headache and ataxia. CT scan was taken. It shows a hyper dense mass lesion in the posterior fosse on left side causing fourth ventricle compression and mild hydrocephalus(fig1). On contrast administration, the lesion shows good enhancement(fig2). MRI – Brain was taken for further evaluation. T1 hypo intense , T2 hyper intense extra axial lesion without internal auditory canal component is seen(fig3,4,5). On contrast, the lesion shows very good enhancement without cystic components(-fig6). Radiological differential diagnosis includes meningioma, acoustic nerve/ facial nerve schwannoma in atypical location. The patient underwent surgical removal. HPE is suggestive of fibroblastic men in gioma.

**Case 2:**

43 year old female admitted with headache and ataxia. CT scan was taken. It shows mixed dense mass lesion with predominant hypo dense areas in the midline of cerebellum causing compression of fourth ventricle and minimal hydrocephalus(fig7). MRI –Brain was taken for the future evaluation. It shows T1 mixed intense, T2 hyper intense lesion, not suppressed in FLAIR lesion in the midline cerebellum compressing fourth verticle(fig8,9,10).MRI FLAIR also shows prominent folia like patternwithin the lesion (fig10).On contrast no significant enhancement of mass seen(fig11,12). The radiological differential diagnosis include ependymoma, cerebellar astrocytoma,rarely dysplastic gangliocytoma. The patient underwent surgical removal of mass. HPE is suggestive of dysplastic gangliocytoma.

## DISCUSSION

Posterior fossa tumour has a very different differential in an adult as opposed to a child.

cerebellar metastases (most common)especially from lung cancer and breast cancerandalso frommelanoma, thyroid malignancies, and renal cell cancer. Haemangioblastoma is most common primary parenchymal cerebellar tumour. astrocytomas and medulloblastomas are rare in the posterior fossa of adults (<1% all tumours).

A. James Barkovich. Philadelphia, PA : Lippincott Williams & Wilkins (2005) found that brain tumor distribution varies with age as follows[1]

| | |
|---|---|
| 0 to 3 years of age | supratentorial>infratentorial |
| 4 to 10 years of age | infratentorial>supratentorial |
| 10 to early adult hood | infratentorial = supratentorial |
| adults | supratentorial>infratentorial |

James G. Smirniotopoulos, MD ,ancy Chang Yue, MD ,lisabetbj Rushing(1993) have shown the percentage of masses of cerebellopontine angle as follows

| **Masses of the CPA** | **PercentageMass of Cases[2]** |
|---|---|
| Acoustic (vestibular) schwannoma | 80-90 |
| Meningioma (petrous/tentonial) | 10-15 |
| Epidermoid inclusion cyst | 5-9 |
| Arachnoid cyst | <1 |
| Lipoma (lipomatoushamartoma) | <1 |
| Aneurysm | <1 |
| Ependymoma | <1 |
| Choroid plexus papilloma | <1 |
| Metastasis | <1 |

Classification of posterior fossa meningioma "Sekhar and Wright"[3]

| TYPE | LOCATION | ANATOMICAL EXTENSION |
|---|---|---|
| I | Cerebellar convexity, lateraltentorial | Tentorium,transverse and sigmoid sinus |
| II | CP angle | Petrous ridge,IAC |
| III | Jugular foramen | Cerebello medullary angle,internal jugular vein,extra cranial |
| IV | Petro clival | Upper 2/3rd clivus,cavernoussinus, meckelscave,petrous ridge |
| V | Foramen magnum | Lower 1/3rdclivus and $C_1$,$C_2$ area |
| VI | unclassified | Entire clivus,mid and lower clivus and other types |

Takashi M.D.; Ono, Yasuhiro M.D.; Matsumoto, Kengo M.D.; Ohmoto, Takashi M.D.(2001) found thatin patients with meningiomas, Tumor infiltration into adjacent brain parenchyma and a

pial-cortical blood supply are critical factors for the development of peritumoral brain edema[4]. In practicality, a balance between good functional outcome and extent of resection is important for posterior cranial fossa meningiomas in proximity to critical structurewas shown by Vijayakumar Javalkar, M.D., Anirban Deep Banerjee, M.D., and Anil Nanda, M.D., F.A.C.S in 2012[5]

Andrea Giorgianni, Carlo Pellegrino, Alessandro De Benedictis(2013) found that the dysplastic gangliocytoma is hypoattenuated on unenhanced computed tomographic (CT) images. In such cases, the only diagnostic clue may be the mass effect, which manifests as compression of the fourth ventricle, effacement of the cere bellopontine angle cistern and hydrocephalus[6].

MRI reveals the characteristic appearance of Lhermitte-Duclos-Disease[7]

MR imaging reveals a cerebellar mass with a typical striated, corduroy, or tiger-striped folial pattern that consists of alternating bands on both T1- and T2-weighted images. The bands are hyper- and isointense relative to gray matter on T2-weighted images and iso- and hypointense on T1-weighted images. Calcification is an uncommon finding, but it has been reported. Atul B.

Shinagare, MD, Nirupama K. Patil, MD, and S. Z. Sorte, MD,(2009) have shown that most dysplasticgangliocytomas do not enhance[8].Recognition of the disease is of particular importance, as the frequent but under-reported coexistence with Cowden syndrome.clinical and apparative investigation to detect or exclude concomitant malignancies should be prompted[9]. Joachim Klischa, FreimutJuenglinga, Joachim Spreera, DonatusKocha(2001) found that Although the exact pathophysiologic explanation for the signal characteristics of LDD in diffusion-weighted imaging/perfusion-weighted imaging, 1H MRS, FDG-PET, and 201-Tl SPECT remains unknown,the pathophysiology of this very rare entity may be answered by functional imaging studies of the lesion in future[10]

**CONCLUSION**

Posterior fossa mass lesions are different in adults than children. MRI is the best modality for evaluating posterior fossa lesions highlighted by above cases. Meningioma can occur anywhere in posterior fossa. Dysplastic cerebellar gangliocytoma is a rare entity. Non enhancing solid mass lesion inside cerebellar parenchyma between age of 30 to 50 should raise the possibility of this disorder in the radiologist mind.


**Fig1-CT shows hyperdense mass in left posterior fossa**


**Fig2-CT shows good enhancement of mass**

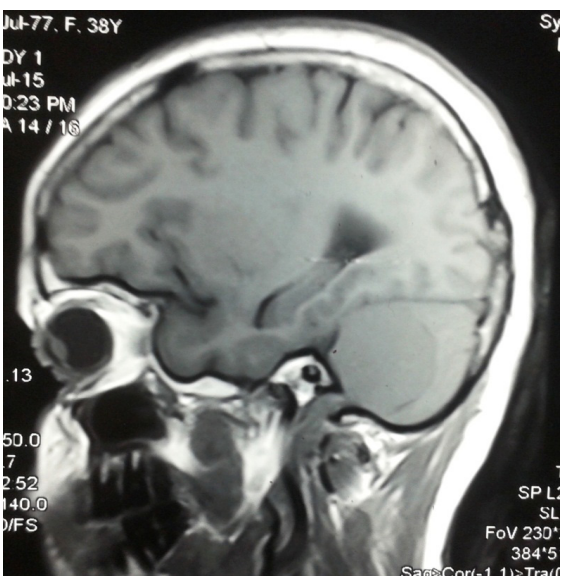


**Fig3-MRI $T_1$ W shows hypointense mass of posterior fossa**

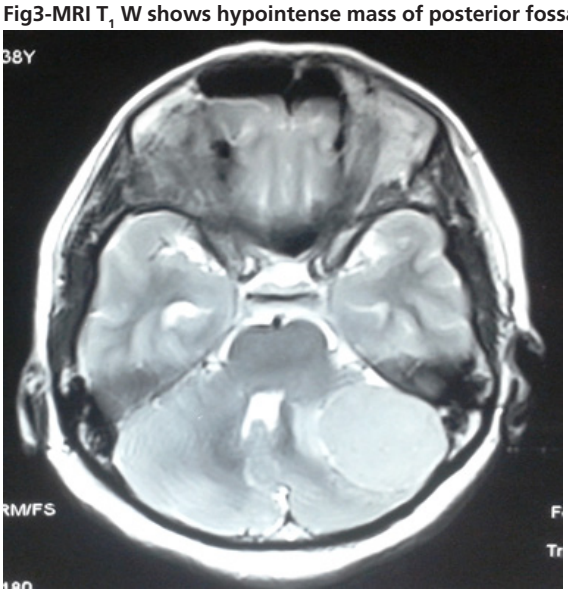

**Fig4-MRI T2W shows hyperintense mass lesion**

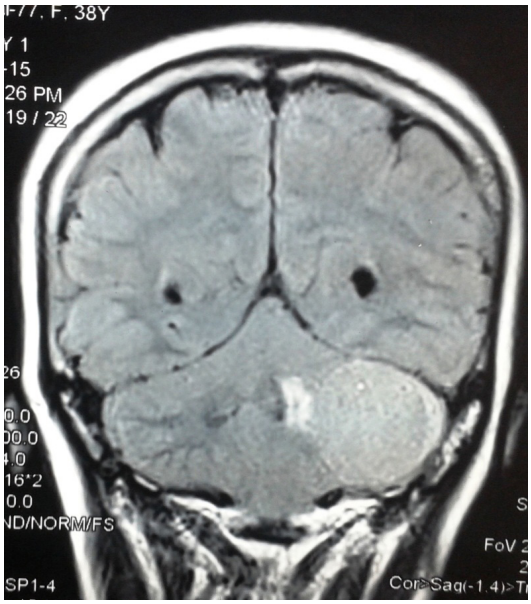

Fig5-MRI FLAIR shows hyperintense mass

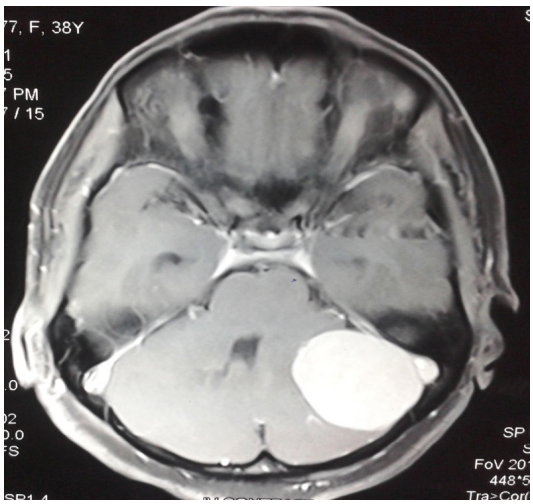

Fig6-MRI contrast shows good enhancement

Fig7-CT shows hypodense mass in midcerebellum

Fig8-MRI $T_1W$ shows hypointense mass

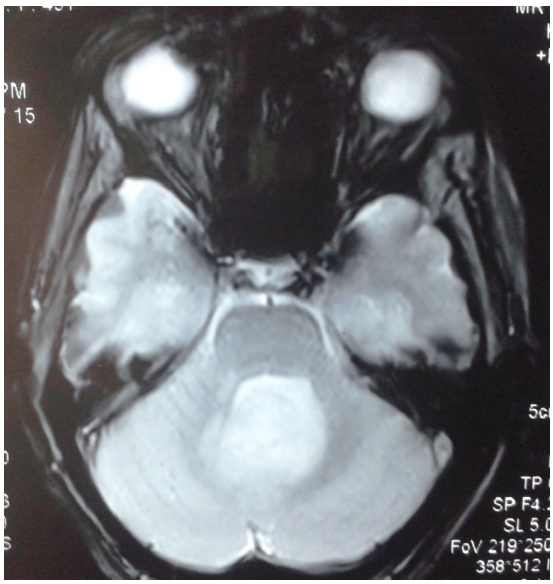

Fig9-MRI $T_2W$ shows hyperintense mass

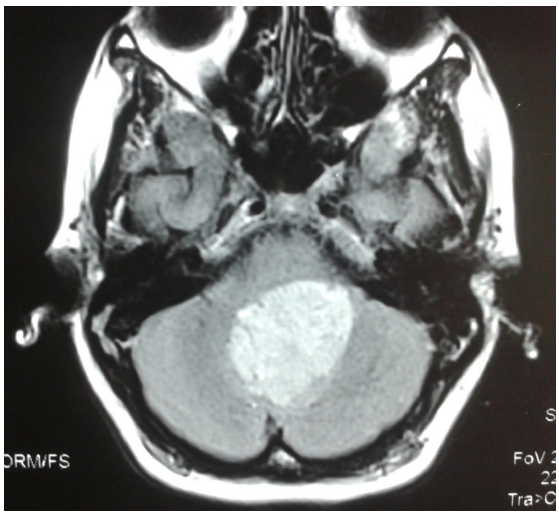

Fig10 MRI FLAIR -hyperintensitywith prominent folia like pattern

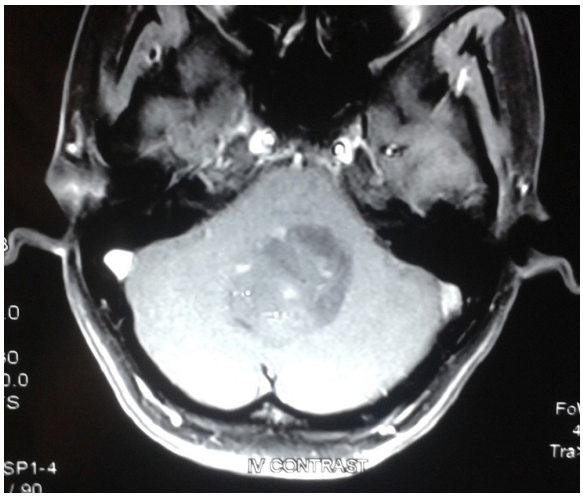


**Fig11 MRI axial contast-no significant enhancement**


**Fig12-MRI coronal contrast-no significant enhancement**

## REFERENCES

1. Pediatric neuroimaging. A. James Barkovich. Philadelphia, PA : Lippincott Williams & | Wilkins, c2005. ISBN:0781757665 | 2. Cerebellopontine Angle Masses:Radiologic-Pathologic Correlation. James G. Smirniotopoulos, MD ,ancy Chang Yue, lisabetbj Rushing,RadioGraphics 1993; 13:1131-! 147 | 3. Posterior fossa meningioma "our experience" in 64 cases,Vernon Velho, VivekAgarwal, Rahul Mally, and D. A. Palande, Asian J Neurosurg. 2012 Jul-Sep; 7(3): 116–124. | 4. Peritumoral Brain Edema in Intracranial Meningiomas: Effects of Radiological and Histological Factors,Tamiya, Takashi M.D.; Ono, Yasuhiro M.D.; Matsumoto, Kengo M.D.; Ohmoto, Takashi M.D.,Neurosurgery:November 2001 - Volume 49 - Issue 5 - pp 1046-1052 | 5. Posterior Cranial Fossa Meningiomas* VijayakumarJavalkar, M.D., Anirban Deep Banerjee, M.D., and Anil Nanda, M.D., F.A.C.S. J NeurolSurg B Skull Base. 2012 Feb; 73(1): 1–10. | 6. Lhermitte-Duclos Disease A Case Report Andrea Giorgianni, Carlo Pellegrino, Alessandro De Benedictis, Anna Mercuri, Fabio Baruzzi, Renzo Minotto, Antonio Tabano, and Sergio Balbi3 Neuroradiol J. 2013 Dec; 26(6): 655–660. | 7. Assessing a Dysplastic Cerebellar Gangliocytoma (Lhermitte-Duclos Disease) with 7T MR Imaging ChristophMoenninghoff, MD, Oliver Kraff, MSc, Marc Schlamann, MD, Mark E. Ladd, PhD, ZazaKatsarava, MD,andElke R. Gizewski, Korean J Radiol. 2010 Mar-Apr; 11(2): 244–248. | 8. Dysplastic Cerebellar Gangliocytoma (Lhermitte-Duclos Disease) AtulB.Shinagare, MD, Nirupama K. Patil, MD,and S. Z. Sorte, MD,rsna radiology April 2009,Volume 251, Issue 1 | 9. Lhermitte–Duclos disease (dysplastic cerebellar gangliocytoma): a malformation, hamartoma or neoplasm?D. A. NowakandH. A. Trost,ActaNeurologicaScandinavica,Volume 105, Issue 3, pages 137–145, March 2002 | 10. Lhermitte-Duclos Disease: Assessment with MR Imaging, Positron Emission Tomography, Single-photon Emission CT, and MR Spectroscopy,JoachimKlischa, FreimutJuenglinga, Joachim Spreera, DonatusKocha, TorstenThiela, Martin Bücherta, Sebastian Arnolda, Friedrich Feuerhakea and Martin Schumachera,AJNR 2001 22: 824-830 |