Research Paper Medical science

Iatrogenic hydatid cutaneous fistulization in a patient with coexisting pulmonary tuberculosis

Dr. Kavita Chawla Asst Prof, Department of Physiology, MLN Medical College Allahabad

Dr. Vikas Sachdeva Prof, Department of Surgery, MLN Medical College, Allahabad

ABSTRACT

We report a very rare case of Pleural hydatid cyst in a known case of pulmonary tuberculosis which presented as discharging wound of the chest wall resulting due to intercostal drain insertion misdiagnosing it as tubercular effusion/empyema. This is a very unusual presentation of such cases. Patient was treated by thoracotomy with evacuation of the cyst. Patient recovered in four weeks time and was discharged with anti tuberculosis and anti-parasitic treatment. This case emphasizes the importance of suspicion in concomitant disease in endemic areas for echinococcosis and tuberculosis.

KEYWORDS Hydatid cyst, Tuberculosis, Thoracotomy

Introduction:
The most common causes of pulmonary tuberculosis and pleural hydatidosis are Mycobacterium tuberculosis and Echinococcus granulosis respectively [1]. Living in an endemic area like India is an important risk factor for these diseases. Pleural hydatid disease constitutes only 1% of the total incidence of hydatid disease [2]. Coexistence of these two diseases is even rarer. We report one such case where unintentional intercostal drain insertion in a pleural hydatid cyst led to the formation of a fistula draining clear liquid with cystic elements and white membranes.

Case History:
A 58-year-old female was admitted to our department with chest pain, fever, breathlessness, cough with expectoration and discharging wound in Left lower chest wall. The patient's history revealed that she was being treated for tuberculosis for past 6 months without significant improvement. Her past chest X-ray was suggestive of effusion in the pleural space (Fig.1a) for which an intercostal drain insertion was done. On further deterioration, the drain was removed and patient was referred to us. The physical examination revealed a small discharging wound in left lower chest wall draining clear liquid with cystic elements and white membranes (Fig.1b). Patient was in a toxic state with high grade fever, increased respiratory rate and heart rate. There was dullness on Left side with crepts and ronchi all over the chest. Patient was put on broad spectrum antibiotics, bronchodilators albendazole, antipyretics and her condition was stabilized. At surgery, the lesion was approached via a postero-lateral thoracotomy incorporating the fistulous site in the incision. The infected cyst with multiple daughter cysts was found in the pleural cavity (Fig.2). The wall of the cyst was intimately adhered to visceral and parietal pleura. The cyst was completely evacuated and was irrigated with hypertonic saline. The wall was removed as far as possible. This caused multiple air leaks which were repaired and a chest drain was put. Postoperatively, the anti-tuberculosis and anti-parasitic treatment was continued and the drain was removed after 4 weeks when the lung expanded and there was minimal discharge.

Discussion:
In countries like India which has a high prevalence of pulmonary tuberculosis and hydatid disease is endemic, a coexistence of these two diseases leads to diagnostic difficulties. The clinical manifestations of pleural hydatid cyst are not characteristic of the disease. It may present as hydropneumothorax, exudative effusion or empyema [3]. Tuberculous pleural effusion occurs in 30% of patients with tuberculosis [4]. The most common presenting symptoms are pleuritic chest pain (75%) and nonproductive cough (70%) [5]. In our case, the patient was a known case of tuberculosis and the radiological appearance of the hydatid cyst was similar to that of pleural effusion/empyema which was not responding to medical therapy so an intercostal drain insertion was done which led to the formation of a fistula from which daughter cysts and clear fluid was being discharged. Others have reported similar cases where pleural hydatid presented with massive pleural effusion [6].The definitive diagnosis of tubercular pleural effusions depends on the demonstration of acid-fast bacilli in the sputum, pleural fluid, or pleural biopsy specimens. It is difficult to make a diagnosis of pleural hydatidosis except by pleural biopsy or pleural fluid estimation for daughter cysts. Diagnosis is usually based on high degree of suspicion in endemic areas. Treatment of hydatid disease is essentially surgical [7]. Percutaneous aspiration/drainage of cyst is not recommended because of the risk of an allergic reaction like asthma or anaphylaxis and because of the danger of spread of disease by spillage of the cyst's contents [8].This case emphasizes the importance of considering the coexistence of echinococcosis and tuberculosis in endemic areas and adequate evaluation of the cases before any intervention is attempted.

Figure 1
(a) Chest X ray for which the drain was inserted;

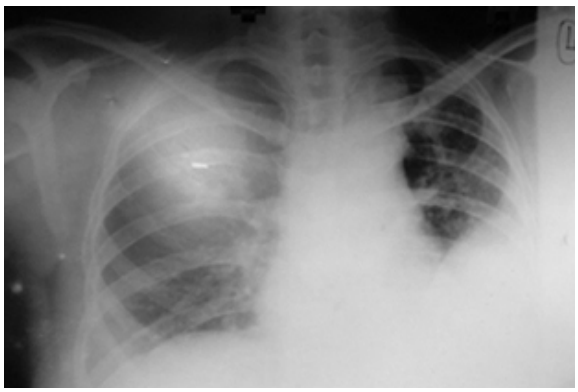

(b) Discharging sinus showing the daughter cysts

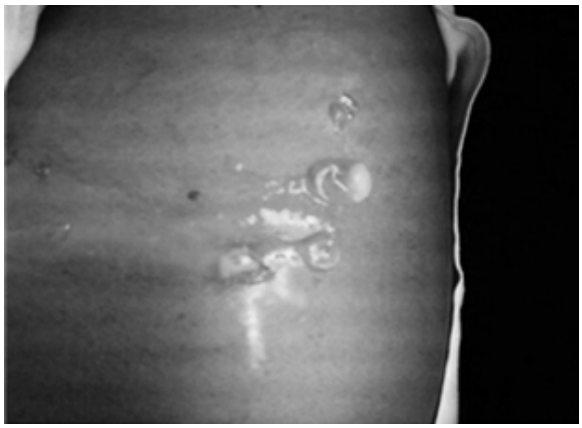

Figure 2
Per op Picture showing the cyst

REFERENCES

1. Chauhan MS, Rajan RS, Gopinathan VP, Jayaswal R. Pulmonary hydatid disease associated with pulmonary tuberculosis. Indian J Chest Dis Allied Sci.1986; 28: 88-91. | 2. Solak O, Esme H, Eser O, Aslan A, Fidan F, Solak O. Multiple pleural hydatid cysts associated with destruction of the vertebral column. Turkish respiratory journal 2006; 7: 134-136. | 3. Ozvaran MK, ErsoyY, Uskul B, Unver E, Yalcin E, Baran R, Morice RC. Pleural complications of pulmonary hydatid disease. Respirology 2004; 9: 115-119. | 4. Ferrer J. Pleural tuberculosis. Eur Respir J.1997; 10: 942-7. | 5. Berger HW, Meira E. Tuberculous pleurisy. Chest 1973; 63: 88-92. | 6. Vidyasagar B; Rao HLS; Indushekar S; Subba Rao H L Pulmonary hydatid simulating large pleural effusion : a case report Lung India.1989 Nov; 7(4): 198-200. | 7. Yalcinkaya I, ErM, Ozbay B, Ugras S. Surgical treatment of hydatid cyst of the lung: review of 30 cases. Eur Respir J 1999; 13: 441-444. | 8. Karawi MAA, Mohamed ARES, Tayeb BOE, Yasawy MI. Unintentional percutaneous aspiration of a pleural hydatid. Thorax 1991; 46: 859-860. |