Research Paper Medical Science

Orthodontic Treatment in Patient With Ectodermal Dysplasia and Cleft Lip and Palate.

Noemi Leiva	Orthodontist, Director Craniofacial Malformation Unit UMC, Faculty of Dentistry, University of Chile. Luis CalvoMackenna Hospital.
DaniellaVergara	Dental Surgery, Craniofacial Malformations Unit UMC, Faculty of Dentistry, University of Chile.
Paulina Sciaraffia	Dental Surgery, Craniofacial Malformations Unit UMC, Faculty of Dentistry, University of Chile.
Loreto Castellón	Maxillofacial surgeon. Luis CalvoMackenna Hospital.

ABSTRACT

Ectodermal dysplasia (ED) forms a large group of syndromes characterized by anomalies of ectodermal structures. It is a rare inherited disorder, with a characteristic physiognomy, affecting the development or function of the teeth, hair, nails and sweat glands, it involves a combination of different symptoms, which can range from mild to severe. There are described more than 200 types of ED, the most common form is the Hypohidrotic type and usually is inherited as a recessive X-linked trait. A case of a patient with hypodrotic ED and Cleft lip and palate is presented, the treatement included orthodontic and midface distraction osteogenesis using RED system (Rigid external distraction).

KEYWORDS Hypohidrotic ectodermal dysplasia, Cleft lip and palate, Orthodontic, Midface distraction osteogenesis.

INTRODUCTION

The term Ectodermal dysplasia (ED) is used to describe a heterogeneous group of disorders characterized by findings that imply a primary defect of skin, teeth and appendages structures including hair, nails, sebaceous glands and exocrine disorders[1]. It is a hereditary disorder happens as a result of disturbances in patterning the developing embryonic ectoderm [2,3].

When commit at least 2 of these ectodermal structures, the patient is diagnosed with ectodermal dysplasia syndrome [4].

Currently, ED represents a large and complex group of diseases comprising more than 200 different medical conditions[5,6]. In an attempt to classify different subgroups according to the presence or absence of the ED 4 primary defects are created[1]:

- ED1: Trichodysplasia (hair dysplasia).
- ED2: Dental dysplasia.
- ED3: Onychodysplasia (nails dysplasia).
- ED4: Dyshidrosis (sweat glands dysplasia).

In patients with ED the pubic and underarm hair is generally low, the hair on the scalp is often blond, thin, hard and short, while eyebrows and eyelashes are often absent or are white. The nails may be normal or spoon-shaped. In females, the mammary glands are hypoplastic or aplastic. It has been reported impaired function of the lacrimal gland and occasionally glaucoma. There may also be more susceptible to allergic disorders such as asthma or eczema. The absence of sweat glands results in a very smooth skin, but dry and thin and with hyperkeratosis in hands and feet. While oral manifestations may include anodontia, hypodontia, conical teeth and underdevelopment of the alveolar bone[7].

Thus, the more committed structures are nails, hair follicles, sweat glands and teeth, but can be associated manifestations such as psychomotor retardation, immunodeficiency, cleft lip and palatal and cranial abnormalities.[8].

Diagnosis is based on episodes of hyperpyrexia, lack or type of hair, absent teeth and tooth morphology. It have developed diagnostic criteria based on the number and distribution of sweat pores and the amount of sweat produced. Other diagnostic criteria are dermatoglyphic analysis, characteristics of tear secretion and distribution and pattern of scalp hair. The missing teeth is also an important sign[1].

This disease can be inherited by various genetic patterns including: autosomal dominant, autosomal recessive and X-linked (dominant or recessive)[9,10]. Also is possible a spontaneous genetic mutation (de novo) that can occur in any family with no history of this syndrome[1].

The prevalence in the population has been evaluated between 1:10,000 and 1:100,000 men live births [11], with a mortality rate of 28% in men aged up to 3 years old[4].

Of the 200 different ED entities, has been identified the causative gene in approximately 30. Most cases of ED are caused by mutations in only 4 genes[12,13,14]:

- EDA1: Reported in patients with X-linked form, encoding the A1 ectodysplasin isoform protein, which belongs to the family of tumor necrosis factor (TNF).
- WWTP: Reported in patients with autosomal dominant and in some cases with autosomal recessive inheritance, encoding the receptor ectodysplasin-A1.
- EDARADD: Causing both autosomal forms, dominant or recessive, which acts as intracytoplasmic EDAR receptor modulator.
- WNT10A: Member of the Wnt signaling pathway, involved in embryonic development and cell differentiation as well as certain physiological processes in adult and cancer, and give rise to several forms of autosomal inheritance, as hypohydrotic ectodermal dysplasia or dental-nail-dermal dysplasia.

Therefore, the signaling pathway mediated by the EDA is essential for proper development of various organs and structures derived from the ectoderm, such as hair, nails, pituitary gland, mammary and sweat glands, nose, eyes and tooth enamel.

There are two main types of this condition depending on the number and function of the sweat glands:

1) Hidrotic ED (Clouston syndrome): where the sweat glands are normal and is inherited in an autosomal dominant manner.
2) Hypohidrotic or Anhidrotic ED (Christ-Siemens-Touraine syndrome), where the sweat glands are absent or significantly reduced number, presents X-linked inheritance. Depending on the severity of the clinical manifestations, the ED can be classified as Hypohidrotic (decrease of sweat glands) or Anhidrotic (lack of sweat glands)[4,15].

Hypohidrotic Ectodermal Dysplasia (HED)

Is the most common form of ED, it affects men more severely, whereas heterozygous females show varying severity, ranging from mild to severe, due to inactivation of the X chromosome [16].

The HEDhas characteristic triad of reduction in the amount of hair (hypotrichosis), absence of sebaceous glands (asteatosis), and absence of sweat glands (anhidrosis)[1,15].

Other classic signs are periorbital wrinkles, frontal bossing, prominent supraorbital ridges, saddle nose (depressed nasal bridge), prominent chin, protruding lips, sunken cheeks and wrinkled, hyperpigmented skin around the eyes and hyperkeratosis of palms and soles of the feet. Further, such as chronic rhinitis, pharyngitis, laryngitis, and developmental disorders can, in some cases, anomalies accompany the above symptoms[6,16].

Oral manifestations may include hypodontia or anodontia both primary and permanent teeth and anomaly tooth shape associated (conical and smaller teeth); Sweeney et al[17]pointed out that the permanent teeth most likely to be present in the maxillar are central incisors, followed by the first molars and canines, while in the jaw, canines, first premolars and first molars, are most frequently to be found.

This patients also present dysmorphic roots and crowns (mainly conical incisors and canines and molars with crowns abnormally), diastemas, delayed eruption of permanent teeth, underdeveloped alveolar bone and even cleft palate. As a result of hypodontia and lack of alveolar ridge, the vertical dimension of the face is reduced by a decrease in the lower third. Moreover, within oral manifestations may occur salivary glands hypoplasia and absence of accessory glands resulting in xerostomia and dry lips and / or chapped.[1,6,16,18].

ED patients suffering of little psychological and physiological development as a result of an unusual aesthetic and abnormal functions of orofacial structures. Therefore, early treatment is suggested, that requires multidisciplinary collaboration efforts of pediatric professionals, psychologists, otolaryngologists, speech therapists, dentists and oral rehabilitation, with the responsibility of rehabilitating these patients to improve dental aesthetics and chewing. Dental treatment depends on the severity of the condition, therefore, this will vary according to the age, growth and development of the stomatognathic system of the patient and its main objective is to give the child a treatment offering optimum aesthetics and function, so that the patient can physically, emotionally and socially developed[1].

CASE REPORT

A 12-day-old male infant with no family history related to this anomaly, diagnosed with ectrodactyly - ectodermal dysplasia - cleft lip/palate syndrome(ECC) was admitted to the Surgery Departmentof Salvador Hospital, Chile. A year later he underwent surgical closure lip and palate.Later he underwent several surgeries due to syndactyly of hands and feet, gastroesophageal reflux (Laparoscopic NISSEN), hypospadias - neurogenic bladder (vesicostomy), urethral meatus stenosis (urethroplasty), left lacrimal duct obstruction (lacrimal permeation).

Other manifestations presents in the patient are: hearing loss, ophthalmologic problems, anodontia, microdontia.

At 8 years old the patient presents early eruption of right and left canines and gingival discontinuity, so a bone graft is made in the left maxilla. (Fig. 1)

According to the analysis of the case and the severe lack of development of the middle third facial, it was decided to perform midface distraction osteogenesis with rigid external distractor device (RED).(Fig.1)

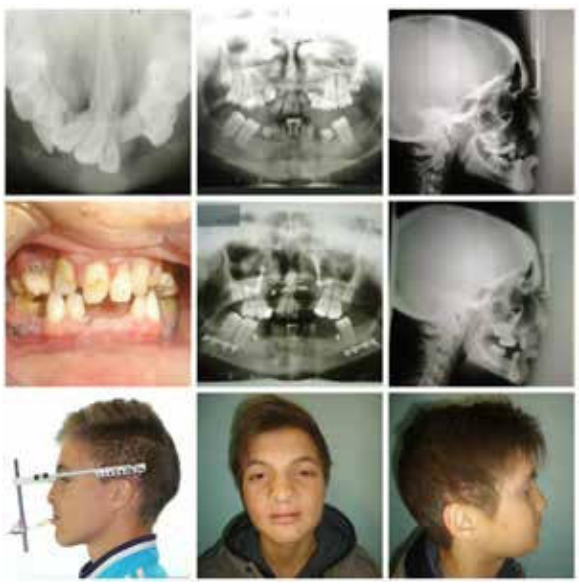

Fig. 1: From left to right: occlusal radiograph after bone graft.Pre-treatment panoramic radiography, teleradiography prior to surgery. Image with rigid external distractor (RED). Post-treatment photographs.

DISCUSSION

The ED corresponds to a large group of syndromes, there are described under this term about 200 different conditions[6,18]. Patients with ED have variety in relation to clinical and genetic aspects and are characterized by abnormalities of the ectodermal structures. They can manifest in problems with hair, nails, teeth, sweat glands and sebaceous glands, they may or may not be associated with alterations in other ectodermal appendices[3,6,18].

The HED is a disease X-linked and is the most common form of ED. In this syndrome, there is no sweat glands or are decreased significantly[9].

Recent advances in molecular and biochemical methods have enabled the classification of the genes causing ED into four major functional subgroups: cell–cell communication and signaling, adhesion, transcription regulation, and development. Despite the great number of ED cases described so far, fewer than 30 have been explained at the molecular level with identification of the causative gene. These findings provide clinicians with the opportunity to redefine ED, not simply as a result of general abnormal ectodermal development but, more precisely, as systemic pathologic conditions. However, these

methods are not readily available for a routine clinical diagnosis of ED[7].

Children with craniofacial and birth defects are unique and oral problems must be evaluated individually to provide the most suitable treatment. This results in a significant improvement in aesthetics, masticatory and phonetic function. In addition, the positive psychological impact on the child and their parents and relatives should be taken into account[1].

In many cases of ED, the most common oral characteristic is hypodontia or anodontia. In these cases, the advantages of existing teeth with regard to retention, stability,function, and the phonetics of the denture should be considered. In addition, existing teeth help protect the proprioception mechanism and prevent the formation of residual alveolar ridges[20]

REFERENCES

1. Deshmukh S, Prashanth S. Ectodermal dysplasia: a genetic review. Int J Clin Pediatr Dent. 2012 Sep;5(3):197-202. doi: 10.5005/jp-journals-10005-1165. Epub 2012 Dec 5. | 2. Lesot H, Clauss F, Manière MC, et al. Consequences of X-linked hypohidrotic ectodermal dysplasia for the human jaw bone. Front Oral Biol. 2009; 13: 93-9. | 3. Ramesh K, Vinola D, John JB. Hypohidrotic ectodermal dysplasia - diagnostic aids and a report of 5 cases. J Indian Soc Pedod Prev Dent. 2010 Jan-Mar;28(1):47-54. doi: 10.4103/0970-4388.60474. | 4. Bani M., Tezkirecioglu AM., Akal N., et al. Ectodermal dysplasia with anodontia: a report of two cases. Eur J Dent. 2010 Apr;4(2):215-22. | 5. Vieira KA, Teixeira MS, Guirado CG., et al. Prosthodontic treatment of hypohidrotic ectodermal dysplasia with complete anodontia: case report. Quintessence Int. 2007; 38: 75-80. | 6. Carvalho M, Romero Souto de Sousa J, Paiva Correa de Melo F, et al. Hypohidrotic and hidrotic ectodermal dysplasia: a report of two cases. Vasconcelos Dermatol Online J. 2013 Jul 14;19(7):18985. | 7. Baskan Z, Yavuz I, Ulku I, et al. Evaluation of ectodermal displasia. Department of Orthodontics, Faculty of Dentistry, Dicle University, Diyarbakir, Turkey. Med Sci 2006;22:171–6. | 8. Araníbar D., Ligia, Lay-Son R., Guillermo, Sanz C., Patricia, & Castillo T., Silvia. Displasia Ectodérmica hipohidrótica, caso clínico y revisión de la literatura. (2005). Revista chilena de pediatría, 76(2), 166-172. | 9. Kishore M, Panat SR, Aggarwal A, et al. Hypohidrotic Ectodermal Dysplasia (ED): A Case Series. J Clin Diagn Res. 2014 Jan;8(1):273-5. doi: 10.7860/JCDR/2014/6597.3951. Epub 2014 Jan 12. | 10. Lamartine J. Towards a new classification of ectodermal dysplasias. Clin Exp Dermatol. 2003 Jul;28(4):351-5. | 11. Kupietzky A, Houpt M. Hypohidrotic ectodermal dysplasia: Characteristics and treatment. Quintessence Int 1995 Apr;26(4):285-291. | 12. Cluzeau C, Hadj-Rabia S, Jambou M, et al. Only four genes (EDA1, EDAR, EDARADD, and WNT10A) account for 90% of hypohidrotic/anhidrotic ectodermal dysplasia cases. Hum Mutat. 2011 Jan;32(1):70-2. doi: 10.1002/humu.21384. | 13. Habib R, Ansar M, Mattheisen M, et al. A Novel Locus for Ectodermal Dysplasia of Hair, Nail and Skin Pigmentation Anomalies Maps to Chromosome 18p11.32-p11.31. PLoS One. 2015 Jun 26;10(6) | 14. García-Martín P, Hernández-Martín A, Torrelo A. Ectodermal dysplasias: a clinical and molecular review. Actas Dermosifiliogr. 2013 Jul-Aug;104(6):451-70. doi: 10.1016/j.ad.2012.07.012. Epub 2012 Oct 26. | 15. Mokhtari S, Mokhtari S, Lotfi A. Christ-siemens-touraine syndrome: a case report and review of the literature. Case Rep Dent. 2012;2012:586418. doi: 10.1155/2012/586418. Epub 2012 Nov 29. | 16. Lexner MO, Bardow A, Hertz JM, et al. Anomalies of tooth formation in hypohidrotic ectodermal dysplasia. Int J Paediatr Dent. 2007 Jan;17(1):10-8. | 17. Sweeney IP, Ferguson JW, Heggie AA, et al. Treatment outcomes for adolescent ectodermal dysplasia patients treated with dental implants. Int J Paediatr Dent. 2005 Jul;15(4):241-8. | 18. Van Sickels JE, Raybould TP, Hicks EP. Interdisciplinary management of patients with ectodermal dysplasia J Oral Implantol. 2010;36(3):239-45. doi: 10.1563/AAID-JOI-D-09-00043R1. | 19. Dall'Oca S, Ceppi E, Pompa G, Polimeni A: X-linked hypohidrotic ectodermal Dysplasia: A tem-year case report and clinical considerations. Eur J Ped Dent 2008;9:14-8. [PMID: 19886367] | 20. Yenisey M, 55%Guler A, 55%Unal U. Orthodontic and prosthodontic treatment of ectodermal dysplasia--a case report. Br Dent J. 2004 Jun 12;196(11):677-9. |