



Video Endoscopic Inguinal Lymphadenectomy (Veil) : Experience From A Single Institute Study

Dr S P Dhangar

Department of Urology, Bharti Hospital and Research Center, Pune - 411043, Maharashtra, India

Dr Ibrahim Kothawala

Department of Urology, Bharti Hospital and Research Center, Pune - 411043, Maharashtra, India

Dr Abhay Kumar

Department of Urology, Bharti Hospital and Research Center, Pune - 411043, Maharashtra, India

Dr Renuka Chowdary

Department of Surgery, Bharti Hospital and Research Center, Pune - 411043, Maharashtra, India

Dr D K Jain

Department of Urology, Bharti Hospital and Research Center, Pune - 411043, Maharashtra, India

ABSTRACT

VEIL is a new and attractive approach, duplicating the standard open procedure. It reduces post-operative discomfort, allowing a faster recovery and decreased overall morbidity. We present our initial experience with this technique and discuss the procedure and its complications. We included total 6 procedures with penile carcinoma, moderate to high grade with no palpable inguinal lymph nodes who were at high risk for inguinal metastases and were subjected to elective VEIL. We noted no cutaneous complication, localised lymphocele in two patients, surgical emphysema in one patient. There was decreased overall morbidity and no mortality. VEIL is a promising minimally invasive approach for radical inguinal dissection in penile cancer patients with non-palpable or low-volume palpable inguinal disease. Newer studies with more number of patients and long term follow up may confirm the oncological safety and possible lower morbidity of this novel approach.

KEYWORDS

VEIL, inguinal lymphadenectomy, laparoscopic inguinal lymphadenectomy, carcinoma penis

INTRODUCTION : The presence and extent of metastasis in inguinal lymph nodes are the most important prognostic factors in carcinoma of penis. Inguinal metastases are one of the major determinants of mortality in patients with penile cancer. The biology of penile cancer is such that it exhibits a long loco-regional phase before distant metastasis occurs, providing a rational for therapeutic lymphadenectomy. Elective inguinal lymphadenectomy may offer survival advantage over watchful waiting in high risk patients. Elective inguinal lymphadenectomy is the standard of care for patients with larger tumour size, high histological grade and the presence of lympho-vascular invasion [1,2,3]. Open surgery, however, causes morbidity in the form of skin loss, wound infection, large skin necrosis, etc. [4]. VEIL is an endoscopic procedure, and a new and attractive approach, duplicating the standard open procedure. It reduces post-operative discomfort, allowing a faster recovery and decreased overall morbidity [5]. We present our initial experience with this technique and discuss the procedure and its complications.

MATERIAL AND METHODS : This study was carried out at Bharti Hospital and Research Center, Pune, Maharashtra. 4 patients and 6 units (total 6 procedures) with penile carcinoma, moderate to high grade and /or locally advanced with no palpable inguinal lymph nodes who were at high risk for inguinal metastases were subjected to elective VEIL. The mean age of the patients was 54.7 years (range 46 – 70years). Three patients had T2N0M0 disease and partial penectomy was done in these 3 patients. One patient had T1aN1M0 disease and total penectomy was done in this patient. In this patient with palpable node, the node remained enlarged in spite of antibiotic for one month. In all patients the tumour was moderately differentiated. VEIL was done in standard surgical steps. Peri-

operative parameters were assessed.

Consent

Written informed consent was obtained from all the patients for publication of this report and any accompanying images.

Surgical technique and steps of VEIL :

All patients were thoroughly investigated pre-operatively and optimised. All were given pre-operative antibiotics one hour before starting the procedure. The aim of our approach was to remove all the inguinal lymph nodes. All patients were given epidural block anaesthesia.

Step 1. Surface marking : markings were done for femoral triangle, inguinal ligament, anterior superior iliac spine and sapheno-femoral junction. (figure 1)

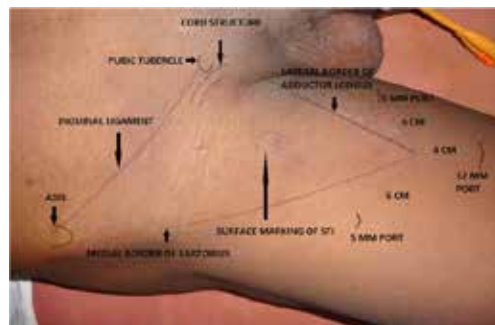


Figure 1. Surface Markings

Step 2. Patient positioning : The lower limb was folded at knee and thigh externally rotated to make the femoral triangle more prominent. It was fixed to the table. The video monitor was positioned at the contralateral side at the patient's pelvic waist.

Step 3. Port placement and gas insufflation : An incision of 1.5 cm in the skin and in the subcutaneous tissue was made 2 cm distal to the femoral triangle vertex. A plane developed deep to Scarpa's fascia with trocar and balloon dilatation. 30 degree camera was introduced through this 10mm port and CO2 gas insufflated at 14mmHg to make the space. Further 10mm and 5mm ports were made under vision. Second port was made with a 1cm incision at around 2 cm above and 6 cm medially to the first incision, to introduce a 10 mm port. A third 5mm incision for 5mm port made laterally in symmetrical position on the opposite side for using graspers, scissors etc .(Figure 2.)

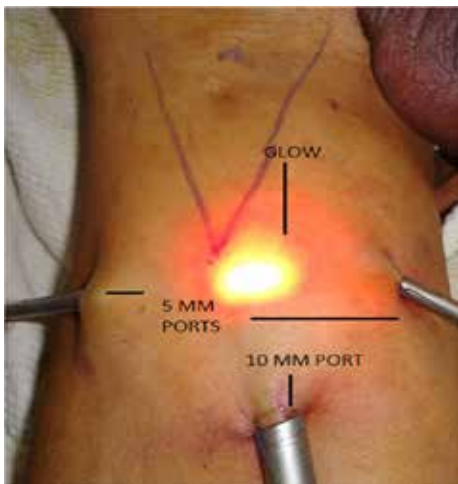


Figure2. Port placement sites

Step 4. Dissection and identification of landmarks : The dissection was carried out deep to the Scarpa's fascia and superiorly. The main landmarks of dissection were medially the adductor longus muscle, laterally - the sartorius muscle, superiorly - the external oblique aponeurosis and inguinal ligament, and the inferior margin was the apex of the femoral triangle. Transillumination, external pressure on skin by palpation and surface markings allow good orientation and monitoring of the progression of the dissection. The dissection was done with help of harmonic scalpel in all cases.

Step 5. Identification of the important structures : The saphenous vein was identified medially and the external oblique aponeurosis and inguinal ligament were dissected superomedially. The identified saphenous vein was dissected cranially up to the fossa ovalis. We did not divide saphenous vein in four out of six units.(figure 3)

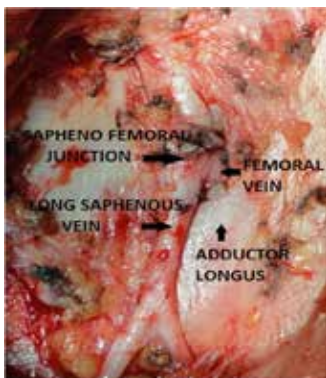

Figure 3. After intra-operative dissection is done, **important structures** are identified

Step 6. Dissection was started initially at the vertex of the femoral triangle. All the fatty and lymphatic tissue above the fascia covering the muscle were dissected. It was carried superiorly along the saphenous vein till femoral vessels were reached. The tributaries of saphenous vein were identified and ligated with the help of harmonic and vascular clips.

Step 7. The femoral artery was identified at femoral triangle, at which point the fascia over the muscle was opened in all directions.

Step 8. The dissection was completed and specimen consisted of all the fibro-fatty tissue with deep and superficial inguinal lymph nodes. The specimen was taken out through the 10 port. Incision was extended for larger specimen and retrieval bag was used for specimen removal.

Step 9. Suction drain was placed through the lateral port and port incisions were closed.

Step 10. Compression dressing was applied. Elastic compression bandage was applied on the side of surgery. Catheter was kept for two days in all patients for urinary drainage. Early mobilisation of the patient was done.

RESULTS : No intra-operative complication occurred. Operative time for VEIL was 200 to 240 minutes. Total operative time was initially longer but reduced in subsequent procedures. Lymph node yield was 8 to 19 lymph nodes. We noted no cutaneous complication, localised lymphocoele in two (which were needle aspirated and were not seen after two aspirations), surgical emphysema in one (managed conservatively). Positive inguinal lymph nodes on histopathology were seen in one patient for which he underwent laparoscopic bilateral pelvic lymphadenectomy. HPE of pelvic lymph nodes came out to be negative subsequently. There was decreased overall morbidity, despite the small number of patients. (Table 1)

Table 1. Outcome of patients with squamous cell carcinoma of the penis who underwent VEIL

SN of patients	Duration of surgery (in minutes)	Skin-related complications	Lymph-related complications	Drain removal (in days)	Lymph node yield	Self-resolving surgical emphysema	Histopathology of lymph nodes (positive/negative for malignancy)
1	240	No	No	14	12	Negative	Negative
2	220	No	No	14	10	Negative	Negative
3	210	No	Lymphocoele	22	9	Positive	Negative
4	220	No	Lymphocoele	14	11	Negative	Negative
5	200	No	No	14	19	Negative	Negative
6	200	No	No	18	8	Negative	Positive

DISCUSSION : Approximately 30% of the patients with penile carcinoma present with inguinal lymph node metastasis at the time of presentation/diagnosis[6]. Identification of this high risk group is important for proper staging and treatment to improve the survival. Inguinal lymphadenectomy is accepted for its prognostic and therapeutic value in cases of penile carcinoma with high risk of developing metastasis [5]. Conventional open inguinal lymphadenectomy can have significant morbidity [7]. Recent series however shows that the morbidity of inguinal lymphadenectomy has decreased, with Bouchot et al [8] reporting 12% overall complication rate. Even today, many centres have higher complication rates with significant operative morbidity, even in the most experienced hands for open inguinal lymphadenectomy [6,7,8]. Minor complications

(superficial wound dehiscence, mild oedema, seroma) can occur in up to two-thirds of patients, while major complications (flap necrosis, deep vein thrombosis, lymphocele requiring drainage) occur in one third[6,7,8]. Inguinal lymphadenectomy was modified to minimise the complication of open surgery by 1) using thick skin flaps based on the blood supply superficial to Scarpa's fascia, 2) dissecting medial to the course of the femoral nerve, 3) smaller skin incisions, 4) preservation of the saphenous vein, and 5) by transposition of the sartorius muscle [9]. Despite these modifications, 36% minor complication rates, deep vein thrombosis, and even myocardial infarction have been reported [6,8]. These results have encouraged search for reducing the morbidity of inguinal lymphadenectomy by using minimally invasive endoscopic techniques.

The VEIL technique was described by Tobias-Machado et al. in 2006[5] with an aim to duplicate the standard radical procedure with less morbidity. By using VEIL, we were able to identify the same landmarks as in the open surgery and perform a dissection same as in the radical surgery. We can remove all the lymphatic tissue within the limits of dissection same as open surgery. We were able to perform complete inguinal lymph node dissection in all our patients with this technique. We had 3 patients with clinically negative groins but T2 disease and one patient with N1 disease. In this patient with palpable inguinal lymph node the dissection was done with difficulty. Bishoff et al also reported difficult dissection of palpable disease in one patient[10]. Laproscopic bilateral pelvic lymph node dissection was required in this patient as nodes were positive on histopathology in the clinically N1 lymph nodes. These pelvic lymph nodes came out to be negative subsequently.

We preserved saphenous vein in 4 units. Saphenous vein can be preserved as some authors claim that it may reduce post-operative oedema [11,12,13,14].

Published cases have reported an overall wound complication rate of 19-51% and a wound dehiscence rate of 7-44% in open inguinal lymph node dissection[15]. Complications with VEIL are fewer compared to an open surgical procedure, and this technique has reduced post-operative morbidity. The most important advantage of VEIL was a decrease in skin events in our experience with no skin related complications. Suarez et al reported 0% cutaneous morbidity and 30% lymphatic morbidity[16]. Tobias-Machado et al. reported 5% cutaneous and 10% lymphatic morbidity[16], whereas Sotelo et al. reported 0% cutaneous and 23% lymphatic morbidity in their study[16]. Similar experience has been reported from other studies[17]. With VEIL the drains can be removed early and patients can be discharged earlier[12]. In our cases the drains were removed in minimum 14 days as there was increased discharge in the drains and patients were discharged on third post-operative day with the drains. Operative time of VEIL was longer than with the conventional open surgery, but the time decreased significantly as our experience increased. As the incisions are small in VEIL, sub-cutaneous sutures can be completed with a better aesthetic outcome. Master et al. reported their experience with 25 leg dissections performed endoscopically[18]. They performed complete inguino-femoral lymphadenectomy (the LEG procedure) and stated that this procedure required operating time comparable to open procedures and carried less morbidity.

There are few reports in the literature of robotic-assisted video endoscopic inguinal node dissection. Josephson et al. in 2009[19] performed endoscopic robotic-assisted inguinal lymph node dissection in a patient with penile cancer. Dogra P N et al. published their experience with two cases of robotic-assisted inguinal node dissection in patients with carcinoma of the penis in 2011[20].

New studies with a greater number of patients and long-term follow-up are needed to test the hypothesis that VEIL can retain the long-term oncological efficacy of the standard surgery and result in a lower morbidity. If this holds true, VEIL can become an attractive choice for the prophylactic inguinal lymphadenectomy in penile cancer patients. Other possible clinical

indications for this new procedure may include prophylactic dissection for urethral and vulval cancers.

CONCLUSION : In our initial experience, VEIL is a safe, feasible and promising technique in patients with penile carcinoma and non-palpable inguinal lymph nodes. It allows the removal of inguinal lymph nodes within the same limits as in the conventional inguinal lymphadenectomy and significantly reduces surgical morbidity. VEIL is a promising minimally invasive approach for radical inguinal dissection in penile cancer patients with non-palpable or low-volume palpable inguinal disease. Newer studies with more number of patients and long term follow up may confirm the oncological safety and possible lower morbidity of this novel approach.

FINANCIAL SUPPORT AND SPONSORSHIP: Nil

CONFLICTS OF INTEREST: None

BIBLIOGRAPHY

- Misra S, Chaturvedi A, Misra NC: Penile carcinoma: a challenge for the developing world. *Lancet Oncol* 2004, 5:240-247.
- Marquis V, Saqalowsky AI: Penile cancer: management of regional lymphatic drainage. *Urol Clin North Am* 2010, 37:411-419.
- Slaton JW, Morgenstern N, Levy DA, Santos MW Jr, Tamboli P, Ro JY, Ayalá AG, Pettaway CA: Tumor stage, vascular invasion and the percentage of poorly differentiated cancer: independent prognosticators for inguinal lymph node metastasis in penile squamous cancer. *J Urol* 2001, 165:1138-1142.
- Ravi R: Correlation between the extent of nodal involvement and survival following groin dissection for carcinoma of the penis. *Brit J Urol* 1993, 72:817-819.
- Tobias-Machado M, Alessandro T, Molina WR Jr, Forseto PH Jr, Juliano RV, Wroclawski ER: Video Endoscopic Inguinal Lymphadenectomy (VEIL): Minimally Invasive Resection of Inguinal Lymph Nodes. *Int Braz J Urol* 2006, 32:316-321.
- Bevan-Thomas R, Slaton JW, Pettaway CA: Contemporary morbidity from lymphadenectomy for penile squamous cell carcinoma: the M.D. Anderson Cancer Center Experience. *J Urol* 2002; 167: 1638-42.
- Protzel C, Alcaraz A, Horenblas S, Pizzocaro G, Zlotta A, Hakenberg OW. Lymphadenectomy in the surgical management of penile cancer. *Eur Urol* 2009;55:1075-88.
- Bouchot O, Rigaud J, Maillat F, Hetet JF, Karam G. Morbidity of inguinal lymphadenectomy for invasive penile carcinoma. *Eur Urol* 2004;45:761-6.
- Catalona WJ. Modified inguinal lymphadenectomy for carcinoma of the penis with preservation of saphenous veins: technique and preliminary results. *J Urol* 1988;140:306-10.
- Bishoff JT, Basler JW, Teichman JM, Thompson IM: Endoscopic subcutaneous modified inguinal lymph node dissection (ESML) for squamous cell carcinoma of the penis. *J Urol* 2003;169:78.
- Catalona WJ. Modified inguinal lymphadenectomy for carcinoma of the penis with preservation of saphenous veins: technique and preliminary results. *J Urol* 1988;140:306-10.
- d'Ancona CA, de Lucena RG, Querne FA, Martins MH, Denardi F, Netto NR Jr. Long-term follow-up of penile carcinoma treated with penectomy and bilateral modified inguinal lymphadenectomy. *J Urol* 2004;72:498-501.
- Tobias-Machado M, Tavares A, Molina Jr WR, Starling ES, Juliano RV, Wroclawski ER. Video endoscopic inguinal lymphadenectomy (VEIL) with saphenous vein preservation: demonstration of feasibility (video). *J Endourol* 2007;21:1.
- Sotelo R, Sánchez-Salas R, Carmona O, Garcia A, Mariano M, Neiva G, et al. Endoscopic lymphadenectomy for penile carcinoma. *J Endourol* 2007;21:364-7.
- Canter DJ, Dobbs RW, Jafrisma, Herrel LA, Ogan K, Delman KA, Master VA. Functional , oncologic, and technical outcomes after groin dissection for penile carcinoma. *Can J Urol* 2012;19(4):6395-6400.
- Walter F Correa1 and Marcos Tobias-Machado2 Video-endoscopic Inguinal Lymphadenectomy. *European Oncology*, 2010;6(2):80-4
- Thyaviahally Y, Tongaonkar H, Video Endoscopic Inguinal Lymphadenectomy (VEIL): our initial experience, *J Urol*, 2009;72:181(4):427.
- Master V, Ogan K, Delman K, Kooby D. Hsiao W: Leg Endoscopic Groin Lymphadenectomy (LEG Procedure): Step-by-Step Approach to a straightforward Technique. *Eur Urol* 2009, 56(5):821-828.
- Josephson DY, Jacobsohn KM, Link BA, Wilson TG: Robotic-assisted endoscopic inguinal lymphadenectomy. *Urology* 2009, 73(1):167-170
- Dogra PN, Saini AK, Singh P: Robotic-assisted inguinal lymph node dissection: a preliminary report. *Indian J Urol* 2011, 27(3):424-427.