



Assessment of Conservative Treatment of Greenstick Fractures in Forearm Bones in Children

Dr. Pankaj Sharma	M.S.orthopedics, Department of orthopedics, V.S.Hospital
Dr. Tarkik Amin	M.S.orthopedics, Assistant Professor, Department of orthopedics, V.S.Hospital

ABSTRACT

Forearm fracture in children are common mostly because of fall and are assessed in this study with conservative treatment. **MATERIALS AND METHODS:** We have treated 35 cases. Patients pre and post reduction serial follow up x-rays were studied. **CONCLUSION:** Remodeling and returning of final range of motion is excellent using conservative treatment with reduction with serial follow up

KEYWORDS

INTRODUCTION

Incidence of fractures of forearm bones is 3% to 6% of all fractures in children.

Greenstick Fracture is defined as a type of fracture where the bone bends and partially breaks. Greenstick fracture usually occurs during infancy and childhood when bones are soft. This fracture was described by John Insall, a British-American orthopedist and Michal Slupecki, a Polish-American orthopedist. They described the fracture like that of a breakage of green wood, which simply breaks outside when bent.

Angulated greenstick fractures of the shaft of the radius and ulna at different levels indicate a significant rotational component to injury. Evans, Rang and others have stated that the apex-volar angulation pattern usually is associated with a supination type injury mechanism, while most apex-dorsal angulation greenstick fracture involve a pronation type injury mechanism.

The objective of treatment in greenstick fracture is to correct angular deformity by simply reversing the forearm rotational forces (reducing an apex-dorsal pronation type injury with supination).

Material and Method

We have treated 35 cases in our institute. There were 23 male child and 12 female child. Patients pre and post reduction serial follow up x-rays were studied. Follow up period ranges from 3 months to 2½ year.

Treatment Protocol

Primary Treatment:

• General Treatment:

General condition of the patient was assessed and other associated injuries were noted.

• Local Care:

Neurovascular status of the extremity was assessed. If any wound was present, it was examined and then it was covered with sterile dressing.

• X Ray and Splintage:

After general and local examination, anteroposterior and lateral x ray of injured forearm done which include both wrist and elbow then above elbow splint was given to involved limb.

• Definite Treatment:

Close reduction was done under general anesthesia and IITV control.

- In greenstick fracture reduction done according to Angulation of fracture. When the apex of fracture is towards dorsum of forearm (apex dorsal- pronation injury), the forearm is supinated to achieve reduction. When apex of fracture towards the volar aspect of forearm (apex volar-supination injury), A plaster was given in pronation.
- Post reduction check X-ray was taken and patient was kept under observation with elevation of limb for 2 days, if there was oedema and stretch pain at extension of finger, Plaster slit from ulnar border and simple bandage was applied over it. If there was no oedema or circulatory disturbance patient was discharge after 2 days. And patient was advised to come after 1 week to check plaster condition and oedema or if any problem patient was asked to come at any time.

Reduction Criteria:

In our study we have accepted up to <15° angulation of either or both bones. Angulation

>15° was not acceptable.

Follow up :

After 1 week:

- Check for oedema
- Check for plaster (broken or not)
- If fracture has tendency to displace then check x ray.

If there was oedema, slit plaster from ulnar border and if there was no oedema then follow up after 2 weeks. If plaster was broken then strengthen it.

After 3 weeks :

If plaster is given in supination or pronation then it is removed and given in neutral position and patient is asked to come for follow up after 2-3 weeks to remove plaster.

After 6 Weeks:

Plaster was removed and patient was checked clinically and radiologically.

- Check x ray for union.
- Check range of motion at elbow and wrist.

Final follow up:

- Check x ray for remodeling.
- Check range of motion.

RESULTS AND DISCUSSION

In our study we have taken 35 cases of Greenstick fracture of forearm bones, In which there were 23 male & 12 female with age between 3-13 year, High incidence of Greenstick Fracture of forearm were found in age group 5-10 year.

Highest incidence of forearm fractures is found in age group of 5-10 years.

Female(34%) are less involve than male.

In present series both bone(54%) involved more than isolated bone.

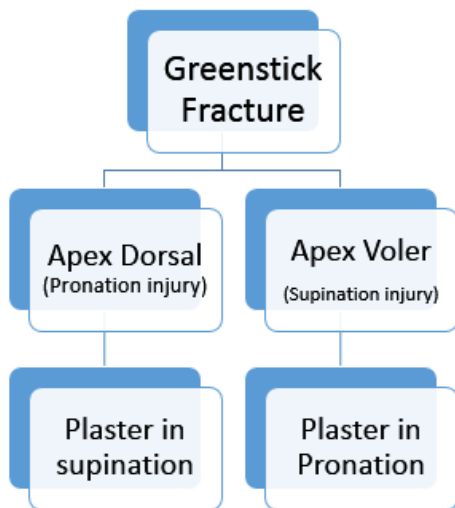
Volar angulation(85%) is more common than dorsal.

In present series lower 1/4th level is more common.

Left Upper Limb(68%) more involved in present series.

Most common injury is occurred by fall. In 74% cases this was the cause. In 25% the cause was accident.

Types of plaster



Displacement of fracture at 6 Week :

	No. of Patients
Alexander VAN Tongel, Pieter, Bart Series	7(33%)
Present Series	9(25%)

Pronation is more affected than supination. 17% Patients has 10° loss of pronation in over study while one patients has restriction of supination

(Short term follow up of 2 months)

Average period of immobilization is 6 weeks

In present series the highest degree of correction in radius is 18° & in Ulna is 13°. In Alexander VAN Tongel, Pieter, Bart Series the highest degree of correction in radius is 15°.

In our study 74% has excellent result, 22% has good result & 1% has fare result. None of has poor result.

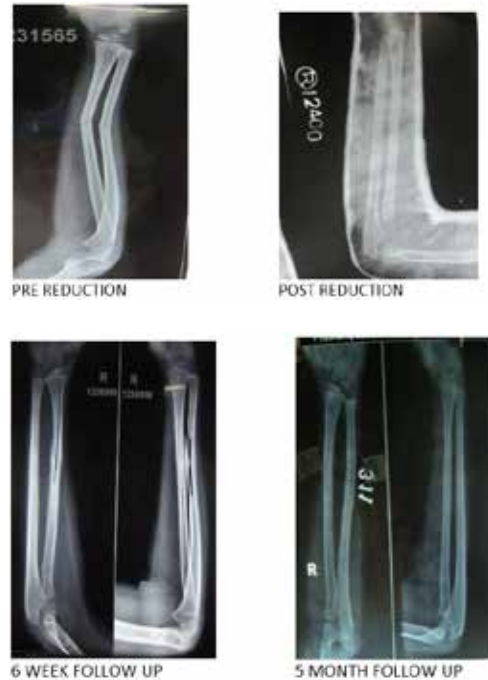According to Evans in greenstick fractures the bones are often broken at different levels and the radius angulated more than the Ulna. This would indicate that a rotation force has been acting. In pronation & supination the radius moves around the static ulna and if it is fractured while rotating, its deformity would naturally be greater.

CONCLUSION

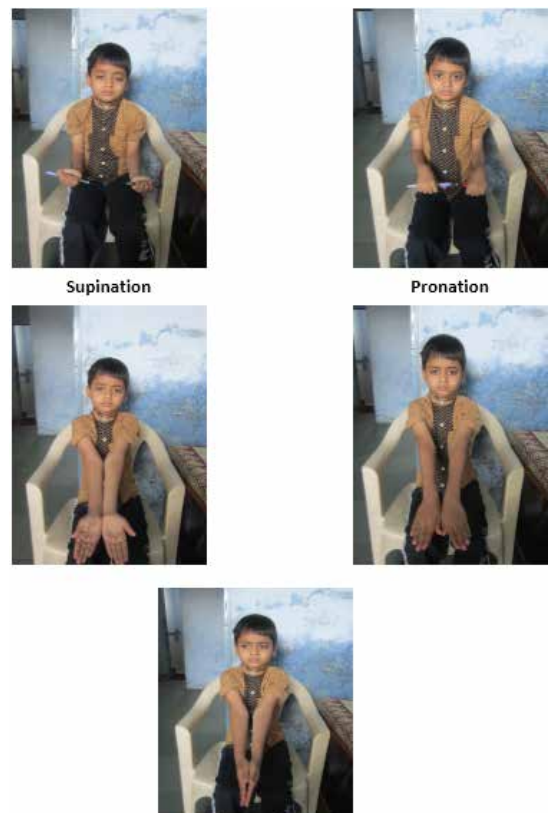
- 35 Cases of greenstick fracture forearm bones are studied.
- Maximum fractures were in age group of 5-10 year with predominance in males.

- Most of the fractures were on subordinate side.
- Average union time in greenstick fracture was 6 week.
- In this series the highest degree of angulation (at final follow up) which got corrected was in radius 18° and in ulna 13°.
- There is rare incidence of slitting plaster.
- Remodeling and returning of final range of motion is excellent.

CLINICAL CASE



Functional Results : Excellent



REFERENCES

1. Angulated greenstick fractures of the forearm in children :
2. Closed reduction by pronation or supination. Alexander VAN TONGEL, Pieter ACKERMAN, Koen LIEKEN, Bart BERGHS. Acta Orthop. Belg., 2011, 77, 21-26.
3. Greenstick Fracture of The Radius And Ulna, E.Mervyn Evans, Swansea, Wales, JBJS vol-33B, NO.4, November, 1951.
4. A Study Of supination and Pronation with especial reference to The Treatment of Forearm Fracture. James Patrick, F.R.C.S., Glasgow, Scotland, JBJS vol.28, no.4, October 1946.
5. Immobilisation of forearm fractures in children : Extended versus flexed elbow.
6. C. Bochang, Y. jie, K. Katz. vol 87-B No., 7, July 2005. JBJS
7. Paediatric forearm fractures : Functional outcome of conservative treatment
8. Nazari Ahmd Tarmuzi, Shalimar Abdullah, Bratisl lek listy 2009; 110(9) 563-568
9. Cast and padding indices used for clinical decision making in forearm fractures in children : Sarvpreet Singh, Maneesh Bhatia, and Phil Housden, Acta orthopedic 2008;79(3): 386-389
10. Remanipulation of forearm fractures in children : Chan CF; Meads BM; Nicol RO
11. N Z Med J July 11 1997