Volume : 5 | Issue : 12 | December-2016 ISSN - 2250-1991 | IF : 5.215 | IC Value : 79.96

Original Research Paper Oncology

Epitheloid Sarcoma of the Vulva – A Case Report

Dr tara ram choudhary Resident doctor, Gujarat cancer and research institute, Ahmedabad.

Dr ankita parikh Associate professor, Gujarat cancer and research institute, Ahmedabad.

ABSTRACT

Background
Epitheloid sarcoma is a rare and aggressive malignant soft tissue tumor.[1] Epitheloid sarcoma of vulva is even rarer and only 20 cases have been reported.[2]

Case Report
A 46 year old female, presented with a palpable, firm, non tender mass of right labia majora. USG of the abdomen and pelvis revealed multiple submucosal (2.9cm), subserosal (2.1cm) and cervical fibroids. Right ovary was normal and left ovary had multiple simple cysts, largest measuring 2.3cm. She underwent Total abdominal hysterectomy bilateral salpingo-oophorectomy with wide local excision of the labial mass.
Histopathological report suggested high grazed malignant epithelial tumor of the labia. Immunohistochemistry showed AE1 positive, EMA positive, Vimentin Positive, AFP negative, Desmin negative, CK-7 negative and was concluded to be Epitheloid sarcoma, Proximal type. A thorough metastatic work up was done and was found to be normal. The patient was delivered postoperative radiotherapy 50Gy in 25 fractions five day a week over five weeks.

Result
Patient is currently on follow up and is asymptomatic.

KEYWORDS Epitheloid sarcoma, vulva, proximal type.

Introduction

Epitheloid sarcoma is rare and aggressive malignant soft tissue tumor was first characterized as a distinct clinico-pathological entity by Enzinger in 1970 which is usually arise in the hand and forearm of young adults[1]. Epitheloid sarcoma of vulva is even rarer and only 20 cases have been reported[2]. It poses diagnostic difficulties both clinically and pathologically and thus the treatment becomes challenging. They are divided into two types i.e. 'Proximal' which arises on the trunk and 'Distal' type which arises on upper and lower limbs[3]. The "classic" or distal type is common and mainly affects the wrist and hands[4]. The proximal type tends to arise in the axial locations, such as pelvis, perineum and genital tract. It is more aggressive in behavior.

We report a case of Epitheloid sarcoma of vulva with its pathological features and management.

Case Report

A 46 year old female, Gravida one, para two, presented to the gynecology OPD in January 2015, with chief complaints of a palpable mass lesion of size 7-8 cm over right labium majus from mons pubis (above clitoris), around oval in shape since 2000 and mass become increasing in size since 5-6 months. It was associated with itching and not associated with pain and discharge. On physical examination, the mass revealed smooth surface, firm inconsistency and was non tender. There were no clinically palpable inguinal lymph nodes. USG of the abdomen and pelvis revealed multiple submucosal (2.9cm), subserosal (2.1 cm) and cervical fibroids. Right ovary was normal and left ovary had multiple simple cysts, largest measuring 2.3 cm. Patient had also underwent laparoscopic myomectomy for multiple fibroids in august 2008 and September 2011. Patient had twin baby girl with IVF conception.

She had negative personal and family history for other diseases. All other routine investigations were done, following which, Trans-abdominal hysterectomy and bilateral Salpingo–oophorectomy with wide local excision of the labial mass was done on - 07.02.2015 (Figure 1). Histopathological report of the labial mass was suggestive of high grade malignant epithelial tumor of the labia (Figure 2). Histopathological feature suggestive of tumor cells in reticular and solid pattern on myxoid background, cells show vesicular nucleus with prominent nucleoli, and tumor tissue with necrosis present high grade malignant tumor. Immuno-histochemistry showed AE1 positive (Figure 3), Vimentin strongly positive (Figure 4), and epithelial membrane antigen positive. AFP negative (figure 5). Desmin negative, CK7 negative, S-100 negative, CD34 negative, P63 negative, CA-125 negative. Tumor cells show loss of INI-1 expression and was diagnosed to be Epitheloid sarcoma, proximal type.

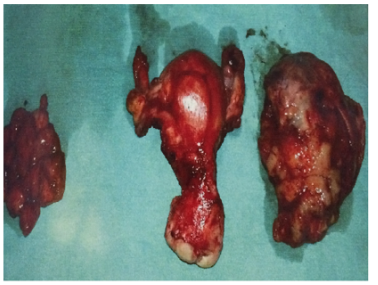

Fig. 1 Surgical Specimen

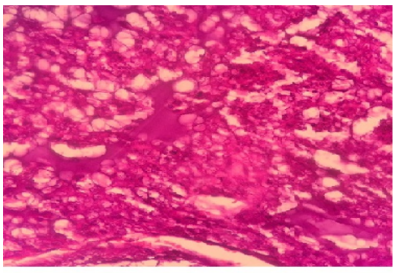

Fig. 2 Histopathological feature suggestive of tumor cells in reticular and solid pattern on myxoid background, cells show vesicular nucleus with prominent nucleoli, and tumor tissue with necrosis.



Fig. 3 Immunohistochemistry showing AE1 positive

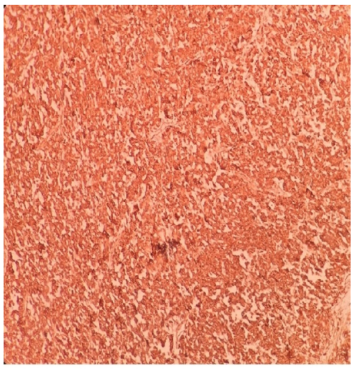

Fig4. Immunohistochemistry panel showing Vimentin strongly positive

Fig. 5 Immuno-histochemistry showing AFP negative

A thorough metastatic work up was done. Pap's smear was negative for intraepithelial neoplasia. Chest x-ray shows old calcified granuloma in right upper zone. CT thorax, CT Abdomen and Pelvis was performed and was found to be negative CA 125 was found to be normal. The patient was administered Post operative radiotherapy with single perineal field in lithotomy position (Figure 7), to a dose of 50 Gray in 25 fractions, on a telecobalt unit from 09.04.2015 to 11.05.2015. The patient is currently on follow up, and is asymptomatic.

Discussion

Epitheloid sarcoma is a rare malignant soft tissue tumor of mesenchymal origin. Most Epitheloid sarcomas usually present as a rapidly growing, painless, subcutaneous nodule commonly mistaken as a benign lesion, e.g. Bartholin cysts, lipomas, fibromas, teratoma[2]. These misdiagnoses lead to inadequate and delayed treatment, adversely affecting the therapeutic outcome. Other malignant conditions those need to be differentiated from this, are, Squamous cell carcinoma, malignant melanoma and malignant rhabdoid tumor. Squamous cell carcinoma can be differentiated by; the presence of keratin pearls, intercellular bridges and overlying dysplasia while Squamous cell carcinoma and Rhabdoid tumors are CD34 negative unlike epitheloid sarcoma. Malignant melanoma is positive of Melanin, S-100, HMB 45 and Melan-A which are usually negative in epitheloid sarcoma. Co-expression of vimentin and keratin is characteristics of epitheloid sarcoma. Pan-keratin AE1 and epithelial membrane antigen positive in 96% and 98% of cases respectively.Recently, in genetic study, loss of INI 1 gene in more than 80% of patients with epitheloid sarcoma.

The Primary treatment of Epitheloid sarcoma of vulva consists of wide local excision of the lesion with an aim of achieving 2 cm margin[2]. The role of adjuvant radiotherapy is controversial. One study reports a recurrence rate of 14% in patients who received adjuvant radiotherapy as compared to 71% in patients who did not received it (p=0.01)[5]. Another study recommends adjuvant radiotherapy for high grade tumors and those with inadequate margins6. The role of chemotherapy in this condition is an adequate. A variety of chemotherapy regimens have been employed but without any significant results and chemotherapy for recurrences is even less effective.4 Overall five year survivalrate for distal type of Epitheloid sarcoma is 50 to 80% and 10 year survival rate is 42-45% but proximal type has poor prognosis [1,4,5].

Indicators of poor prognosis of Epitheloid sarcoma include vascular invasion, depth of invasion more than 0.5cm, tumor size more than 5 cm. more than 30% necrosis, high mitotic activity, nodal involvement, multifocal local disease, presence of local recurrence and advanced stage at presentation, male sex, older age at presentation. Two variety of Epitheloid sarcoma are described in literature. "Proximal type" type variant first described in 1997 and occurs in perineum and pubic region and have a distinct entity than "distal type". Distal type occurs in upper and lower extremities. Proximal type Epitheloid sarcoma have higher rate of localrecurrence and distant metastasis. Local recurrence is common and may develop after many years post successful treatment, despite adequate and negative resection margin. Distant metastasis eventually occurs in up to 60% of cases[6]. Excision with wide surgical margins is the treatment of choice. Surgery is also recommended for local recurrences. Removal of inguinal lymph node is controversial. Dissection of loco-regional lymph node is considered if there is suspicious or enlarged node at physical examination or in imaging studies. Unlike most soft tissue sarcoma, Epitheloid sarcoma characteristically spread to lympatics. 34% patient presents withy lymph node metastasis at the time of diagnosis. Post operative radiotherapy decreases the recurrence rate in case of close margin or high grade histology the role of adjuvant chemotherapy is minimal even in metastatic disease.5 year and 10 year survival of Epitheloid sarcoma is 50-70% and 42-55% respectively. Optimal treatment of epitheloid sarcoma of vulva is not known due to its rarity

REFERENCES:

1. Enzinger FM. Epitheloid Sarcoma: A sarcoma simulating a granuloma or carcinoma. Cancer 1970:26:1-29-41.
2. Kim JH, Choi YS, Lee TS. A case of epitheloid sarcoma arising in the vulva. J of Gynaeconcol 2008: 19(3):202-4.
3. Guillou L. Wadden C. Coindre JM. Kraus T Flethcher CD. "Proximal type" epitheloid sarcoma, a distinctive aggressive neoplasm showing rhabdoid features, Clinicopathologic, immunohistochemical study of a series. Am J SurgPathol 1997:21:130-146).
4. Chase DR, Enzinger FM. Epitheloid sarcoma: diagnosis, prognostic indicators and treatment. Am J SurgPathol1985:9:241.
5. ArgentinalPA, Thomas S, Chura JC. Proximal typeepitheloid sarcoma Vs malignant rhabdoidtumor of the vulva: a case report,review of the literature, and an argument for consolidation. GynaecOncol 2007:107:130-5)
6. Hasegawa T. Matsuno Y. Shimoda T. Umeda T. Yokoyama R. Horhashi S. Proximal type epitheloid sarcoma: a clinicopathologic study of 20 cases. Mod Pathol 2001: 14:655-63.