Volume : 5 | Issue : 12 | December-2016 ISSN - 2250-1991 | IF : 5.215 | IC Value : 79.96

Original Research Paper Orthopaedics

Sterile Spondylodiscitis in a Case of Ankylosing Spondylitis – Andersson Lesion

Dr Vinay Jain K	Junior Resident, Department of Orthopaedics, M S Ramaiah Medical College, Bangalore, India
Dr Abhilash Palla	Junior Resident, Department of Orthopaedics, M S Ramaiah Medical College, Bangalore, India
Dr Ravikumar T V	Assistent Professor, Department of Orthopaedics, M S Ramaiah Medical College, Bangalore, India

ABSTRACT

The case we present here is of a 54 year old male patient who presented to us with pain of lower back with difficulty in walking. Patient is a known case of Ankylosing spondylitis and Psoriasis. Radiographs and MRI were suggestive of infective Spondylodiscitic features. He underwent posterior spinal Fusion and biopsy was sent for Histopathological examination and culture and sensitivity which ruled out the infective pathology, going against the MRI finding of infective spondylodiscitis and suggestive of Andersson lesion. The detailed knowledge of Andersson lesion is required in order to differentiate spondylodiscitis in cases of Ankylosing spondylitis of longer duration, which mimics infection. Thus helping us to avoid these patients to be managed in the lines of infective pathology.

KEYWORDS Andersson lesion, spondylodiscitis, Ankylosing spondylitis, instrumentation, trauma.

INTRODUCTION:

Ankylosing spondylitis (AS) is a chronic idiopathic inflammatory disease primarily affecting the spine and sacroiliac joints. Main presentation includes pain, stiffness and a progressive thoracolumbar kyphotic deformity [1].

Throughout the course of the disease radiological changes can be appreciated which includes ossification of the spinal ligaments, joints and intervertebral discs. Leading to a fused and brittle spine making it susceptible to fractures. The mechanical forces and the concomitant inflammation results in focal discovertebral lesions that fail to heal, causing persistent symptoms, eventually leading to pseudoarthrosis and mimicking spondylodiscitis. The focal discovertebral lesion in AS is referred to as Andersson lesion, first described by Andersson in 1937. Hence it is very important to diagnose and differentiate between the two entities, the Andersson lesion and spondylodiscitis, since the management of the two conditions in entirely different.

CASE PRESENTATION:

The case we present here is of a 54year old male patient who presented to us with the history of trauma 2months back following which he developed pain of lower back. Pain increased gradually over the past 2weeks and developed difficulty in walking. Patient was a known case of Ankylosing spondylitis and Psoriasis and was on Inj Etanercept since 3years. Radiography of the dorsolumbar spine showed squaring of the vertebra, syndesmophytes, and pseudoarthrosis of the facet joints, end plate irregularity at D11-D12 level, with compression fracture of the D12 vertebrae (Fig1), and the magnetic resonance imaging suggestive of infective Spondylodiscitic features (Fig 2). Laboratory values were marginally elevated; with erythrocyte sedimentation rate (ESR) of 42, C-reactive protein (CRP) of 2.5 and total count of 10,250 cells/cumm. He underwent posterior spinal instrumentation and fusion (Fig 4), and biopsy from the involved disc level along with vertebral bone biopsy was sent for Histopathological examination (HPE), culture and sensitivity and TB-pcr. The HPE showed hypercellular stroma with bone trabeculae suggestive of callous and culture showing no growth of the organism, going against the MRI finding of infective spondylodiscitis and suggestive of Andersson lesion. Following surgery patient showed good functional outcome. The patient was not put on any long course of antibiotics. Later rheumatologist opinion was taken allowed to continue treatment of the Ankylosing spondylitis and psoriasis as before. Patient was followed up for a period of one year and improved both clinically and functionally. Serial radiographs showed good fusion at the involved level.

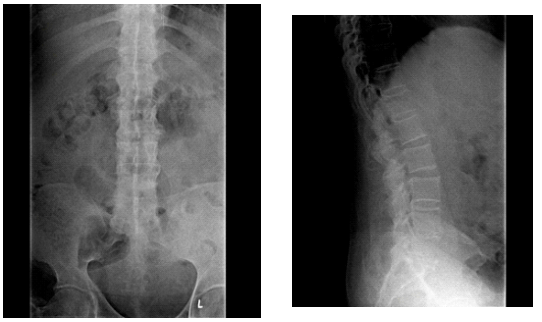

Fig 1: Radiographs lumbosacral spine (AP and Lateral) showing the endplate changed at the D11-D12 level with pseudoarthrosis at multiple levels.

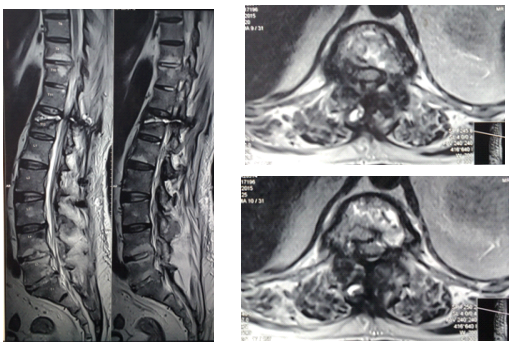

Fig 2: MRI showing spondylodiscitis of the D11 – D12 intervertebral disc

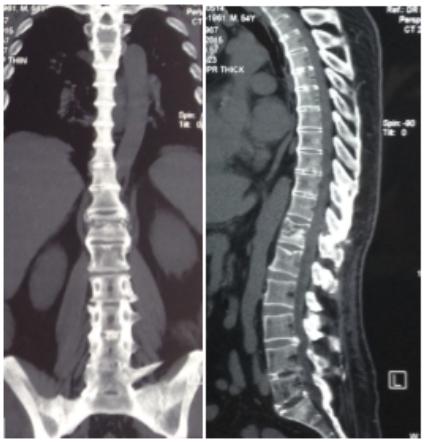

Fig 3: CT showing the destruction of the vertebral bodies at the involved level

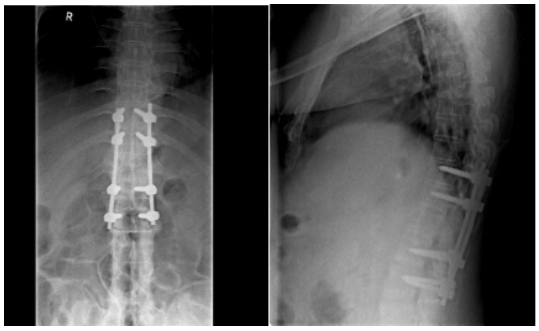

Fig 4: Postoperative Radiographs of lumbosacral spine (AP and Lateral) showing posterior spinal instrumentation done from D10 to L2 level.

DISCUSSION:

The estimated prevalence of AL varies from 1.5% to 28%, which is based on the review article by Bron et al, 2009 [2]. This wide range may be explained by the fact the condition lacks a proper diagnostic criteria, non specific presentation and the fact mimicking infective spondylodiscitis. The etiology is still uncertain, but believed to be non-infectious. The two proposed theories include, one is inflammatory and the other mechanical/traumatic.
During the course of AS, there is progressive ossification of the ligaments which causes the spine to become rigid. Osteoporosis of the vertebral bodies continue with the ongoing inflammation, leading to which the nucleus pulposus can herniated into the vertebral body through the endplate. This causes the inflammatory response due to the antigenicity of the nucleus [2].

Another proposed theory is that the extent of inflammation and spinal fusion are not equally distributed throughout the spine in the course of the disease. Because of which the areas with decreased fusion (mobile segment) with increased inflammation forms one segment and on the other hand areas with increased fusion (stiff segment) and decreased inflammation forms one segment, which makes the spine prone for stress fractures at the junction. Once the fracture develops it is likely to undergo pseudoarthrosis [2].

Cawley et al. (1972) [3], reported that these lesions can either be focal or affecting more levels at once [3], and classified into three types. Type 1 lesions which can occur in both ankylosed and non-ankylosed spine are localised to the central subchondral portions of the discovertebral junction. Type2, these lesions are peripherally localized lesions occurring in the anterior or posterior part of discovertebral junction. Type3, usually seen in advanced ankylosis involving destruction of the whole discovertebral junction, there may be a history of trauma and associated fracture through the ankylosed spine.

Wang et al (2011), a study of 8 cases in which they postulated surgical instrumentation with fusion as treatment of choice for Andersson lesion in cases with traumatic etiology [4]. Curettage of the lesion, anterior fusion and posterior fixation has been proposed as the golden standard. However, there are reports of successful fusion with posterior fixation only, without any curettage of the lesion and without anterior fusion. In the present case we followed only posterior instrumentation, which gave good results both functionally and radiologically.

The detailed knowledge of Andersson lesion is thus required in order to differentiate it from spondylodiscitis in patients of Ankylosing spondylitis of long duration, which mimics infection.

Thus helping us to avoid these patients to be managed in the lines of infective pathology.

REFERENCES

1. Von Bechterew W (1893), Steifigkeit der wirbelsäule und ihre Verkrümmung als besondere Erkrankungsform. Neurologisches Zentralblatt 12:426–434.
2. Bron JL, de Vries MK, Snieders MN, van der Horst-Bruinsma IE, van Royen BJ. Discovertebral (Andersson) lesions of the spine in ankylosing spondylitis revisited. Clin Rheumatol. 2009; 28: 883–892.
3. Cawley, Chalmers, Kellgren et al. Destructive lesions of vertebral bodies in Ankylosing spondylitis. Ann Rheum Dis 1972; 31: 345.
4. Wang G, Sun J, Jiang Z, Cui X. The Surgical Treatment of Andersson Lesions Associated With Ankylosing Spondylitis. Orthopedics. 2011; 34: 302-306.
5. Pen, Milcic, Krajnc, Vogrin, Recnik, Andersson Lesion Presenting Itself as Spondylodiscitis and Evolving to Pseudoarthrosis in a Patient with Ankylosing Spondylitis: A Case Report. Austin J Orthopade & Rheumatol. 2015; 2(1): 1011.
6. Hanson JA, Mirza S. Predisposition for Spinal Fracture in Ankylosing Spondylitis. Trauma Cases from Harborview Medical Center. AJR. 2000; 174: 150.
7. Dhakad U, Das SK. Anderson lesion in ankylosing spondylitis. BMJ Case Rep. 2013.