



## Limbal Dermoid Excision Followed by Amniotic Membrane Grafting in a Case of Goldenhar Syndrome

**Dr Dhaivat Shah**

3rd year resident, C H Nagri Eye hospital,

**Dr Kush Patel**

3rd year resident, C H Nagri Eye hospital

**Dr Dipali Satani**

Associate professor, C H Nagri Eye hospital

### KEYWORDS

#### INTRODUCTION:

A 12 year old male patient, presented to C.H. Nagri eye hospital, Ahmedabad, with complain of ocular discomfort and for assessment of limbal swelling in left eye since the past 1 year, gradually increasing in size, for which the patient used lubricating and antibiotic eyedrops on & off, prescribed locally. There is past history of pre-auricular tags surgically removed in a local hospital, with no other significant details available. Family and birth history were insignificant.

#### AIMS AND OBJECTIVES:

To surgically excise the mass taking care of cosmetic appearance and avoiding recurrence, along with evaluation of the mass histopathologically.

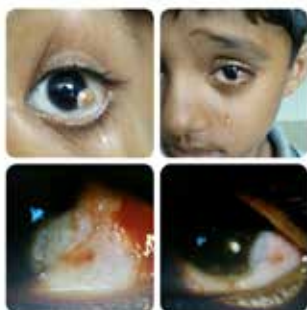#### METHODOLOGY:

Best corrected visual acuity in both eyes was 6/6. IOP measured by Applanation tonometer was 12 & 14 mm Hg respectively. Anterior segment examination revealed a 6\*4 mm limbal swelling, in the inferotemporal quadrant, extending 2mm on the corneal surface, in the left eye. Posterior segment evaluation revealed healthy disc, fundus glow, normal cup disc ratio and dichotomously branching vessels in both eyes.

Surgical excision with histo-pathological evaluation of the mass followed by amniotic membrane grafting was planned, henceforth.

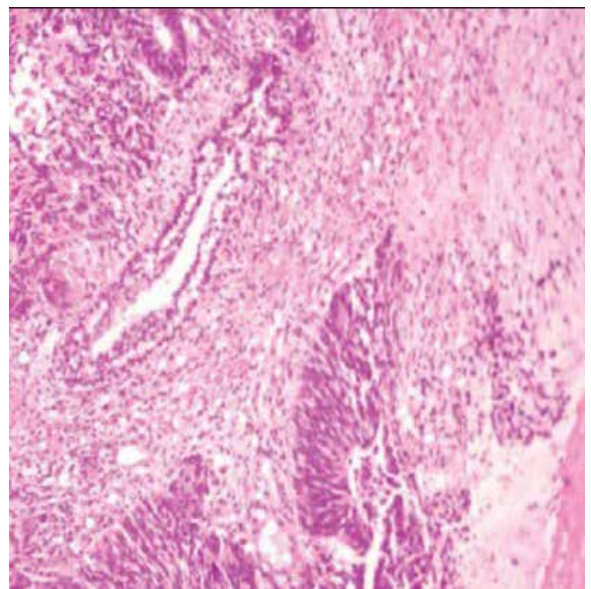
#### RESULTS:

Post op follow up was taken at day 1, day 5, 2 week, 1, 3 and 6 months. Lubricating eyedrops 6 times/day, antibiotic eyedrops (Gatifloxacin & Tobramycin) 6 times/day, with low dose steroids (Fluomethalone) 4 times/day tapered off every 5 days, were prescribed. The amniotic membrane graft was in place with intact vicryl 8-0 sutures on day 1. There was ciliary congestion and an area of sub conjunctival haemorrhage at 7 o'clock, which cleared up by 2 weeks. At the end of 3 months, the amniotic membrane graft had completely settled and acquired transparency, with no evident vascularisation or inflammation. At the end of 6 months, there was no more ocular discomfort or any recurrence of a similar swelling.



#### HISTOPATHOLOGICAL EVALUATION:

Histo-pathological reports confirmed the lesion to be a solid limbal dermoid. The tissue revealed stratified squamous epithelium with thin keratinisation superficially, with stroma containing disordered pilar structures, inflammatory exudates, vascular bodies and some amount of adipose tissue, ruling out any malignant changes.



#### CASE DISCUSSION:

Goldenhar syndrome (also known as Oculo-Auriculo-Vertebral (OAV) syndrome) is a rare congenital defect characterized by incomplete development of the ear, nose, soft palate, lip, and mandible. It is associated with anomalous development of the first and second branchial arch. Common clinical manifestations include limbal dermoids, preauricular skin tags, and strabismus. It affects between 1/3,500 to 1/26,000 live births, with a male:female ratio of 3:2. Chief markers of Goldenhar syndrome are incomplete development of the ear, nose, soft palate, lip, and mandible on usually one side of the body. Additionally, some patients will have growing issues with internal organs, especially heart, kidneys, and lungs. Typically, the organ will either not be present on one side or will be underdeveloped. Other problems can include severe scoliosis (twisting of the vertebrae), limbal dermoids, and hearing loss (see hearing loss with craniofacial syndromes), and deafness or blindness in one or both ears/eyes, granulosa cell tumors may be associated as well.

**CONCLUSION:**

This case has been presented to increase the awareness about this rare entity, to highlight the typical clinical and histopathological findings & treatment approach using amniotic membrane graft modality in cases of dermoid associated with Goldenhar syndrome. The limbal dermoids are usually recurrent and are conventionally treated with dermoid excision with bare sclera technique or conjunctival autograft. The long term advantages of Amniotic membrane grafting include graft stability, better cosmesis and relatively less chances of recurrence. And if the graft is used with a fibrin glue, suture placement can be avoided, thereby decreasing the post operative foreign body sensation and discomfort & increasing patient compliance and outcome.

**REFERENCES:**

1. Goldenhar syndrome, a report of 3 cases. *Indian J Dermatol.* 2013 May-Jun; 58(3): 244.
2. Goldenhar syndrome. *Br Med J.* 1968 Feb 24; 1(5590): 489-490.
3. Berker N, Acaroglu G, Soykan E. Goldenhar's Syndrome (oculo-auriculo-vertebral dysplasia) with congenital facial nerve palsy. *Yonsei Med J.* 2004; 45(1):157-160.
4. Gomez GA, Vargas TF, Paya Abad EA. Goldenhar syndrome. Discordance in monozygotic twins. *An Esp Pediatr.* 1984;20:400-402.
5. Herman GE, Greenberg F, Ledbetter DH. Multiple congenital anomaly/mental retardation (MCA/MR) syndrome with Goldenhar complex due to a terminal del(22q). *Am J Med Genet.* 1988;29:909-915.
6. Kallen K, Robert E, Castilla EE, Mastroiacovo P, Kallen B. Relation between oculo-auriculo-vertebral (OAV) dysplasia and three other non-random associations of malformations (VATER, CHARGE, and OEIS). *Am J Med Genet.* 2004;127A:26-34.
7. Volpe P, Gentile M. Three-dimensional diagnosis of Goldenhar syndrome. *Ultrasound Obstet Gynecol.* 2004;24(7):798-800.
8. Stark RB, Saunders DE. The first branchial syndrome. The oral-mandibularauricular syndrome. *Plast Reconstr Surg.* 1962;29:229-239.
9. Poswillo D. Mechanism and pathogenesis of malformation. *Br Med Bull.* 1976; 32:59-63.
10. Moeschler J, Clarren SK. Familial occurrence of hemifacial microsomia with radial limb defects. *Am J Med Genet.* 1982;12:371-375.
11. Saxena R, David MP. Goldenhar Syndrome - A Rare Case Report. *J Genet Syndr Gene Ther* 2012; 3:1-4.
12. Baum JL, Feingold M. Ocular aspects of Goldenhar's syndrome. *Am J Ophthalmol.* 1973; 75: 250-257.
13. Kannur A, Talpallikak N, Chavan P. Goldenhar syndrome- A case report. *National Journal of Medical and Allied Sciences* 2013; 2: 32-35.
14. Padaley JS, Patankar D, Meena MR. Goldenhar Syndrome. *Inj J Contemp Pediatr* 2014; 1:58-60.
15. Nessim-Morcous I, Mathalone MB, Kessel I. Goldenhar's syndrome. *Br Med J.* 1968; 1: 489-490.
16. Al-Droos M, AlmmaniB. Goldenhar Syndrome: A Case Report. *Middle East Journal of Age and Ageing* 2013; 10:31-34.
17. Soni ND, Rathod DB, Nicholson AD. Goldenhar Syndrome with Unusual Features. *Bombay Hospital Journal* 2012; 54: 334-335.
18. Costa CF, Rusu C, Ivanescu CG, Dumitras S, Dimitria G, Cucu A, et al. Goldenhar Syndrome. *J Clin Res Ophthalmol* 2015; 2:041-044.
19. Summit, R.: Familial Goldenhar Syndrome: Birth Defects, 5: 106-109. 1969.
20. Smith, D. W.: Recognizable patterns of human malformations. In, "Major Problems in Clinical Paediatrics," W. B. Saunders Company, Philadelphia, 1982, pp. 168-169.