



## A Morphological Study of Brachial Artery, its Branching Pattern and Variations With its Clinical Correlations

**Dr.Ganesan Muruga Perumal**

Associate Professor, Department Of Anatomy, Tagore Medical College & Hospital, Rathinamangalam

**Dr.D.H.Gopalan**

Associate professor, Department Of Anatomy, Tagore Medical College & Hospital, Rathinamangalam

**Dr.V.Vijayaraghavan**

Professor, Department Of Anatomy, Tagore Medical College & Hospital, Rathinamangalam

### ABSTRACT

**Background:** The Brachial artery, a continuation of the axillary artery, begins at the distal (inferior) border of the tendon of the teres major and ends about a centimeter distal of the elbow joint (at the level of the neck of the radius) by dividing into radial and ulnar arteries. The brachial artery is an important arterial conduit from the clinical point of view and the brachial artery is indispensable to anatomists, general surgeons, radiologists, plastic surgeons, and even cardiovascular thoracic surgeons. **Context & purpose of study:** The routine dissection method was done on 50 upper limbs, belonging to 20 embalmed cadavers, and 10 free upper limbs over a period of two years in the Department of Anatomy, Tagore Medical College & Hospital, Rathinamangalam to study the variation in the course, branching pattern of brachial artery. **Results & Conclusion:** In majority of the cases, the brachial artery terminated below the intercondylar line in the cubital fossa. In one case, the profunda brachii artery showed variations and in three cases nutrient artery arose from the ulnar artery bilaterally where the brachial artery had higher bifurcation in the upper arm. In two cases, the axillary artery gave off superficial brachial artery & in six cases; the median nerve coursed medial to the brachial artery throughout its course in the upper arm whereas in all the other cases, the median nerve crossed the brachial artery in the middle of arm in the usual manner. The length, course, branching pattern and the variation of the brachial artery which will be of considerable practical importance in the conduct of reparative surgery in arm and forearm and for the invasive procedure like angiogram.

### KEYWORDS

Brachial artery; Radial artery; ulnar artery

### INTRODUCTION

Arterial supply to the human upper limb is the most important subject of many anatomical studies due to their high incidence. Variations in the arterial pattern of the upper limb have been observed frequently, either in routine dissections or in clinical practice (10). However some important aspects have until now remained confused or unstudied due to the use of different terminologies and of different criteria for classifying or subclassifying them (1, 11). Striking variations in origin and course of the principal arteries of the upper extremities have long received the attention of anatomists and surgeons for the surgical intervention in case of fractures of humerus and any vascular injuries. Nowadays even the Cardiologists and Radiologists are utilizing the brachial artery with increasing frequency for catheter based diagnostic and therapeutic intervention procedures viz. diagnostic angiography, cardiac catheterization for angioplasty, carotid stenting, trans-brachial access for endovascular renal artery intervention, embolectomy through arteriotomy on brachial artery. Apart from the above mentioned procedures, accidental intra-arterial injections, ligations of the brachial artery instead of the vein have been reported. In order to avoid all these complications, an accurate knowledge of this major artery in relation with its course and particularly of its variational branching pattern is of considerable practical importance and thereby hoping to add more information to guide the Clinicians, Surgeons and Cardiologists.

Since the brachial artery is regarded as an important structure clinically with the high prevalence of variations in the branching pattern, although enormous study was documented by many investigators to add more information in the existence of arterial variations, the present study was carried out to review the literature on the variations in the brachial artery in order to simplify previous classifications and to unify the terminology and morphological descriptions.

### MATERIALS AND METHODS

The study was conducted over a period of two years in the Department of Anatomy, Tagore Medical College & Hospital, Rathinamangalam. 50 upper limbs, belonging to 20 embalmed cadavers, and 10 free upper limbs were used for the study. Out of 20 embalmed cadavers, 12 were males and 8 were females. The dissections were done on the upper limbs of both sides. The cadaver was placed on the dissection table in supine position with the upper limbs at right angles to the trunk. Prior to the procedure of the dissection, the entire length of arm and entire length of the upper limbs were measured from prefixed bony points so that the distances could be represented as a percentage. For the morphological study the parameters used were length of entire upper limb, length of arm, length of brachial artery, level of termination of brachial artery.

### OBSERVATIONS & RESULTS

#### DISTRIBUTION OF RANGE OF UPPER LIMB LENGTH IN MALE AND FEMALE CADAVERS

The length of the upper limbs in the 20 cadavers and 10 free upper limbs dissected showed a minimum of 50.5 cm to a maximum of 66.0 cm with a mean value of 57.5 cm. The length of the upper limbs in 12 male cadavers showed a minimum of 51.5 cm to a maximum of 66.0 cm with a mean of 58.5 cm. The length of upper limbs in 8 female cadavers showed a minimum of 50.0 cm to a maximum of 52.5 cm with a mean length of 51.5cm

The distribution of range of upper limbs length in male and female cadavers is tabulated as follows (Table. 1)

**TABLE. 1**

Length in cm	Male	Female	Total
50 cm	0	2	2
50-55cm	2	6	8
55-60cm	7	0	7
60-65cm	2	0	2
65-70cm	1	0	1

**DISTRIBUTION OF RANGE OF ARM LENGTH IN MALE AND FEMALE CADAVERS**

The length of arm ranged from a minimum of 26.0 cm to a maximum of 34.5 cm with the mean value of 30.5cm. The length of arm in the male cadavers ranged from a minimum of 28 cm to a maximum of a 34.5cm with the mean value of 31.5cm. The length of arm in the female cadavers ranged from a minimum of 26 cm to a maximum of 28.5 cm with the mean value of 27.5cm.

The distribution of the range of arm length in male and female cadavers are tabulated as follows (Table.2)

**TABLE. 2**

Length of arm in cm	Male	Female	Total
25-30 cm	4	8	12
30-35cm	8	0	8

**LENGTH OF THE BRACHIAL ARTERY:**

In all cadavers dissected, the origin of the brachial artery was found to be the continuation of third part of the axillary artery and begin at the lower border of teres major. The length of the brachial artery was measured from the lower border of teres major to the point of bifurcation.

In 40 cadavers and in 10 free upper limbs dissected the length of the brachial artery ranged from 3.8cm to 28.5 cm with the mean value of 23.0 cm.

The overall length of the brachial artery in all specimens are mentioned below (Table.3).

**TABLE. 3**

Length in cm	Number of specimens
Upto 20cm	7
20-25 cm	31
25-30cm	12

**VARIATIONS:**

**Level of termination in relation to intercondylar line :**

In majority of the cases, the brachial artery terminated below the inter condylar line (80%) whereas in 4 cases (16%) above the intercondylar line, out of which in 2 cases 3cm and in 2 other cases 6cm above and in 2 cases (4%) at the intercondylar line are tabulated as follows

**Branching pattern:**

In 12 cases, branching pattern of the brachial artery showed variations and other limbs were found to be normal.

**a. Arteria Profunda brachii :**

In 1 case, the profunda brachii artery showed variations. It arose in common with the radial artery and ulnar artery in the upper 1/3rd of the arm

**b. Nutrient artery:**

In 3 cases, nutrient artery arose from the ulnar artery bilaterally where the brachial artery had higher bifurcation in the upper arm. In other 2 cases, the nutrient artery arose in common with inferior ulnar collateral artery

**c. Muscular branches:**

In 3 cases, the muscular branches are mainly given off from the radial artery and also from the ulnar artery where the radial artery and ulnar arteries had higher origin in the upper arm

**d. Superior ulnar collateral artery:**

In 1 case, the superior ulnar collateral artery and inferior ulnar collateral artery arose by a common stem from the common interosseous artery


**e. Communicating branches:**

In 1 case, the common interosseous artery was communicated with the radial artery and in the another case the common interosseous artery was found to be communicated with the ulnar artery

**f. High origin of common interosseous artery:**

In 1 case, the common interosseous artery arose from the brachial artery in the upper third of arm itself which also gave off the common stem for superior and inferior ulnar collateral arteries as mentioned in the previous case (Fig. 1).

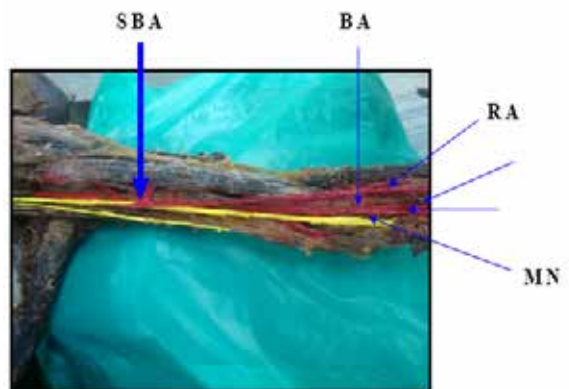
In another case, in the cubital fossa the trifurcation of the brachial artery was found which was divided into the radial, ulnar and common interosseous arteries.



**Fig. 1 Shows high origin of common interosseous artery which also gave off superior ulnar collateral and Inferior ulnar collateral arteries**

**g. Superficial brachial artery:**

In 2 cases, the axillary artery gave off superficial brachial artery which did not pass between the medial and lateral roots of median nerve, but coursed superficial to the median nerve and in the forearm it continued as the radial artery. The brachial artery was divided into ulnar and common interosseous arteries in the cubital fossa (Fig. 2).

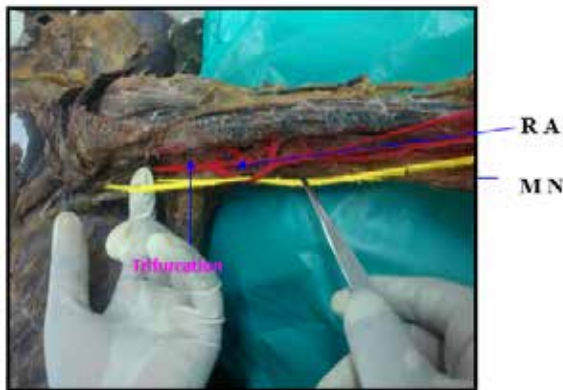

**Fig 2 Shows SBA, which coursed superficial to the median nerve**

in the arm and in the forearm continued as the radial artery.

**Relationship of median nerve to the brachial artery:**

In 6 cases, the median nerve coursed medial to the brachial artery throughout its course in the upper arm whereas in all the other cases, the median nerve crossed the brachial artery in the middle of arm in the usual manner. In a case of higher bifurcation, the radial artery looped around the median nerve in the upper arm (Fig 3). In another case, the median nerve coursed deeper to the brachial artery in the cubital fossa whereas in the upper arm it runs medial to the brachial artery. In one case, the median nerve was medial to the brachial artery and crossed it laterally in the cubital fossa and here it gave a muscular branch to the pronator teres.



## DISCUSSION

The accurate information concerning unusual patterns of the arteries in the upper limb is relevant clinically (Yalcin et al. 2006) [17]. Confusion of these unusual arteries with the subcutaneous veins may explain the accidental injection of drugs and distal necrosis of the limb. Knowledge of these variations may facilitate ascending catheterization of the cardiac cavities (Drizenko et al. 2000) [3]. The arterial variations of the upper limb have been implicated in different clinical situations. The superficial brachial, radial or ulnar arteries have been encountered during elevation of the radial forearm flap. The existence of a superficial radial artery implies the absence of the normal radial pulse at wrist level (Diz et al. 1998) [2]. It has also been reported as producing problems in cannulation for operating monitoring (Diz et al. 1998) [2] and as a symptomatic pressure that required surgical treatment. Finally in a recently reported clinical case, the absence of the ulnar artery was responsible for hand ischaemia after radial artery grafting for coronary bypass (Nunoo – Mensah, 1998) [12]. Therefore the present study was carried out with an aim to highlight the variations of the brachial artery in its origin, course, branching pattern and level of termination which will be very much useful to the clinicians.

Literature analysis revealed that the brachial artery is the continuation of the axillary artery, begins at the lower border of the tendon of teres major and ends by dividing into radial and ulnar arteries in the cubital fossa, at the level of neck of radius (Quain 1844; Poirier, 1886 et al.) [13,15]. The present study also coincided with the literature in the origin of brachial artery.

Patnaik et al. (2002) [14] had observed that the total length of the brachial artery on an average of 26.29 cm whereas the present study showed the average length of the brachial artery as 23 cm (ranging from 3.8cm to 28.5cm) which was measured from its origin, at the lower border of the teres major upto its point of bifurcation.

The site of origin of anomalous arteries in the arm is determined with reference to the intercondylar line of humerus. The bifurcation of the brachial artery proximal to this line is considered as a variation (Karlsson and Niechajev, 1982) [7]. The level of termination of the brachial artery above the intercondylar line was observed by many workers whose average distance ranged from 0.7 cm to 10 cm. In majority of the cases in the present study, the brachial artery was terminated below the intercondylar line (80%) in the cubital fossa, whereas in 2 cases, at the intercondylar line (4 %) and in 4 cases (16%) above the intercondylar line out of which in 2 cases 3cm, in 2 cases 6cm above the intercondylar line.

The observation of the superficial brachial artery in two cases in the present was also reported by so many workers. The superficial brachial artery commonly originates from the axillary artery and runs superficial to the muscles of the arm under brachial fascia lying slightly more lateral than brachial artery and in the elbow region divides into radial and ulnar arteries

(Anson, 1966). Keen (1961) [8] subdivided the superficial brachial artery (found in 12.3%) into two types: Type I: Those superficial brachial arteries which continue in the cubital fossa and bifurcate as usual into radial and ulnar arteries (3.6%). Type II: Superficial brachial artery continues as radial artery and known as "High origin of radial artery". The superficial brachial artery observed in 2 cases in the present study belongs to the type II of Keen's (1961) [8] classification. The superficial brachial artery observed in the present study did not divide into radial and ulnar arteries in the cubital fossa.

Patnaik et al. (2002) [14] observed 94% of profunda brachii artery arose from the postero-medial aspect of brachial artery and 2% of profunda brachii artery in his dissection arose from a common trunk with superior ulnar collateral artery. Keen (1961) [8] reported 61% of profunda brachii artery arose as a branch of brachial artery. In 13% cases, the profunda brachii artery arose as a common trunk with superior ulnar collateral artery. In 26% cases of his dissection, the profunda brachii artery arose from the axillary artery. But the present study did not show such origins. In all the cases in the present study, the profunda brachii artery arose from the brachii artery whereas only in one case, it arose in common with radial and ulnar artery (trifurcation of the brachial artery). This observation is not coinciding with that of previous workers and is a new finding so far not hitherto reported. In the present study in 3 cases (6%), the brachial artery bifurcated in the arm at a higher level which was also reported by many workers.

(1937) [4] and Poirier (1886) [13], described the nutrient artery as a branch of brachial artery which entered the nutrient canal at the level of the insertion of coracobrachialis muscle, also postulated the nutrient artery, a branch of the brachial artery entered that nutrient canal on its medial surface. In the present study in 3 cases (6%), nutrient artery arose from the ulnar artery bilaterally in higher bifurcation of brachial artery in upper arm. In another 2 cases (4%), arose in common with the inferior ulnar collateral artery and in all other cases in the present study the nutrient artery arose from the brachial artery and enters the nutrient canal as mentioned above by other workers except such origins of nutrient artery from the ulnar artery and also in common with inferior ulnar collateral artery are not reported earlier.

Patnaik et al. (2002) [14] reported 3% and Poirier (1886) [13] reported 6% of brachial artery superficial to the median nerve. In another 6 cases (12%) the median nerve coursed medial to the brachial artery throughout its course in the upper arm. In one case (2%), the median nerve was running medial to the brachial artery in the upper arm and crossed it laterally in the cubital fossa. In another case of higher bifurcation of the brachial artery, radial artery looped around the median nerve in the upper arm. This observation is a new finding and could not find a similar case in the available literature.

## CONCLUSION:

The length, course, branching pattern and the variation of the brachial artery which will be of considerable practical importance in the conduct of reparative surgery in arm and forearm and for the invasive procedure like angiogram. Arteriographic misinterpretation results when the contrast dye is injected into variant arteries instead of brachial artery. The existence of the superficial radial artery implies the absence of the normal radial pulse at the wrist level. In such cases, Doppler ultra sound imaging or angiography assist health care providers in treating patients with this knowledge of the present study. Therefore, Anatomical knowledge of brachial artery and its variations are very much essential to the Physicians, Surgeons, Radiologists and Cardiologists.

## REFERENCES

1. Adachi, B: Das Arteriensystem der Japaner, Kyoto (1928): Vol, p 205-10.
2. Diz JC, Ares X, Tarrazo AM, Alvarez J, Meanoser (1998): bilateral superficial radial artery at the wrist. *Acta Anaesthesiologica scandinavica* 42,1020.
3. Drizenko A, Maynou C, Mestbagh H, Mauroy B, Baillleul JP (2000): Variations of the radial artery in man. *Surg Radiol Anatomy*; 22(5-6):299-303.

4. Frazer W, (1937): *Southern Medical Journal*, vol 21 – iss 2 – pp. 148 – 153.
5. Fuss, FK; Matula, C.H.W. and Tschabhcser, M. (1985): Die arteria brachialis superficialis Anatomical Anzeles. 160:285-94.
6. Hollinshead WH (1982): *Anatomy for surgeons. 3<sup>rd</sup> ed.vol.3, the back and limbs.* Philadelphia: Harper & Row; p.362.
7. Karlsson, S. & Niechajev I.A. (1982): Arterial anatomy of the upper extremity. *Acta Radiological Diagonosis* 23: pp. 115-121.
8. Keen, J.A. (1961): A study of arterial variations in the limbs with special reference to symmetry of vascular pattern. *American journal of Anatomy*. 108:245-261.
9. Linell, E.A.(1921): The distribution of the nerves in upper limb with reference to variability & their clinical significance. *Journal of Anatomy*.55: p.79.
10. Lipper,H. and Pabst,R. (1985): *Arterial variations in man.* Springer, New York: pp. 68-73
11. Muller (1903): Die Arm Arterien des Menschen Anat Hefte; 22:p.379
12. Nunoo-Mensah J 1998 - An unexpected complication after harvesting of the radial artery for coronary artery bypass grafting. *Annals of thoracic surgery* 66,929-931.
13. Poirier, p. *Traite de Anatomie Humans Vol. II* Battaille & Co. Paris. (1886): Pp 756
14. Patnaik, V.V.G.; Kalsey,G; Singla Rajan,K.(2002): Bifurcation of axillary artery in its 3<sup>rd</sup> part – A Case Report. *Journal of the Anatomical Society of India*. 50(2): 166-169.
15. Quains, *The anatomy of arteries of human body*, Taylor & Walton, London (1844).
16. Williams, P.L; Bannister, L.H.; Berry, M.M.; Collins, P; Dyson, M; Dussek, J.E.; Fergusson, M.W.J. (1999): *Gray's Anatomy In: Cardio Vascular system.* Ga-bella, G. Edr. 38<sup>th</sup> Edn. Churchill Livingstone. Edinburgh, London: 1542-44.
17. Yalcin B, Kocabiyik N, Yazar F, Kirici Y, Ozan H (2006): Arterial variations of the upper extremities. *Anat Sci Int.*;81:62-64.[Pub Med]