



Rationale behind multi-modal investigations in Ewing's sarcoma of calcaneum

Ayush Kumar Singh	Senior Registrar, Department of Orthopaedics, Grant Government Medical College Mumbai
Manish Devidas Chatte	Senior Registrar, Department of Orthopaedics, Grant Government Medical College Mumbai
Hitesh Mangukiya	Junior Resident, Department of Orthopaedics, Grant Government Medical College Mumbai
Ujwal Ramteke	Junior Resident, Department of Orthopaedics, Grant Government Medical College Mumbai.
KEYWORDS	

ABSTRACT

Ewing's sarcoma is a malignant ,non-osteogenic primary tumor of bone which is commonly seen in the diaphysis of long bones and flat bones of pelvic girdle in patients mostly in their first and second decade. Ewing's sarcoma of calcaneum has been infrequently reported in literature and usually presents with distant metastasis and has poor prognosis. We wish to report the case of primary ewing's sarcoma of calcaneum without distant metastasis which was detected with the help of various modalities like MRI, CT, histopathology , Immunohistochemistry .Of the investigations mentioned above, there is no isolated single investigation which can confirm the diagnosis of Ewing's Sarcoma.

Introduction

Ewing's sarcoma is third most common primary tumour of bone but second most common malignant bone tumor. It is most commonly seen in the diaphysis of long bones and flat bones of pelvis. Age of presentation is in the first and second decade. This is a small round cell tumor believed to be derived from primitive neural tissue cells that are modulated by EWS/FLI1 fusion gene. Cytogenetically, the cells have reciprocal translocation t(11:22)(q24;q12).

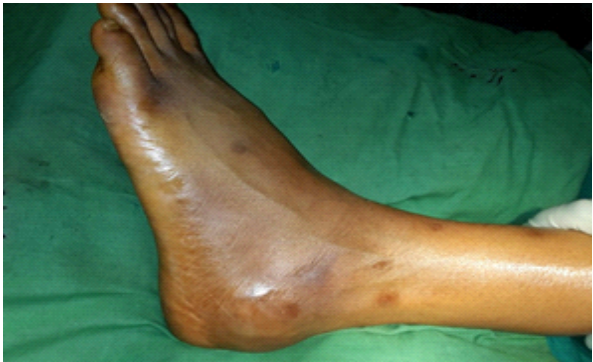The peak incidence of Ewing's sarcoma is in the second decade of life,with a male preponderance.It is a highly anaplastic,round cell tumor primary arising from the intramedullary portion of bone which demonstrates the predilection for long bones most common site being femur. Multiple metastasis may be present at time of diagnosis.

The management of ewings sarcoma requires multidisciplinary approach amongst surgeon, radiologist, pathologist , medical and surgical oncologist. Treatment includes multi-agent neo-adjuvant chemotherapy,followed by en-block excision of tumor mass.

Ewing's sarcoma rarely occurs in small bones of foot and the ones presenting with distant metastasis have a poor prognosis .We wish to report a case of Ewing's sarcoma of calcaneum without distant metastasis.

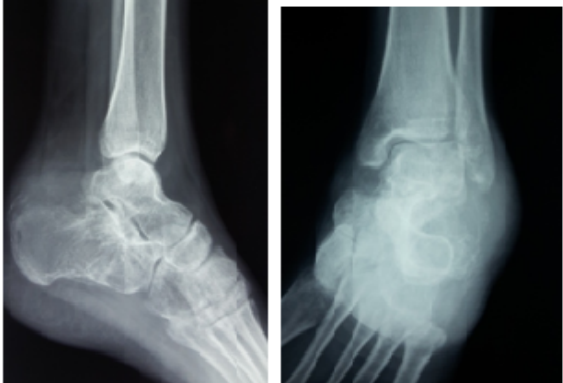Case report

A 22 year male patient presented with painful swelling over the region of left calcaneum which he noticed 4 months back. It started as a small painful swelling which showed rapid increase to the present size. At time of admission, the patient had a swelling and overlying skin was shiny with dilated veins.



Clinical Photograph

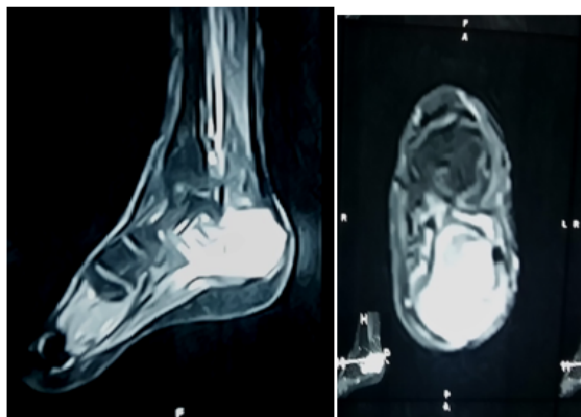
The plain radiograph of calcaneum was taken at time of presentation which showed presence of sclerotic lesion in calcaneum with periosteal reaction.



Xray of calcaneum showing periosteal reaction

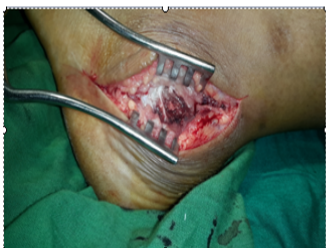The rest of skeleton examination was normal. All blood parameters were within normal limits.

To aid in diagnosis and to assess the local extent of disease the patient underwent MRI of foot which showed tumor confined to calcaneum without extraosseous extension.

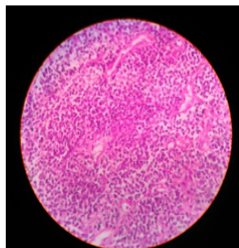


MRI of calcaneum

To confirm the diagnosis open biopsy was done by posterior-lateral approach to subtalar joint and histopathological examination showed malignant round cell tumor.



Biopsy of tumour



Histopathology

On immunohistochemistry, the cells were found to be positive for MIC-2 while they were negative for synaptophysin, desmin. LCA and tdT and FLI-1 was non-contributory.

HRCT of chest and bone scan were done to rule out lungs and bone metastasis.

Patient was treated with primary chemotherapy with vincristine, ifosfamide, methotrexate and cyclo-phosphamide.

Discussion

Ewing's sarcoma was first described in 1921. Ewings sarcoma is primary malignant tumor of diaphysis of long bones more commonly seen in patients between 5-20 years. Usually distant metastasis to lungs or long bone is present at time of presentation.

Diaphysis of long bone shows periosteal reaction with onion-skin

appearance. The lack of lamellated and speculated periosteal reaction and absent of cortical thickening is most commonly seen in the Ewings sarcoma of small bones of hand and feet.

Shirley et al. reviewed 10 cases with Ewings sarcoma of foot-5 in calcaneum, 1 in talus, 2 in metatarsal and 2 in the phalanges. With the exception of those patients with lesion in calcaneum, the prognosis for disease free survival was excellent.

Reported cases in literature and in IESS series associate lesion in the calcaneum with poor prognosis.

Conclusion

Ewing's sarcoma is malignant tumor of the bone with poor prognosis. Occurrence is rare in calcaneum and usually it presents with local and distant metastasis. We want to convey that early detection of ewings sarcoma is very important to prevent the metastasis. As ewings of calcaneum are usually atypical, multiple investigations like MRI, CT 6.5scan and histopathological as well as immunohistochemistry report are essential to confirm its diagnosis.

References

- Adkins CD, Kitaoka HB, Seidl RK et al. Ewing's Sarcoma of the foot. Clin Orthop. 1997; 342: 173-182.
- Dahlin DC, Coventry MB, Scanlon PW. Ewing's Sarcoma: a critical analysis of 165 cases. J Bone Joint Surgery 1961; 43-A: 185-192.
- Escobedo EM, Bjorkengren AG, Moore SG. Ewing's sarcoma of the hand. Am J Roentgenology 1992; 159: 101-102.
- Ewing J. Diffuse endothelioma of bone. Proc NY Pathol Soc. 1921; 21: 17-24.
- Greenfield GB. Sarcomas of bone. In: Berman CB, Brodsky NJ, Clark RA (eds). Oncological Imaging. A Clinical Perspective. Mc Graw Hill, New York, 1988: pp 279-306.
- Leeson MC, Smith MJ. Ewing's sarcoma of the foot. Foot Ankle 1989; 10: 147-151.
- Pritchard DJ, Dahlin DC, Dauphine RT et al. Ewing's Sarcoma: A clinicopathological and statistical analysis of patients surviving five years or longer. J Bone Joint Surg 1975; 57-A: 10-16.
- Ramachandran K, Sasidharan K et al. Ewing's Sarcoma of the calcaneum. Ind J Radiol Imag 2000; 10: 45-46.
- Reinus WR, Gilula LA, Shirley SK et al. Radiographic appearance of Ewing sarcoma of the hands and feet: report from the Intergroup Ewing Sarcoma Study. Am J Yalein S, Turoglu T, Ozdamar S et al. Ewing's tumor of the mandible: Oral surgery oral med oral pathol 1993; 76: 362-7. 6.5 Ewing J. Diffuse endothelioma of bone. Proc NY Pathol Soc. 1921; 21: 17-24.
- Agarwal N, Sabir AB. Ewing's sarcoma of the calcaneus with metastases to the tibia and fibula. Acta Orthop. Belg., 2008, 74, 270-272.
- Yasir Salam Siddiqui, Mohammad Zahid Calcaneal Ewing's Sarcoma with skip metastases to the adjacent tarsal bones: Journal Of Clinical and Diagnostic Research. 2011 Feb, Vol-5(1): 117-119