



## Role of Manual Vacuum Aspiration in the Evaluation of Postmenopausal Bleeding

**Dr Cheriyl Swapna Sukumaran**

Senior Resident , Department of OBG, Academy Of Medical Sciences, Pariyaram, Kannur, Kerala.

**Dr Omana E K**

Associate Professor , Department of OBG, Academy Of Medical Sciences, Pariyaram, Kannur, Kerala.

**Dr Vidya S Prabhu**

Associate Professor , Department of OBG, Academy Of Medical Sciences, Pariyaram, Kannur, Kerala.

**Dr Blessy Mary V R**

Junior resident , Department of OBG, Academy Of Medical Sciences, Pariyaram, Kannur, Kerala

**ABSTRACT**

Post menopausal bleeding is alarming for both patient and clinicians because of classical teaching has labeled postmenopausal bleed as endometrial cancer unless proven otherwise, and is one of the most common reason for referral to gynecologic evaluation. Endometrial evaluation in such cases with traditional D&C were largely replaced by office biopsy technique which include vabra aspirator, pipelle etc. Manual vacuum aspirator with Karman cannula is a safe, quick, and less painful alternative.

### KEYWORDS

postmenopausal bleeding, endometrial evaluation, manual vacuum aspiration

### INTRODUCTION

Menopause is derived from Greek word *men* (month) and *pausis* (to stop). Menopause is defined by WHO as the permanent cessation of menstruation resulting from the loss of ovarian activity<sup>1</sup>. Menopause is a phase in life that every women will go through. This phase constitutes numerous physical-mental, and psychological changes, most of the women cope well with this "change in life".

But one condition associated with post menopausal state is post menopausal bleeding (PMB) which requires immediate attention, and it is defined as any vaginal bleeding occurring after 12 months of amenorrhoea<sup>2</sup>. Nevertheless any bleeding after 6 months in a perimenopausal age should be evaluated.

Depending on the age and risk factors ,1%-14% of women with PMB will be diagnosed to have endometrial carcinoma<sup>3</sup>. But majority are benign causes. It is therefore mandatory to evaluate any women with PMB promptly, in order to exclude underlying malignancy, as early stage endometrial cancer is amenable to curative treatment during early stages.

### REVIEW OF LITERATURE

Bleeding in post menopausal patient can be due to vulval (trauma, ulcer) vaginal (prolapsed, decubitus ulcer, carcinoma) cervical (erosion, polyp, cervicitis, malignancy) uterine (atrophic endometritis, hyperplasia, polyp, malignancy) ovarian and systemic causes.

#### Most common uterine causes are

Endometrial atrophy -(60-80%)

HRT -(15-25%)

Hyperplasia- (5-10%)

Carcinoma- (10%)

Polyp (2-12%)

In 95% cases ,the first sign of endometrial carcinoma is post-menopausal bleeding, hence warrants prompt diagnostic evaluation. Endometrial sampling for histopathology is important in the assessment of PMB. Evaluation by D&C has been drastically changed following evaluation of TVS and office biopsy procedures. Although histological diagnosis is not available ,sonographic imaging is an extremely useful test in assessing PMB, because malignancy almost always associated with increased endometrial thickness. Meta analysis by Smith- Bindman et al showed ET cut off of 5mm has 96% sensitivity and 61% specificity in detecting ca endometrium, whereas multicentric study by Karlsson et al<sup>4</sup> showed better sensitivity and specificity with 4mm cut off. American college of obstetrics and gynaecology recommends that when TVS is performed for patients with PMB and an endometrial thickness of <= 4 mm is found, endometrial sampling is not required.

Out patient endometrial sampling is a well accepted first step procedure in evaluation of such cases ,without the risk of anesthesia, hospital admission etc. MVA is a novel and safe method for endometrial biopsy in office setting. The MVA is hand held plastic aspirator syringe attached to a plastic cannula of varying sizes. It consists of a 60ml syringe with double valve and improved Karman cannulae of sizes ranging from 4 to 12 mm. The vacuum generated in this syringe is identical to that produced by electrical suction apparatus viz 26 inches or 660mm Hg. The vacuum aspiration is safe ,quick and less painful than sharp curettage.

Advantages of MVA include,

- light weight, simple, portable
- no electricity required
- 360 degree rotation possible
- In case of perforation vacuum drops to <10 mmHg and thus prevent injury to bowel.
- Reusable and easy to learn

Ideal for outpatient procedure especially in low resource setting

Hemalatha et al <sup>5</sup> in 2006 compared endometrial aspiration cytology with histopathology in 100 cases of Dysfunctional uterine bleeding using menstrual regulating syringe with 4mm Karma's cannula. The technique was found to be simple, and acceptable. The material was adequate in 93% cases of cytology.

Saurez et al <sup>6</sup> in 2000 concluded That endometrial aspiration by MVA has high diagnostic value similar to D&C ,in detection of endometrial hyperplasia or cancer in patients with abnormal uterine bleeding with the advantage to be an office procedure without any risk or additional cost.

**AIMS AND OBJECTIVES**

1 To study the diagnostic efficacy of manual vacuum aspirator in evaluating the endometrial pathology ( in women with PMB by comparing it with traditional D&C.

2 To study the histopathological pattern of enometrium in PMB.

3 To study the various factors associated with endometrial pre-malignant and malignant lesions.

**MATERIALS AND METHOD**

Observational study conducted in department of OBG ,ACME Pariyaram Medical college, Kannur, Kerala for 1 year (1/12/2013 to 30 /11/2014) in women who presented with postmenopausal bleeding.

The sample size is calculated based on the formula  $3.84 * p * q / d^2 = 81$

**Inclusion criteria**

All women's with complaints of PMB( bleeding after 6 months of amenorrhoea should be evaluated.)

**Exclusion criteria**

Women with bleeding diathesis, abnormal pap smear, on anti-coagulation therapy and surgical menopause.

After taking written informed consent ,detailed history was taken, general physical examination, systemic examination and genital examination was done. Routine Pap smear was taken

Patients were subjected to endometrial aspiration using manual vacuum aspirator using 4mm canulae, sample labeled as (A) and then D&C , sample labeled as (B). Both procedures were done in OPD and no sedation was used for MVA. Histopathology report were collected. Data analysis done with SPSS version 13.

Primary outcome – measure diagnostic efficacy of MVA while comparing it with D&C.

Secondary outcome- tissue adequacy, procedural complications, factors associated with PMB and endometrial carcinoma.

**RESULTS AND OBSERVATIONS**

81 Patients were included in the study as per criteria, 9 samples were found inadequate and thus 72 were finally taken for analysis.

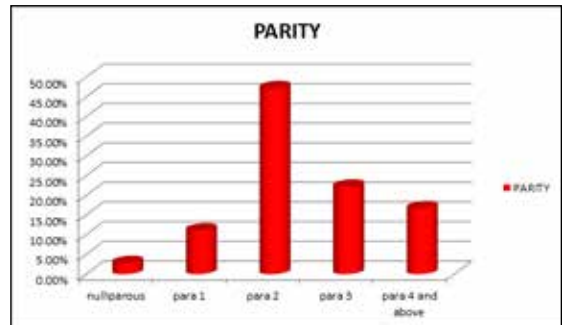
Most of the women with PMB belonged to age group of 50-54 years (54.2%). Mean age was 55.25 , lowest being 47 and highest 80.

Distribution of endometrial pattern – in age group of 45-49 , incidence of secretory endometrium was maximum(42.9%), while it was atrophic endometrium(30.8%) in 50-54 age group. Hyperplasia and carcinoma showed an increasing trend after 60 years.

Duration of menopause varied between 6 months to 25 years. And hyperplasias were common as duration of menopause increases.

**Parity and PMB incidence- chart1**

Chart 1



Medical disorder in study group- 20.8% women had hypertension, 18.1% had diabetes with hypertension, 12.5% were hypothyroid, 5.6% had diabetes. In patients with both DM & HTN , 15.4% had complex hyperplasia with atypia.

Distribution of BMI- 57% had normal BMI, 26.4% were overweight, 16.7% were obese. 50% of patients with complex hyperplasia were obese.

**Distribution of endometrial thickness- chart 2**

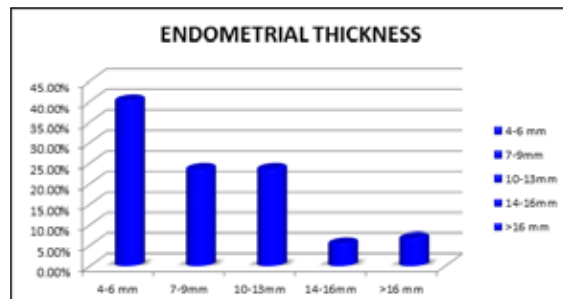
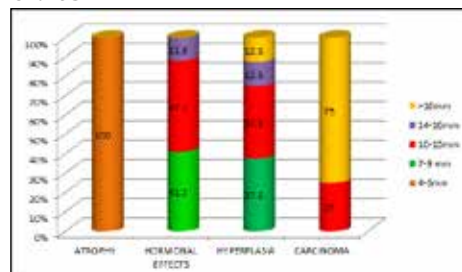


Chart2

**Correlation of ET and endometrial histopathology-chart 3**

Chart 3



As endometrial thickness increased there were more chances of hyperplasia and carcinoma. Women who had carcinoma had their endometrial thickness between 10-13mm and >16mm. p derived for endometrial thickness and its correlation with HPE was significant.

Correlation between MVA and D&C report in study group–table 1

**Table 1**

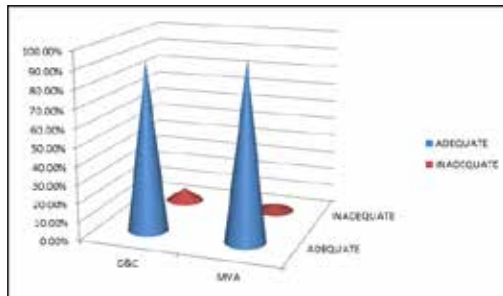
HPE	MVA	D&C
Atrophic	27(37.5%)	27(37.5%)
Secretory	7(9.72%)	8(11.11%)
proliferative	11(15.27%)	9(12.5%)

Simple hyperplasia without atypia	10(13.8%)	11(15.27%)
Complex hyperplasia without atypia	3(4.1%)	3(4.1%)
Complex hyperplasia with atypia	2(2.77%)	2(2.77%)
carcinoma	4(5.5%)	4(5.5%)
polyp	2(2.77%)	0
Disordered proliferative	6(8.33%)	8(11.11%)

100% correlation was obtained in the diagnosis of atrophy and complex hyperplasia without atypia and carcinoma.

Adequacy of tissue obtained by MVA and D&C- chart 4

Chart4



**STATISTICAL ANALYSIS -MVA IN PMB**

Sensitivity-  $TP/(TP+FN)*100=100\%$

Specificity-  $TN/(TN+FP)*100=98.1\%$

Positive predictive value-  $TP/(TP+FP)*100=95.2\%$

Negative predictive value-  $TN/(TN+FN)*100=100\%$

Diagnostic accuracy-  $(TP+TN)/(TP+TN+FP+FN)*100=98.6\%$

( p value was <0.001 which is significant)

**DISCUSSION  
EFFICACY OF MVA**

The primary outcome measured in present study was to determine the efficacy of MVA compared to D&C in evaluating endometrial pathologies in PMB. In the present study MVA had 100% correlation with D&C in detection of atrophic endometrium hyperplasia's, and carcinoma. The present study showed a sensitivity of 100% ,specificity of 98.1%, positive predictive value of 95.2% and negative predictive value of 100% and diagnostic accuracy of 98.6%.

The results are similar to study done by Thitinan Tansathit et al<sup>7</sup> in 2005 comparing Karman's cannula with D&C in AUB, where sensitivity was 89.6% and specificity of 100%.

**Tissue adequacy**

In present study adequacy of tissue sample with MVA was 96.3% which is comparable with study done by Lilli et al<sup>8</sup> in 2006 where tissue adequacy was 97.1%.

**COMPLICATIONS**

There were no intraprocedure or postprocedure complications noted, except for mild abdominal cramps which was similar to the finding in study by Zuber . Grimas D and Nicholas both showed that office endometrial smapling is effective and causes less pain than metal curette.

**CONCLUSION**

Endometrial sampling by MVA is a safe, simple, inexpensive, accurate procedure that appears to be alternative to more invasive procedures like D&C for evaluation of postmenopausal patients with abnormal uterine bleeding. The endometrial

sample so obtained is adequate for histology and shows well preserved architecture. Endometrial pathology of postmenopausal bleeding has been evaluated with MVA and hope to form a base for further studies and research purpose.

**References**

1. W.H.O Reasarch on menopause in the 1990s. Report of a WHO Scientific group. WHO Tech Report Series 1996;866:1-107.
2. Breijer MC , Timmermans A, Van Doorn HC , Mol BW, Opmeer BC. Diagnostic strategies for postmenopausal bleeding. Obstet Gynecol Int 2010;2:812-850.
3. Astrup K,Olivarius NDF. Frequency of spontaneously occurring postmenopausal bleeding in general population. Acta Obste Gynecol Scand 2004;83:203-207.
4. Gull B, Karlson B, Milsom I,Wikland M, Granberg S. Transvaginal sonography of the endometrium in a representative sample of postmenopausal women. Ultrasound Obstet Gynecol 1996;7(5):322-327.
5. Hemalatha AN, Pai MR, Raghuvveer CV. Endometrial aspiration cytology in dysfunctional uterine bleeding. Indian J Pathol Microbiol 2006;49(2):214-217.
6. Saurez R. Diagnostic evaluation of endouterine manual aspiration for detection of endometrial hyperplasia and cancer in patients with abnormal uterine bleeding. Gynecol Obstet Mex 2000;68:1-6
7. Tanshit T,Chichareon S,Tocharoenvanich S,Dechsukhum C. Diagnostic evaluation of Karman's endometrial aspiration in patients with abnormal uterine bleeding. J Obstet Gynecol 2005;31(5):480-485.
8. Lilli May Teodora- Cole, Maria Carmen H ,Fransiska Mochtar. Randomized controlled trial of Manual Vacuum Aspiration Versus Novak Curetettefor endometrial sampling. Phil J Obstet Gynecol 2006;30(3):115-119.