



Treatment of Chronic Non-Healing Leg Ulcers in Unani (Greek) System of Medicine- Case Report

ZAMIR AHMAD	Associate Professor, Department of Amraze jild wa Tazeeniyat (Unani Dermatology and cosmetology), A K Tibbiya College and Hospital, Aligarh Muslim University, Aligarh, India, * Corresponding author
HAMID ALI	Assistant Professor, Department of Ilaj bil tadbeer, National Institute of Unani Medicine, Bangalore, Karnataka, India
KEYWORDS	

Introduction:

Caring and wellbeing of the patients of non-healing ulcers are among the major concerns of the professionals, researchers and academicians because of non-availability of satisfactory management.

In absence of any satisfactory cure, it is imperative that other kind of treatment be searched and reported for the sake of suffering mankind. Classical Unani (Greek) medical literature has vast descriptions of non-healing ulcers as *Quruhe aseerul indamaal*. **To validate and document the outcome of the Unani management of non-healing ulcer, this patient was successfully treated and photographed. Written informed consent was obtained for the publication of his photographs and videos for the academic purpose.**

Case Report:

A 56 years old male patient of Non Healing Ulcers (Patient registration Number: 25994 at A&U Tibbia College Hospital, New Delhi-5) visited to Skin OPD on 20th June 2011 with the complain of a large non healing ulcer on the medial aspect of the right lower leg and small ulcer on lateral side of the same leg since 15 months. The ulcers were quite painful accompanied with crusting and oozing of yellowish fluid from the ulcers. He also presented with swelling of the leg along with redness. Some of the affected area had developed a blackish discoloration.

Prior to this visit, he was admitted at Department of Surgery, Maharaja Agrasen Hospital (ISO - 9001 certified), New Delhi-26 on 23.09.2010 with complain of Non-Healing Ulcers on the both medial and lateral aspect of Right lower leg along with redness, swelling and pain. He was investigated and diagnosed as Diabetes Mellitus type II with cellulitis with hypertension and BPH. He was reported negative for HbsAg, HCV and HIV. He was discharged on 05.10.10 with slight relief in the pain and swelling and has been advised to visit OPD after 07 days. On 14.10.10, he visited the surgical OPD as per instruction and has been referred to plastic surgery department. On examination, gangrenous changes were found there and surgical options were explained to the patient. He had been taking many medications; antibiotics, anti-inflammatory and analgesic under their treatment during these 15 months with no significant relief in the healing of ulcers.

After going through the examination and investigation, he was treated according to the basic principles of Unani (Greek) system of medicine in the following manner.

Internal medications-

Following herbs in equal ratio as a powder- 5 grams twice a day

Fumariaparviflora Linn- whole plant
Terminalia chebula Retz.- Fruit
Terminalia bellerica Roxb. Fruit
Emblica officinalis Gaertn.-Fruit
Cassia angustifolia-Leaves
Rosa damascenamill.
Decoction of following herbs-20 ml twice a day
Swertia chirata Buch.- whole plant
Fumaria parviflora Linn- whole plant
Tephrosea purpurea- whole plant
Lamprachaeniam microcephalum Benth.- whole plant
Sphaeranthus indicus Linn.- Flower
Tablet, 'Habbe Suranjan' having following ingredients -2BD
Aloe barbadensis Miller.- Extract
Anethum sowa Kurz.- Seed
Operculina turpethum (L.) - Root
Ipomoea nil (Linn.) Roth.- Seed
Merendera persica Boiss - Appendix Corn
Commiphora mukul - Resin
Pistacia lentiscus Linn- Resin
QurseKafoor, a tablet containing following ingredients - 1BD
Lactuca sativa Linn. - Seed
Portulacae oleracea Linn.- Seed
Bambusa bambos Druce.- Resin
Glycyrrhizia glabra Linn. - Root
Rosa damascena mill. - Petals of flowers,
Coriandrum sativum Linn. - Seed
Acacia arabica Willd- Gum
Armenian Bole - Mineral
Punica granatum linn. Fruit
Santalum album Linn- Fine powder of wood
Cinnamomum camphora Nees - Camphor

External medication-

1.Zimad (Local application)as a paste of following finely powdered Unani drugsin equal ratio having anti-inflammatory, antimicrobial and healing properties prepared with sesame oil was applied daily.

Cinnamomum camphora Nees -resin

Litharge- mineral

Borex- mineral

Lawsonia inermisLinn-leaves

Sulphur powder- mineral

2.Nutool (irrigation of lukewarm medicated decoction) of following herbs was done on the swollen surrounding areas of

ulcers daily.

Trigonella uncatu- Fruit

Matricaria chamomilla Linn- Flower

Solanum nigrum Linn- Whole plant.

Butea monosperma Lam- flowers

Rock salt- mineral

Takmeed barqi (exposure to infra-red lamp's light) of the ulcers was done after the debridement only.

Taaleeq (Leech therapy)

In addition to the use of internal and external Unani (Greek) therapeutic drugs, a specific Unani (Greek) regimen of Taaleeq (Leech therapy) was also applied. The leech application in the Unani (Greek) system of medicine is in practice since centuries for the evacuation of acrid matter from the affected parts besides the promotion of neo vascularisation and healing.

Varying number of leeches up to the maximum of 12 leeches at time as per the requirement in accordance with the basic principle of Unani (Greek) medicine, were applied on the sites of ulcers with the interval of 03 to 07 days as per the need of quantity of evacuation of acrid matter. The debridement was done before leech application. The used leeches were kept in water jar separately for his exclusive use.

The patient responded to this treatment and showed noticeable improvement in redness, pain, swelling and oozing within few days of starting Unani treatment. Gradually he reported visible improvement in the condition and size of ulcers.

He was repeated with the same set of medications which had benefitted him. The patient reported 25% improvement in his overall symptoms pertaining to the wounds within few weeks. To our surprise, his ulcers were completely cured within 5 months. He did not report any side effect at any time during his Unani (Greek) treatment and walked comfortably.

Discussion

The impacts of non-healing ulcer on quality of life of the patients are reflected in various review papers, which includes pain^{1,2,3,5,6} generally due to leg ulcer⁷ with no relief in 27% patients (n=60) in spite of taking analgesics⁸, restricted physical activities; walking, swimming or gardening^{9,10,11,12}, washing or bathing^{3,9,11}, holidaying or travelling^{10,11} and was frequently associated with oedema in the leg and ankle¹³, sleeping problems³ due to pain at night¹⁵, pruritus, swelling, discharge & smelling causing negative effect on social life^{11,13,14}, leading to anxiety and depression, reduced willpower, helplessness, and a sense of being unclean¹⁰.

Dressings, resting, repositioning of the leg, massage⁸, leg elevation, compression stockings, and diuretic therapy⁴ are the routine modalities in the management of non-healing ulcers, which relieved the pain and swelling only. The patients have to suffer endlessly in miserable condition. It is imperative to search alternative therapies, i.e. Unani Medicine, for the remedy. This case was photographed from commencement of the Unani (Greek) treatment of his ulcers to the ending, in order to search, validate and document the role of Unani (Greek) medicine.

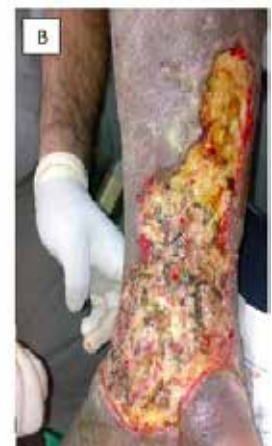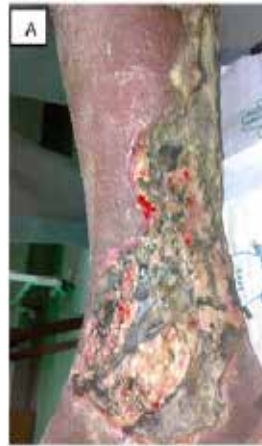The patient responded very well with Unani (Greek) medicines, which helped him to get rid of the obstinate ulcers which were troubling him since 15 months without any side effect.

Conclusion

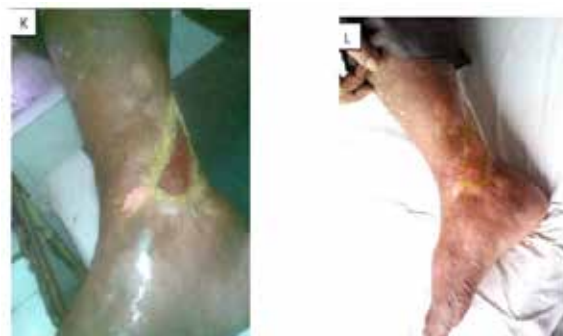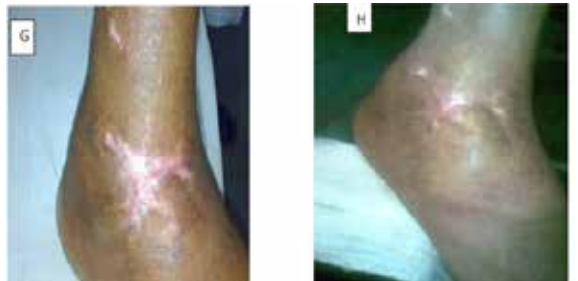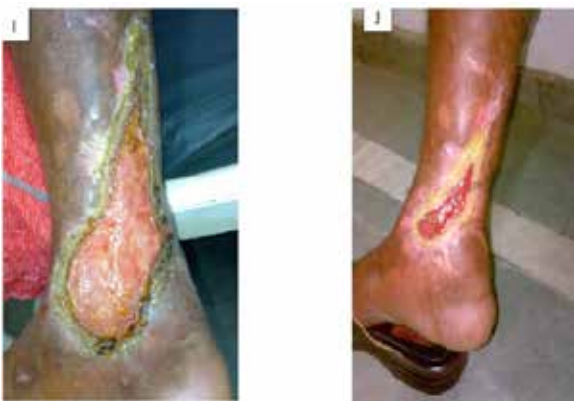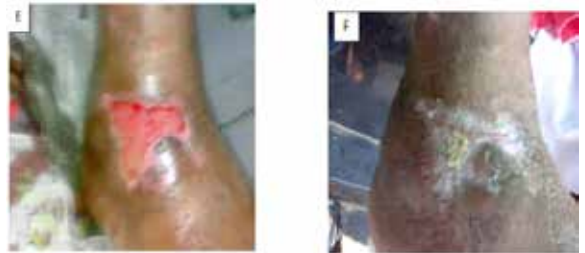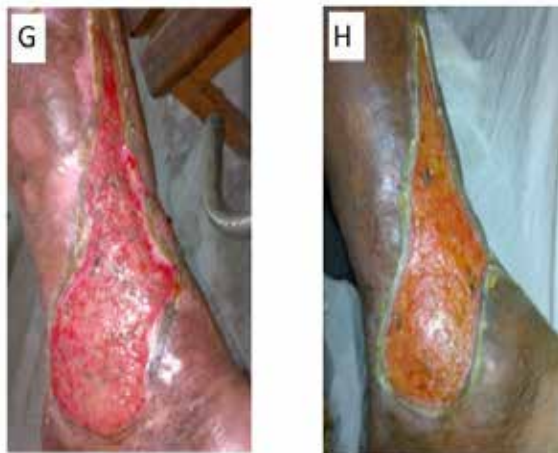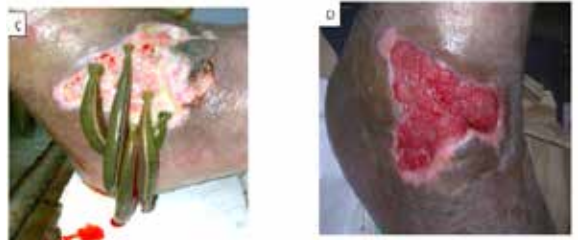
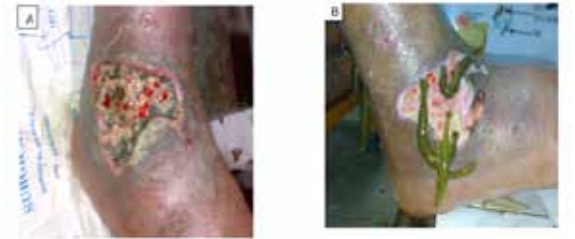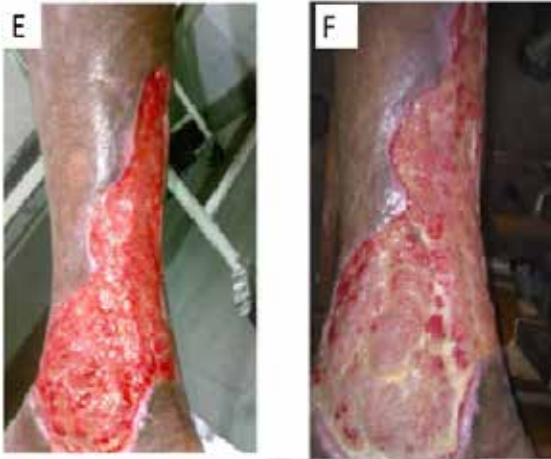Non healing ulcers can be treated safely with Unani (Greek)

system of medicine. Holistic approach with Unani (Greek) System of medicine for the management of non-healing ulcers may be utilized in future in the best interest of human suffering. Randomized control trial may be conducted to develop more effective, safe and natural drug discovery.

Photographs of the clinical presentation during management of non healing ulcer at medial aspect; A- at first visit, B-after one week, C&D- Leech applications, E to L- various stages of healing



Photographs of the clinical presentation during management of non-healing ulcer at lateral aspect; A- at first visit, B & C- Leech application, D to H- various stages of healing



References:

1. Douglas V: *Living with a chronic leg ulcer: an insight into patients' experiences and feelings.* Journal of Wound Care 2001, 10(9):355-360.
2. Hamer C, Cullum N, Roe BH: *Patients' perceptions of chronic leg ulcers.* Journal of Wound Care 1994, 3(2): 99-101.
3. Walshe C: *Living with a venous leg ulcer: a descriptive study of patients' experiences.* Journal of Advanced Nursing 1995, 22(6):1092-1100.
4. Krasner D: *Painful venous ulcers: themes and stories about living with the pain and suffering.* J Wound Ostomy Continence Nurs 1998, 25(3):158-168.
5. Hofman D, Ryan TJ, Arnold F, Cherry GW, Lindholm C, Bjellerup M, Glynn C: *Pain in venous leg ulcers.* Journal of Wound Care 1997, 6(5):222-224.
6. Charles H: *The impact of leg ulcers on patients' quality of life.* Professional Nurse 1995, 10(9):571-574.
7. Lindholm C, Bjellerup M, Christensen M, Zederfeld B: *Quality of life in chronic leg ulcer patients.* Acta Dermatology Venereal 1993, 73: 440-444.
8. Goncalves ML, de Gouveia Santos VL, de MattosPimenta CA, Suzuki E, Komegae KM: *Pain in chronic leg ulcers.* Journal of Wound, Ostomy, Continence Nursing 2004, 31(5):275-283.
9. Chase SK, Whittemore R, Crosby N, Freney D, Howes P, Phillips TJ: *Living with chronic venous ulcers: a descriptive study of knowledge and functional health status.* Journal of Community Health Nursing 2000, 17(1):1-13.
10. Hyland ME, Lay A, Thomson B: *Quality of life of leg ulcer patients: questionnaire and preliminary findings.* Journal of Wound Care 1994, 3(6):294-298.

11. Hareendran A, Bradbury A, Budd J, Geroulakos G, Hobbs R, Kenkre J, Symonds T: *Measuring the impact of venous leg ulcers on quality of life. Journal of Wound Care* 2005, 14(2):53–57.
12. Krasner D: *Painful venous ulcers: themes and stories about their impact on quality of life. Ostomy Wound Manage* 1998, 44(9):38–46.
13. Chase S, Melloni M, Savage A: *A forever healing: the lived experience of venous ulcer disease. Journal of Vascular Nursing* 1997, 10(2):73–78.
14. Hopkins A: *Disrupted lives: investigating coping strategies for non-healing leg ulcers. British Journal of Nursing* 2004, 13(9):556–563.