



Endo-Nasal Dacryocystorhinostomy With and Without Nasal and Lacrimal Flap A Clinical Study

Dr.Sonu Parmar	Senior Resident, Dept. of ENT, Dr.Sampurnanand Medical College,Raj,India
Dr.Ramdayal	Asst.Prof. Dept. of Gen.Surgery, Dr.Sampurnanand Medical College,Raj,India
Dr.Bharti Solanki	Prof. Dept. of ENT, Dr.Sampurnanand Medical College,Raj,India
Dr.Ankit Goyal	Resident, Dept. of ENT, Dr.Sampurnanand Medical College,Raj,India

ABSTRACT

EDCR (Endoscopic Dacryocystorhinostomy) is popular among the surgeons as closer of the rhinostomy opening, facial scar, psuedoepithileal fold formation, angular vein damage, CSF leak, etc. has been overcome through endonasal DCR. A growing clinical experience has confirmed the value of endoscopic DCR technique in the management of nasolacrimal duct obstruction. Although several techniques for endoscopic DCR have been described, the nasal and lacrimal mucosal flap preservation technique produces a large and stable ostium .The purpose of our study is to validate a technique described by Tsirbas and Wormald in which apposition of C- shaped nasal mucosal flap and a large anterior lacrimal sac flap. This study validates the concept of preserving the lacrimal and nasal mucosa through an endoscopic approach to treat nasolacrimal duct obstruction. Early and controlled lining of the fistula with mucosal flaps appears to prevent closer of the ostium and leads to a high success rate and we suggest preservation of mucosal flap for achieving successful clinical outcome.

KEYWORDS

Endonasal Dacryocystorhinostomy, psuedoepithileal fold, obstruction, mucosal flap, lacrimal sac.

INTRODUCTION

Endoscopic Dacryocystorhinostomy has gained a lot of attention among the surgeons since the outcome are comparable to the external approach. Closer of the rhinostomy opening, facial scar, psuedoepithileal fold formation, angular vein damage, CSF leak, etc. has been overcome through endonasal DCR. A growing clinical experience has confirmed the value of endoscopic DCR technique in the management of nasolacrimal duct obstruction. Refinements in technique and instrumentation coupled with an improved understanding of the endoscopic surgical anatomy are largely responsible for the excellent success rates now reported equivalent to the external approach.^{1,2,3} Although several techniques for endoscopic DCR have been described, the nasal and lacrimal mucosal flap preservation technique produces a large and stable ostium⁴. The purpose of our study is to validate a technique described by Tsirbas and Wormald in which apposition of C- shaped nasal mucosal flap and a large anterior lacrimal sac flap.

METHOD & MATERIAL

The present study was conducted in DEPARTMENT OF ENT, MDM Hospital and DR. S.N. MEDICAL COLLEGE JODHPUR RAJASTHAN (India) .We included 50 patients in this study. They were divided randomly into 2 groups equally. Group A-during the surgery posterior nasal and anterior lacrimal mucosal flap is completely removed while in the Group B, the flap is preserved. The patients were postoperatively followed for a period of about 24 months. The results obtained were finally compared.

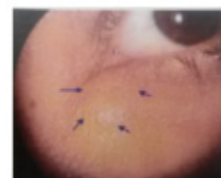
SURGICAL TECHNIQUE

In all patients endoscopic DCR was performed under general anaesthesia with full unit of endoscopic and medical monitor system. Each patient was placed in supine position with head slightly elevated to decrease the venous pressure at the operation site. To decongest nasal mucosa pledgets soaked in 20 ml 4% lignocaine with 1ml adrenaline(1:200000) were used in packing nose. Following this 10ml 2% lignocaine with 1ml adrenaline(1:200000) was injected locally lateral nasal mu-

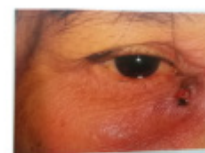
cosa anterior to middle turbinate.



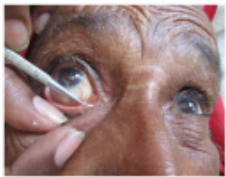Mucocele



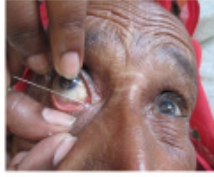Pyocele



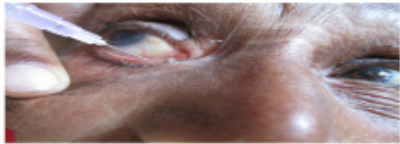With 0 and 30 degree endoscopes , U shaped nasal mucosal flap was created by giving incision with sickle knife in front of axilla of middle turbinate consisting of upper horizontal, middle vertical and lower horizontal part. Freer's elevator was then used to elevate the flap and make a subperiosteal plane along the incision. The flap was directed towards the frontal process of maxilla and was mobilized until lacrimal bone identified. Kerrison punch forcep was used to remove the part of lacrimal bone and frontal process of maxilla. The lacrimal sac is now identified by external compression. Lacrimal lower puncta was dilated with dilator and later on lacrimal probe was introduced to produce a tenting in the sac. The sac was vertically incised using sickle knife and the incision extended upwards and downwards. Normal saline was instilled through puncta to check free flow. Group A-during the surgery posterior nasal and anterior lacrimal mucosal flap is completely removed while in the Group B, the flap is preserved and approximated with middle turbinate. Finally nose was pack tightly with ointment pack



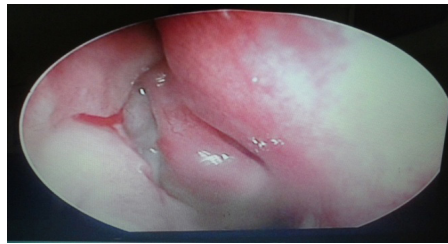Lacrimal lower punctum dilator



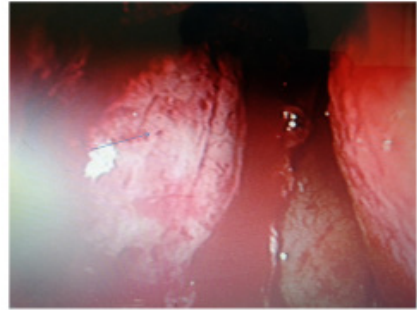
Lacrimal probing



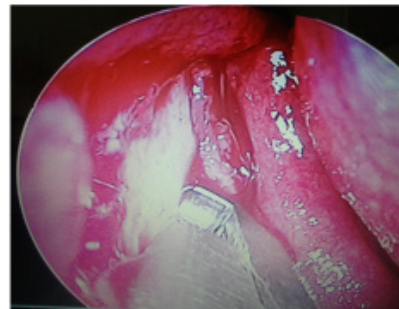Lacrimal syringing showing regurgitation of saline from upper punctum



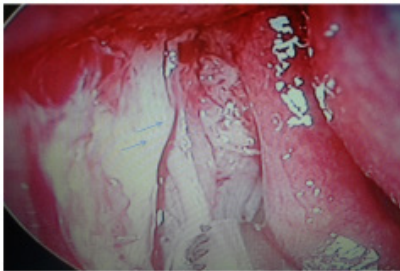
The lacrimal sac identified by external compression



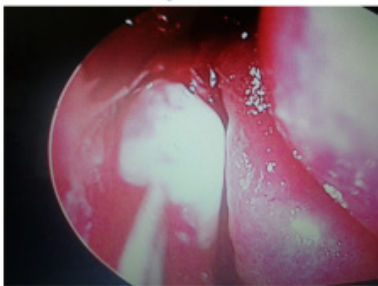
Kerrison punch forcep used to remove the part of lacrimal bone and frontal process of maxilla



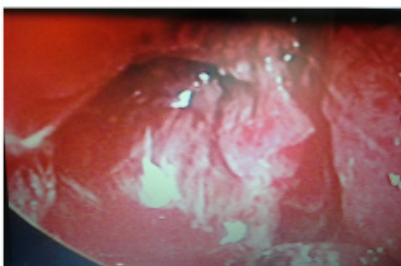
Freer's elevator was then used to elevate the flap and make a subperiosteal plane



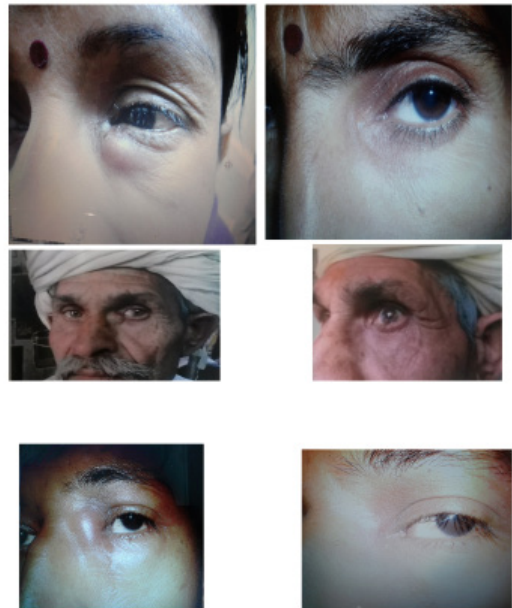Lacrimal lower puncta dilated with dilator. The sac vertically incised using sickle knife and the incision extended upwards and downwards



Normal saline was instilled through puncta to check free flow



Pre and post operative results



RESULTS

Majority of the cases were >60 years of age. Youngest patient was 6 years and oldest was 80 years. Female were affected more often than male and male female ratio was 1:1.9 in out of 50 patients. In majority of cases (46%) disease was present on right side. Most of the patients (62%) were from rural area. Epiphora (100%) was most common presenting symptom in both groups. Only few patients (8%) underwent simultaneous septoplasty procedure in group A. IN 2 cases

(4%) we had intraoperative complication like difficult to remove lacrimal bone out of 50 patients. In the postoperative period 16(64%) patients in Group A and 15(60%) patients in Group B had lid oedema which subsides after a day or two with routine treatment. All patients will be followed up at OPD at weeks 1st and 2nd, months 1st, 2nd, 3rd and then every 3rd month. History regarding symptomatic improvement will be taken. Nasal endoscopic examination will be performed in post-operative visit. More crust granulation and synechia were present in Group A as compared to Group B.

Post operative findings at end of 3rd month

Particulars No. Of patients %		Group A		Group B		
		No. Of patients	%			
Lacrimal syringing	Spontaneous flow	22	88%	23	92%	
	Flow with pressure	1	4%	1	4%	
	No flow	2	8%	1	4%	
Endoscopic finding	Synechia	4	16%	2	8%	
	Crust	2	8%	0	0%	
	Granulation	3	12%	2	8%	
	Rhinos-tomy opening	Patent	22	88%	23	92%
		Closed	3	12%	2	8%

Post operative findings at end of 1 year

Particulars No. Of patients %		Group A		Group B		
		No. Of patients	%			
Lacrimal syringing	Spontaneous flow	7	63.63%	5	83.33%	
	Flow with pressure	2	18.18%	0	0%	
	No flow	2	18.18%	1	16.66%	
Endoscopic findings	Synechia	2	18.18%	0	0%	
	Crust	1	9.09%	0	0%	
	Granulation	3	27.27%	1	16.66%	
	Rhinos-tomy opening	Patent	8	72.72%	5	83.33%
		Closed	3	27.27%	1	16.66%

CONCLUSION

This study validates the concept of preserving the lacrimal and nasal mucosa through an endoscopic approach to treat nasolacrimal duct obstruction. Early and controlled lining of the fistula with mucosal flaps appears to prevent closer of the ostium and leads to a high success rate and we suggest preservation of mucosal flap for achieving successful clinical outcome.

REFERENCES:

- [1] Cokkeser Y, and Evreklioglu ERH. Comperative external versus endoscopic dacryocystorhinostomy: Results in 115 patients (130 eyes) Otolaryngol Head Neck Surgery(2000) 123: 488-491
- [2] Ben Simon GJ, Joseph J, Lee S, et al. External versus endoscopic dacryocystorhinostomy for acquired nasolacrimal duct obstruction in a tertiary referral center. Ophthalmology (2005) 112:1463-1468
- [3] Yigit O, Samancioglu M, Taskin U, et al. External and endoscopic dacryocystorhinostomyin chronic dacryocystitis: Comparison of results . Eur Arch otorhinolaryngol (2007)264:879-885.
- [4] Mann BS, and Wormald PJ.Endoscopic assessment of the dacryocystorhinostomy ostium after endoscopic surgery. Laryngoscope(2006) July;116:1172-1174