



Magnesium Sulphate Versus Dexmedetomidine as Adjuvant to Bupivacaine in Open Transversus Abdominis Plane Block for Lscs

Dr. MADHU VELAYUDHAN

MD, DNB, Associate professor, Department of Anaesthesiology, Sree Gokulam Medical College and Research Foundation, Trivandrum

Dr. DAVE STENI POTHEN

MBBS, Department of Anaesthesiology, Sree Gokulam Medical College and Research Foundation, Trivandrum

KEYWORDS

INTRODUCTION:

Pain in abdominal surgeries is related to somatic pain signals derived from the abdominal wall. Inadequate post operative pain control leads to patient discomfort, immobilisation, thromboembolic phenomenon and pulmonary complications. TAP block was first described by Rafi in 2001, involves injection of local anaesthetic in the neurofascial plane between the internal oblique and transversus abdominis muscle layers, with the aim of anaesthetising the intercostal nerves (T6-T11), subcostal nerve (T12) and ilioinguinal and iliohypogastric nerves (L1) supplying the anterolateral abdominal wall.

TECHNIQUES

- Loss of resistance technique through anatomical landmarks of triangle of Petit to get a double 'pop' to place the local anaesthetic
- A subcostal technique – to provide analgesia for upper abdominal surgeries not extending below T10 dermatome or more lateral than anterior axillary line
- Ultrasound guided TAP block – improves the accuracy of the block
- Open surgically administered TAP block

ADVERSE EFFECTS OF TAP BLOCK

- liver injury
- femoral nerve palsy
- Peritoneal puncture
- difficulty in obese patients
- Not effective for upper abdominal surgeries as the lower six thoracic nerves are inadequately blocked

Surgically administered open TAP blocks are more accurate. The operating surgeon identifies the anatomical layers under direct vision when closing the abdomen and placing the local anaesthetic accordingly. This has the advantage of avoiding inadvertent injection into the incorrect layer or damaging deeper structures.

Dexmedetomidine is a newer alpha 2 adrenergic agonist, with more specificity for alpha 2 receptors. It prolongs analgesia when used in neuraxial and peripheral nerve block. When added to a local anaesthetic, it prolonged the action of the local anaesthetic.

Magnesium sulphate is a common pharmaceutical preparation of magnesium, commonly known as Epsom salt which acts by NMDA receptor antagonism. It regulates the calcium influx into the cells.

OBJECTIVES

- To compare magnesium sulphate and dexmedetomidine as adjuvants to bupivacaine during open TAP block for LSCS patients

- Time to first analgesia, pain scores at 2,6,12,24 hours, haemodynamic data and side effects are considered

MATERIALS AND METHODS

STUDY DESIGN: Prospective randomized double blinded study

STUDY SETTING :Dept of Anesthesiology,SreeGokulam Medical College and Research Foundation, Venjaramoodu, Trivandrum

STUDY SUBJECTS: Patients 18 - 30 years, ASA I undergoing LSCS

STUDY PERIOD :September 2015 to August 2016

SAMPLE SIZE: Total of 50 patients with 25 in each group. Patients were allocated randomly

INCLUSION CRITERIA

- 18 - 30 years
- ASA I
- Elective LSCS under LSAB

EXCLUSION CRITERIA

- <18 , >30 years
- ASA II or above
- Patient refusal

METHODOLOGY

After getting the institutional ethical committee clearance, and the informed consent of the patient, the was kept nil per oral for 8 hours. An intravenous access was secured using an 18 gauge cannula. Standard monitors were attached and heart rate, BP, oxygen saturation, ECG and end tidal CO2 were monitored. Patients underwent LSCS under LSAB through a pfannenstiell incision. At the time of wound closure, following peritoneal closure, drugs were given into bilateral Transversus Abdominal Plane under direct vision.

- Patients were allocated into two groups by block randomisation.
- Group M – 20 ml 0.25% Bupivacaine + 20mg/kg Magnesium sulphate given
- Group D – 20 ml 0.25% Bupivacaine + 0.5 mcg/kg Dexmedetomidine given

Time to first analgesia, pain scores at 2/6/12/24 hours, haemodynamic data, side effects were noted. Time to first analgesia is the time after which first dose of rescue analgesia is given. Pain scores at 2/6/12/24 hours were noted on the basis of visual analog scale (VAS). Haemodynamic data: HR, NIBP and MAP were noted after 2/6/12/24 hours. Side effects: Sedation was assessed using in-

verted observer assessment of alertness scale. PONV was assessed using PONV assessment scale.

The values were entered into a chart and statistical analysis was done by SPSS version 20.0. The hypothesis was tested using student t test.

RESULT

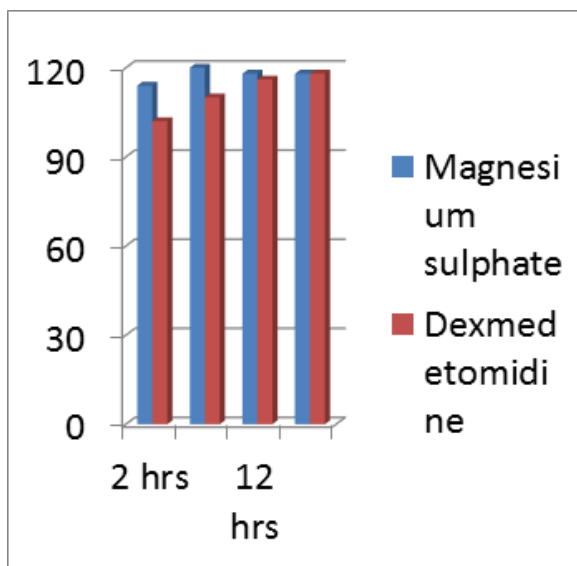
A comparison of patient characteristics are shown in table. Age, weight, height and frequency of pregnancy were similar in both the groups with no significant statistical difference.

	Group M	Group D	p Value
Age	27.77+/-4.13	28.89+/-5.5	0.341
Weight	73.14+/-10.68	75.97+/-10.67	0.271
Height	163+/-12	165+/-12	0.34
Pregnancy frequency	2.46+/-1.07	2.49+/-1.1	0.912
	Group M (n = 25)	Group D (n = 25)	p Value
Time to first analgesia	380 ± 83	910 ± 153	0.001
VAS 2	1.42 ± 0.12	1.4 ± 0.11	0.22
VAS 6	3.81 ± 1.11	1.49 ± 0.13	0.01
VAS 12	3.5 ± 0.48	2.57 ± 0.31	0.02
VAS 24	3.41 ± 0.64	3.23 ± 0.55	0.28

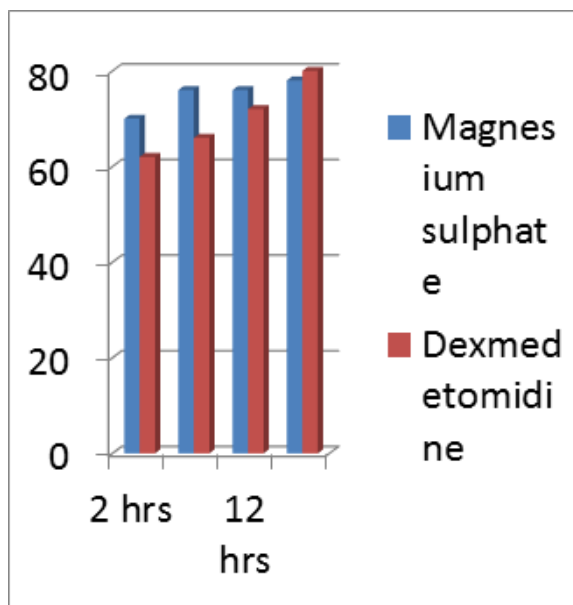
No statistically significant differences were observed in age, body weight, or pregnancy frequency between the groups. Statistically significant difference in pain scores were observed at 6 hours and 12 hours. Pain scores were statistically insignificant at 2 hours and 24 hours.

	Group M (n=25)	Group D (n=25)	p Value
HR 2	69.24 ± 6.62	61.64 ± 2.7	0.001
HR 6	87.24 ± 9	63.24 ± 2.74	0.001
HR 12	73.32 ± 4.6	72.92 ± 3.95	0.06
HR 24	73.80 ± 3.94	74.12 ± 3.5	0.38

	Group m (n=25)	Group D (n=25)	p Value
MAP 2	66.34 ± 3.91	62.76 ± 2.16	0.034
MAP 6	68.29 ± 2.96	63.41 ± 1.83	0.02
MAP 12	68.22 ± 3.07	67.37 ± 3.14	0.074
MAP 24	70.18 ± 3.02	69.92 ± 2.9	0.238



Systolic BP



Diastolic BP

Statistically significant difference in heart rate and blood pressure were observed at 2 hours and 6 hours for which no interventions were required.

All the 50 members in the study had a PONV score of 0 and OAA/S score of 5 throughout the first 24 hours of the study.

DISCUSSION

TAP block involves injection of local anaesthetic between the internal oblique and transversus abdominis muscle layers, with the aim of anaesthetising the intercostal nerves (T6-T11), subcostal nerve (T12) and ilioinguinal and iliohypogastric nerves (L1) supplying the anterolateral abdominal wall. Initially, the block used surface landmarks of the triangle of Petit located along the mid axillary line bounded posteriorly by latisimus dorsi, superiorly by external oblique and inferiorly by iliac crest and a double fascial 'pop' to guide placement of the local anaesthetic. Ultrasonography has been used to improve the accuracy of TAP block. A subcostal technique provides analgesia for upper abdominal surgeries not extending below T10 dermatome or more lateral than anterior axillary line. Adverse effects of these techniques include liver injury, femoral nerve palsy and difficulty in obese patients. TAP blocks administered through triangle of Petit is not effective for upper abdominal surgeries as the lower six thoracic nerves are inadequately blocked. Surgically administered TAP block are more accurate and prevents inadvertent injection into the incorrect layer or damage to deeper structures.

Dexmedetomidine is an alpha 2 adrenergic agonist which decrease the sympathetic tone and attenuate the haemodynamic and neuroendocrine response to stress. It provide sedation and analgesia by acting on the alpha 2 receptors in locus coeruleus and spinal cord thereby increasing GABA and galanin release and inhibiting ion conductance through calcium channel. It preserves psychomotor function and benefits in prophylactic and adjuvant treatment of perioperative myocardial ischaemia. It is being increasingly used in pain management and regional anaesthesia. Dexmedetomidine act on alpha 2c and alpha 2a receptors in the dorsal horn thereby decreasing release of substance P and glutamate and hyperpolarisation of neurons. It prolongs the action of local anaesthetic when given as an adjuvant. Sensory block is more via the unmyelinated C fibres. It also has an opioid sparing effect. Common adverse effects include hypotension and bradycardia.

Magnesium sulphate is an NMDA receptor antagonist. It regulates calcium influx into cells thereby increasing analgesic effects of opioids.

In this study, statistically significant difference was noted in the time to first analgesia and also in the pain scores at 6 hours and 12 hours. First dose of rescue analgesia was given after 15 hours and 10 minutes +/- 153 minutes, when dexmedetomidine was added as an adjuvant to bupivacaine for TAP block, whereas the first dose of rescue analgesia had to be given at 6 hours and 20 minutes +/- 83 minutes when magnesium sulphate was used as an adjuvant. Total opioid requirement during the first 24 hours was 50 mg of tramadol, when dexmedetomidine was used as an adjuvant, whereas 100mg of tramadol had to be used when magnesium sulphate was used as an adjuvant. Statistically significant difference was noted in the heart rate and BP at 2 hours and 6 hours, but no interventions were needed for the same. No side effects were noted with both the drugs during the study period. Hence Dexmedetomidine produces a longer duration of post op analgesia with no deleterious effects on haemodynamic status and no side effects compared to magnesium sulphate, when added to bupivacaine for an open TAP block.

References:

1. Shelly Rana, Ravinder Kumar Verma, Jai Singh et al. Magnesium sulphate as an adjuvant to bupivacaine in ultrasound guided TAP block in patients scheduled for total abdominal hysterectomy under subarachnoid block. *Indian journal of anaesthesia*. 2016 march; 60(3): 174-179.
2. Mridu Paban Nath, Rakesh Garg, Tapan Talukdar, Dipika Choudhary, Anulekha Chakrabarty. To evaluate the efficacy of intrathecal magnesium sulphate for hysterectomy under subarachnoid block with bupivacaine and fentanyl: A prospective randomized double blind clinical trial. *Saudi journal of anaesthesiology*. 2012 Jul-Sep; 6(3): 254-258.
3. Waleed A. Almarakbi, Abdullah M. Kaki. Addition of dexmedetomidine to bupivacaine in transversus abdominis plane block potentiates post-operative pain relief among abdominal hysterectomy patients: A prospective randomized controlled trial. *Saudi journal of anaesthesiology*. 2014 Apr-Jun; 8(2): 161-166.
4. Sandhya Agarwal, Ritu Aggarwal, Praveen Gupta. Dexmedetomidine prolongs the effect of bupivacaine in supraclavicular brachial plexus block. *Journal of anaesthesiology clinical pharmacology*. 2014 Jan-Mar; 30(1): 36-40.
5. Vinit K. Srivastava, Abhishek Mishra, Sanjay Agrawal, Sanjay Kumar, Sunil Sharma, Raj Kumar. Comparative Evaluation of Dexmedetomidine and Magnesium Sulphate on Propofol Consumption, Haemodynamics and Post-operative Recovery in Spine Surgery: A Prospective, Randomized, Placebo Controlled, Double-blind Study. *Advanced pharmaceutical bulletin* 2016 Mar; 6(1): 75-81.
6. David H. Chestnut. *Chestnut's Obstetric anaesthesia principles and practice*.
7. Sol M Schneider. *Anaesthesia for obstetrics*.
8. Ronald D. Miller. *Miller's anaesthesia*.