



A large mucinous cystadenoma of ovary in an adolescent girl- A Case Report

Dr Sanjaya Sharma Professor & HOD, MLB Medical College Jhansi, Uttar Pradesh (India).

Dr. Vidya Chaudhary Associate Professor, MLB Medical College Jhansi, Uttar Pradesh (India).

Umesh Kumari Yadav Junior Resident-3, MLB Medical College Jhansi, Uttar Pradesh (India).

ABSTRACT

Huge benign tumors of ovary are rare in today's modern world due to improved diagnostic tools and general awareness. We have reported a case of 15 years old girl with a 5 month history of increasing abdominal girth and later on respiratory discomfort. Diagnosis of mucinous cystadenoma was made on the basis of history, clinical examination, trans abdominal ultrasound and histopathological study of excised surgical specimen. Patient underwent exploratory laprotomy, left salphingo-opherctomy was done. Her post-operative period was uneventful.

KEYWORDS

Mucinous Cystadenoma, Exploratory laparotomy, Salphingo-opherctomy

Introduction

Mucinous cystadenomas make up 15% - 20% of all ovarian tumors. They often become very large and can extend up into the abdomen. About 80% of mucinous tumors are benign, 10% are border-line and 10% are malignant. Although benign ovarian mucinous tumors are rare at the extremities of age, before puberty and after menopause, they are common between the third and the fifth decades⁴. The most frequent complications of benign ovarian cysts, in general, are torsion, hemorrhage and rupture. Pseudomyxoma peritonei can result if the tumor ruptures and spills its contents into the abdomen. This report presents a case of a large ovarian mucinous cystadenoma in an Indian adolescent girl.

Case Report

A 15 years old girl presented to our outpatient department with a history of progressive abdominal distension from 5 months and respiratory discomfort since a month. On clinical examination patient was emaciated, abdomen was grossly distended, making overlying skin thin and veins distended & prominent, massive ascites with obvious fluid thrill. A football size mass occupying the lower abdomen, more towards left side was present. Ultrasound revealed left side large ovarian cyst with massive ascites. Patient was counselled and signed information for surgical exploration.

Under spinal anaesthesia, an initial midline subumbilical incision was made and 12 litres of yellowish mucinous fluid was suctioned. A huge cystic mass was noticed arising from the left ovary. Later on, the incision was extended up, about 5 cm below xiphisternum, to deliver the cystic mass intact without exposed it to the risk of rupture intraperitoneally. The outer surface of the mass was smooth and intact all-around without external growths or adhesions. The uterus, right adnexa, and appendix were looking healthy. An abdominal drain was placed in situ for 6 days. The post-operative period was uneventful. Biopsy report revealed benign mucinous cystadenoma.

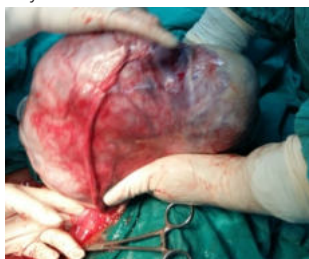

Fig. 1 Intraoperative Image- Showing stretched left fallopian tube & Ovarian mass

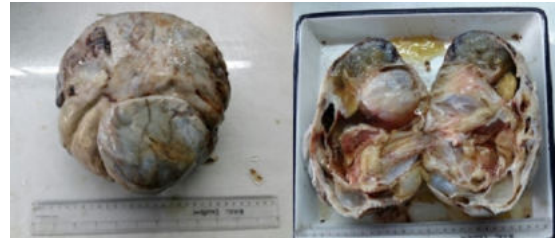

Fig. 2 Gross Specimen & Cut section showing multiple fluid filled cysts

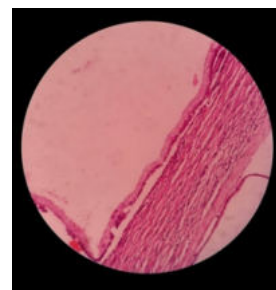


Fig. 3 Histology- Showing non ciliated columnar epithelial lining

Discussion

There are four major categories of ovarian tumors:

- 1) Epithelial tumors (65% - 75%)** — serous or mucinous cystadenoma/carcinoma, clear cell carcinoma, Brenner tumor;
- 2) Germ cell tumors (15%)** — dysgerminoma, embryonal cell cancer, choriocarcinoma, teratoma;
- 3) Sex-chord-stromal tumors (5% - 10%)** — granulosa cell tumor, thecoma, fibroma;
- 4) Metastatic tumors (10%)** — uterine, stomach, colon, breast, lymphoma.

These tumors are usually evaluated using ultrasound, CT scan, or MRI. Findings on imaging studies are nonspecific. These ovarian tumors may be multi-septated, cystic masses with thin walls. They

may contain varying amounts of solid tissue which consists of proliferating stromal tissue, papillae, or malignant tumor cells. Tumour markers may also aid us in telling us the origin of the tumour. Mucinous cystadenomas are divided into three categories: benign, borderline, and malignant. Survival is largely dependent on the histology of the tumor. 10 year survival rate of 100% for benign tumors, 60% for borderline tumors, and only 34% for the malignant subtype. Benign mucinous tumors tend to present earlier, while malignant tumors are often seen later in life. Benign mucinous cystadenomas comprise 80% of mucinous ovarian tumors and 20% - 25% of benign ovarian tumors overall. The peak incidence occurs between 30 - 50 years of age. Benign tumors are bilateral in 5% - 10% of cases. Borderline mucinous cystadenomas make up about 10% of mucinous ovarian neoplasms and are bilateral in 10% of cases. Malignant mucinous cystadenomas are rare, and encompass 10% of mucinous ovarian tumors and 5% - 10% of primary malignant ovarian neoplasms overall. They are bilateral in 15% - 30% of cases and have a peak incidence between 40 - 70 years of age. Giant ovarian tumours have become rare in current medical practice, as most cases are discovered early during routine check-ups. Detection of ovarian cysts causes considerable worry for women because of fear of malignancy, but fortunately the majority of ovarian cysts are benign. These giant tumours may be associated with pressure symptoms, urinary tract changes, respiratory embarrassment and debilitation. While operating on such tumours care has to be taken to manage these complications as well as the problems associated with sudden decompression of such large tumours. Histologically, mucinous cystadenoma is lined by tall columnar non-ciliated epithelial cells with apical mucin and basal nuclei. 80% tumours are cystadenomas while the remaining 20% is of the borderline variety, noninvasive (intraglandular; intraepithelial) carcinomas, or invasive carcinomas. The borderline tumors may be of intestinal type or mullerian (endocervical-like) type. The intestinal-type tumors are by far the most common. Mucinous cystadenoma is a benign ovarian tumor. It is reported to occur in middle-aged women. It is rare among adolescents or in association with pregnancy. On gross appearance, mucinous tumors are characterized by cysts of variable sizes without surface invasion. Only 10% of primary mucinous cystadenoma is bilateral. In our case, the tumor was unilateral, affecting the left ovary. The cyst was filled with sticky gelatinous fluid rich in glycoprotein. Management of ovarian cysts depends on the patient's age, the size of the cyst and its histo-pathological nature. Conservative surgery as ovarian cystectomy and salpingo-oophorectomy is adequate for benign lesions.

Conclusions

Management of ovarian cysts depends on the patient's age, the size of the cyst and its histopathological nature.

Conservative surgery as in ovarian cystectomy and salpingo-oophorectomy is adequate for benign lesions. For large ovarian masses with a risk of malignancy we suggest laparotomy and intraoperatively to follow the oncologic protocols, which included careful intraperitoneal exploration and a biopsy of the diaphragm, the omentum majus, the Pouch of Douglas and right and left side colon douche. The histopathological workup of our case revealed a mucinous cystadenoma.

This disease has a significant biological/physiological and psychological impact on the patient as described above and for these reasons we suggest a multidisciplinary approach so that the collaboration of different specialists can create the optimal conditions to manage the perioperative period by trying to minimize the risk of the complications.

References

1. Vizza, E., Galati, G.M., Corrado, G., Atlante, M., Infante, C. and Sbiroli, C. (2005) Voluminous mucinous cystadenoma of the ovary in a 13-year-old girl. *Journal of Pediatric and Adolescent Gynecology*
2. Mittal, S., Gupta, N., Sharma, A.K. and Dadhwal, V. (2008) Laparoscopic management of a large recurrent benign mucinous cystadenoma of the ovary. *Archives of Gynecology and Obstetrics*
3. Crum, C.P., Lester, S.C. and Cotran, R.S. (2007) Pathology of female genital system and breast. In: Kuma, V., et al., Eds., Robbins' basic pathology, 8th Edition,

4. Saunders/Elsevier, Philadelphia.
5. Ioffe, O.B., Simsir, A. and Silverberg, S.G. (2000) Pathology. In: Berek, J.S. and Hacker, N.F., Eds., *Practical gynaecologic oncology*, Lippincott Williams & Wilkins Company, Philadelphia
6. Scully, R.E. (1987) Classification of human ovarian tumors. *Environmental Health Perspectives*
7. Hart, W.R. (2005) Mucinous tumors of the ovary: A review. *International Journal of Gynecological Pathology*
8. Alobaid, A.S. (2008) Mucinous cystadenoma of the ovary in a 12-year-old girl. *Saudi Medical Journal*
9. Yenicesu, G.I., Cetin, M., Arici, S. (2009) A huge ovarian mucinous cystadenoma complicating pregnancy: A case report. *Cumhuriyet Medical Journal*