



## A Study of twenty consecutive case of unstable Intertrochanteric fracture treated with long Proximal Femoral Nail: A Clinical outcome

<b>Dr. Anshul Sharma</b>	3rd year P.G. student, M.S. Orthopaedics, Mahatma Gandhi Medical College and Hospital, Sitapura, Jaipur, India.
<b>Dr. A.K. Mathur</b>	Professor and Unit Head, Orthopaedics Department, Mahatma Gandhi Medical college and Hospital, Sitapura, Jaipur.
<b>Dr. Mohit kumar</b>	Associate Professor, Orthopaedics Department, Mahatma Gandhi Medical college and Hospital, Sitapur, Jaipur.
<b>Dr. Anil kala</b>	Assistant professor, Orthopaedics Department, Mahatma Gandhi Medical college and Hospital, Sitapur, Jaipur.
<b>Dr. S.P.Gupta</b>	Professor and HOD, Orthopaedics Department, Mahatma Gandhi Medical college and Hospital, Sitapur, Jaipur.

### ABSTRACT

**Background:** Intertrochanteric fractures have very high incidences in elderly. Conservative and operative management is available to treat these fractures. Conservative management could result in delayed union, malunion and shortening of limb. Various operative method are available like extramedullary and intramedullary fixation. The surgical management and outcome in intertrochanteric fracture using long proximal femoral nail is the aim of our study.

**Material and Method:** We are presenting twenty (20) consecutive cases of closed intertrochanteric fracture of either sex for whom follow up was done up to six (6) months.

**Results:** Closed reduction was done in nineteen (19) cases before internal fixation and one (1) case had failed closed reduction for which open reduction was done followed by internal fixation. These twenty (20) cases of intertrochanteric fracture operated with long proximal femoral nail were followed up to six (6) months. We found excellent to good results in eighteen (18) cases and good result in two (2) cases without any incidences of complication like varus instability, delayed union except for a few technical problems.

**Conclusion:** Patients with intertrochanteric fracture treated with minimal invasive method with long proximal femoral nail have shown good to excellent results which indicates PFN is a safe and successful method to treat intertrochanteric fracture.

### KEYWORDS

Intertrochanteric fractures, Proximal femoral nail, Harris hip score, Fracture fixation.

### Introduction:

Intertrochanteric fractures are injuries that affect both the elderly and young individuals. In young individuals injury results from high energy trauma and in elderly individuals usually fractures are of osteoporotic bone, resulting from trivial trauma.<sup>1</sup> Intertrochanteric fractures are more common in elderly females. Elderly people with low bone mineral density are prone for unstable fracture.<sup>2</sup> It can be managed both conservatively and surgically. DHS is considered as the gold standard treatment.<sup>3</sup> Treatment of choice for both displaced and undisplaced intertrochanteric fractures is open reduction and internal fixation. However these fractures are often associated with complications like malunion, delayed union or nonunion resulting from fixation failure or implant failure. A lack of satisfactory implant in surgical management of unstable intertrochanteric fractures has led to series of evolution in designing a perfect implant. In view of these considerations, the study of surgical management of intertrochanteric fractures by minimal invasive technique using proximal femoral nail is done.

### Material and Method:

This prospective study was conducted in our hospital from January 2015 to June 2016. During this period, a total of 20 cases of unstable intertrochanteric fractures of age 18 or above of either sex were evaluated. Only closed fractures were included for whom follow up was done up to six months. Pathological, compound fractures were excluded. Pre operative assessment was done by knowing mode of injury, routine investigations, radiological findings like neck-shaft angle, medullary canal size and any proximal femoral deformity. In our study, PFN had, proximal part diameter is of 17 mm, mediolateral angulation is 6 degree and neck shaft angle of 135 degree with superior Derotational screw

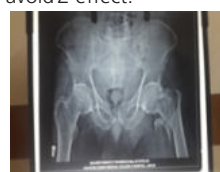and lower compression screw.

### Surgical management:

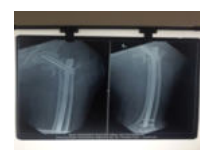Supine position was taken on the fracture table. Proper C- arm positioning was taken in both AP and lateral view. Trunk was abducted at waist by 15 degree to contra lateral side and adduction of affected limb was done to access tip of trochanter. All these patients were treated by minimal invasive technique using proximal femoral nail by closed reduction taking lateral approach. These patients were followed up to six month at interval of 6 weeks, 12 weeks, 24 weeks.

### Salient feature:

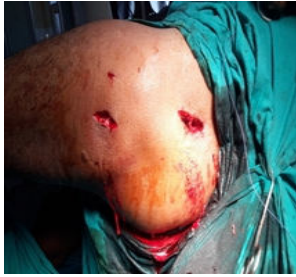Entry point is very important. It is taken over the tip of trochanter or better slightly over medial aspect of the tip of trochanter. Derotational screw should be inserted first and then the compression screw is placed after placing the guide wires in proper position. Proper anteversion of femoral neck is taken care of and varus reduction has to be avoided. Compression screw should be engaging the subchondral bone of head of femur. However penetration of the joint must be avoided. Derotational screw should be at least 10 to 15 mm shorter than compression screw to avoid Z-effect.



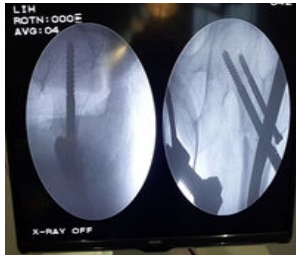
**Fig 1: Preop xray of left hip with femur**



**Fig 2: Immediate post op xray Showing intertrochanteric fracture**



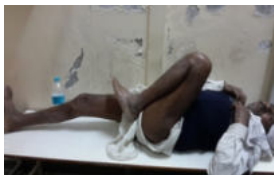**Fig 3: Intra op image LEFT HIP**



**Fig 4: C- arm image**

### Result and Discussion:

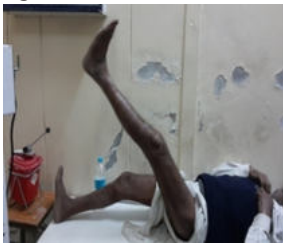These twenty (20) patients were operated and after six (6) months of follow up, the results were good to excellent in eighteen(18) patients and good in two(2) patients according to Harris Hip Score.<sup>11</sup> In this study twelve (12) were male patients and eight (8) were female patients. Fifteen (15) patients sustained injury by fall on ground and five (5) patients by road traffic accident. In our study fourteen (14) patients had type 3 Boyd and griffin fracture. Fracture union in eighteen (18) cases was achieved by twelve (12) weeks but two (2) cases were united only after sixteen (16) to twenty (20) weeks. Partial weight bearing was started only after four (4) weeks and full weight bearing was allowed only after twelve (12) weeks.



**Fig 5: Flexion**



**Fig 7: Squatting**



**Fig 6: SLR**

There were few complications encountered during follow-up and most of them were technique related. In one (1) case closed reduction was not possible for which open reduction was done and screw positioning difficulty was there in four (4) cases. There were no evidence of varus reduction, delayed union, z-phenomenon, implant failure in our study.

### Discussion:

Intertrochanteric fracture is more commonly seen in elderly with porotic bones and occurs mostly due to simple falls.<sup>1</sup> Elderly people with low bone mineral density are prone for unstable fracture.<sup>2</sup> Keystone for successful union in intertrochanteric fracture is adequate reduction and stable fixation. Before second generation nails, Smith Peterson Nail and Jewet nail were introduced in

1930's. Sliding devices and Dynamic hip screw were developed. DHS is the gold standard for treatment of stable intertrochanteric fractures but for unstable intertrochanteric fractures PFN has showed better results.<sup>3,7</sup> PFN provides additional rotational stability, prevents excessive collapse and maintains neck shaft angle and ease of trochanteric entry portal due to presence of 6 degree mediolateral angulation and 135 degree neck shaft angle.<sup>8</sup> PFN is centromadullary device which is more biomechanically sound and can be performed with minimal invasive technique.<sup>9</sup>

It is classified according to Boyd and Griffin classification which describes four type of inter trochanteric fracture.<sup>10</sup> Type1: Fracture that extend along the IT line, Type2 : Communited fracture with the main fracture line along the IT line but with multiple secondary line(may include coronal fracture line in lateral view), Type3 : Fracture that extend to or are distal to LT, Type4: Fracture of the trochanteric region and proximal shaft with fracture in at least two planes. In our study the most common type of intertrochanteric femoral fractures was Boyd and Griffin type 3.

### Conclusion:

From our study although a small one, we conclude that an intramedullary implants for fracture fixation has favourable outcome in communited intertrochanteric fracture where as the extramedullary implant like DHS/ PFLCP have shown less favourable results. However due to more complicated procedure and a steep learning curve for intramedullary implant fixation , it has been considered to give less satisfactory result in undisplaced intertrochanteric fracture cases ( Grade 1 and 2 stable type) as compared with extra medullary implant.

So , PFN is a biomechanically sound implant and as reduction can be achieved most of the time by a closed technique. It also has the advantage of allowing controlled collapse at fracture site, so maintain the neck length. It also provides rotational stability and reduces incidences of implant cutout .Tip has smaller diameter which reduces the energy fractures. Difficulty in placement the screw, varus collapse might be the complication. Postoperatively early mobilization can be started. So we consider PFN is safe and excellent implant for treatment of peri trochanteric fractures.

### References:

1. Robert W Bucholz , James D Heckman, Charles M Court-Brown, Rockwood and Green's "FRACTURES IN ADULTS"; volume 2, 6th edition; pages 1827-1844.
2. Koval K.J., Aharonoff G.B., Rokito A.S., Lyon T., Zuckerman J.D.; Patients with femoral neck and intertrochanteric fractures: Are they the same? Clin Orthop., 1996; 330: 166-72.
3. G S Kulkarni, Rajiv Limaye , Milind Kulkarni , " Intertrochanteric Fractures – Current Concept Review" Ind J Orth, 2006, Vol 40, 16-23.
4. Haidukewych GJ, Israel TA, Berry DJ. Reverse obliquity fractures of the intertrochanteric region of the femur. J Bone Joint Surg Am 2001; 83:643-50.
5. Babst R, Renner N, Biedermann M, Rosso R, Heberer M, Harder F, et al. Clinical results using the trochanter stabilizing plate (TSP): The modular extension of the dynamic hip screw (DHS) for internal fixation of selected unstable intertrochanteric fractures. J Orthop Trauma 1998; 12:392-9.
6. Hersche O, Heim D, Bodoky A, Regazzoni P. 4 fragment fractures of the proximal femur: Is the dynamic hip screw a suitable implant? Helv Chir Acta 1989; 56:577-80.
7. Whitelaw GP, Segal D, Sanzone CF, Ober NS, Hadley N. Unstable intertrochanteric/subtrochanteric fractures of the femur. Clin Orthop 1990; 252:238-45.
8. Zickel RE. Subtrochanteric femoral fractures. Orthop clin North America 1980; 11:555-568.
9. Haberneck H, Wallnce T, Aschaner E, Schmid L, "comparison of Ender's nails, dynamic hip screw and gamma nails in treatment of peritrochanteric femoral fractures" Orthopaedic 2000; 23(2); 127(7)
10. Boyd HB, Griffin "classification and treatment of trochanteric fractures" Arch surgery, 1949; 58; 853-866.
11. Velasco RU, Comfort T. Analysis of treatment problems in subtrochanteric fractures of the femur. J Trauma 1978; 18:513-522.