



## Kartagener's syndrome: A rare inherited disease

**Prasanta Dihingia**

Associate Professor of Medicine, Department of Medicine, Assam Medical College & Hospital, Dibrugarh

**Anupam Dutta**

Assistant Professor of Medicine, Department of Medicine, Assam Medical College & Hospital, Dibrugarh

**Mahendra Debbarma**

Post Graduate Trainee in Medicine, Department of Medicine, Assam Medical College & Hospital, Dibrugarh

### ABSTRACT

Kartagener's syndrome is a very rare autosomal recessive inherited syndrome. Primary (genetic) defects is in the structure and function of sensory and motile cilia resulting in multiple ciliopathies and malformation comprising of a classic triad of sinusitis, situs inversus and bronchiectasis. Primary ciliary dyskinesia(PCD) is a genetic disorder with manifestations present from early life and this distinguishes it from acquired mucociliary disorders. The defective cilia lining the respiratory tract are unable to clear the airways of secretions and pathogenic bacteria, resulting in mucus retention and chronic or recurrent respiratory tract infection - leading to damage to airway walls. This report presents a clinical case of Kartagener's syndrome in a 28-year-old man coming with recurrent history of respiratory tract infections and recurrent use of antibiotics. Chest X-ray and electrocardiogram showed dextrocardia and bronchiectasis, Paranasal sinus X-ray revealed sinusitis. Abdominal ultrasound confirmed situs inversus totalis. The patient is undergoing treatment for the last 10 years for respiratory tract infections and is infertile.

### KEYWORDS

Bronchiectasis, primary ciliary dyskinesia, Kartagener's syndrome, sinusitis, situs inversus

### Introduction

Kartagener's syndrome is a rare autosomal recessive genetic disease which is mainly seen to affect ciliary movement.<sup>1</sup> The syndrome forms part of a larger group of diseases that are referred to as primary ciliary dyskinesia (PCD). Although the disease is inherited in a recessive autosomal pattern and some specific genetic defects have been recognized, the syndrome clearly manifests substantial genetic heterogeneity.<sup>2</sup> The incidence of the process is 1–2/30000 births.<sup>3</sup> Siewert first described the combination of situs inversus, chronic sinusitis, and bronchiectasis in 1904. However, Manes Kartagener<sup>4</sup> first recognized this clinical triad as a distinct congenital syndrome in 1933. Kartagener described this syndrome in detail.

The symptoms of the syndrome are a consequence of the defective motility of the cilia found in the respiratory tract.<sup>2,3</sup> Recurrent lung infections are due to the affected mucociliary movement in the airways, which cause mucus stasis in the bronchi.<sup>1,5</sup> Until a diagnosis is reached, progressive and substantial lung damage may occur.<sup>3,5</sup> In older children and adults with primary ciliary dyskinesia, 3 diseases of the lower respiratory tract have been described: pneumonia, bronchiectasis and asthma.<sup>6</sup> Although treatment for patients with this syndrome has yet to be established, it is important to control chronic lung infections and declining lung function.

### Case Report

A twenty eight year-old man came to Medicine OPD with complaints of recurrent respiratory tract infections presenting with cough and expectoration and frontal headache intermittently for past 10 years with history of chest pain and breathlessness for last 1 year and chronic use of antibiotics with occasional steroids.; the patient also revealed his infertility status for the last 8 years.

### Examination

The patient was a thin built man, who was dyspneic, coughing, and short of breath. He was febrile, conscious, and oriented. No pallor, cyanosis and icterus were seen. JVP was not raised and no edema feet. A few submental lymph nodes were palpable, which were mildly tender. Auscultation of the chest revealed diffuse bilateral crackles over both infrascapular regions. Chest expansion was reduced. His heart sounds were not heard on the left side, but

they were heard over right side. Apex beat was palpable over the fifth intercostal space on the right side of chest. Rest of the physical and systemic examination were normal.

### Investigations

The electrocardiogram (ECG) with both right and left-sided chest leads revealed inverted "P" waves in L1 and AVL. The ECG was normal on right-sided chest leads thereby showing dextrocardia.

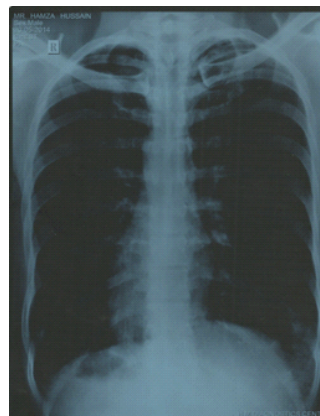
The PNS X-ray have shown bilateral frontal and maxillary sinusitis with hypoplastic left frontal sinus.

The chest X-ray revealed increased bronchovesicular markings and suspicious bronchiectatic features. The above findings gave us the clue to be a case of situs inversus with KS.

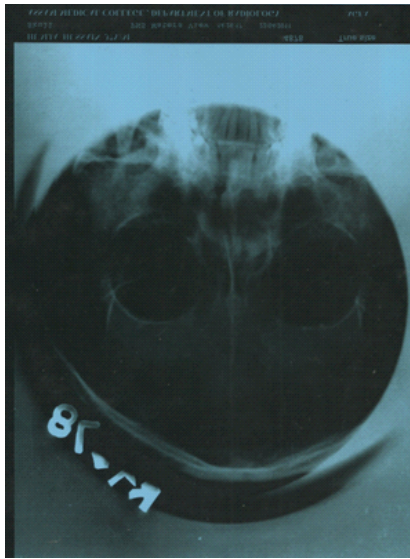
The ultrasonography of abdomen revealed transversely rotated abdominal organs with aorta inverted on the right side of IVC which is suggestive of situs inversus, rest of the scan was normal.

2D echo was consistent with dextrocardia; all four chambers were normal with small pericardial effusion. Doppler study confirmed situs inversus of aorta and inferior vena cava.

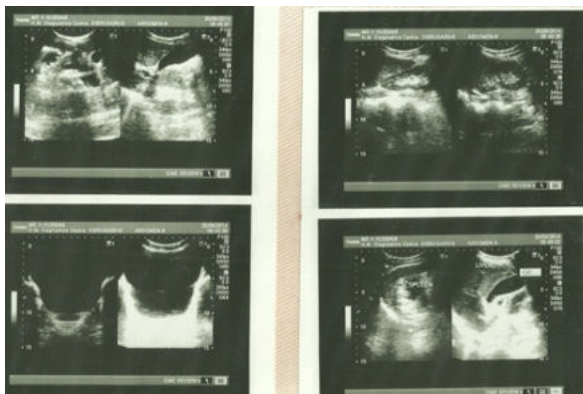
### Image 1: Chest X Ray (PA) showing dextrocardia



**Image 2: X ray Para nasal Sinus shows frontal and maxillary haziness**



**Image 3: Ultrasonography (Abdomen) showing transversely rotated abdominal organs and aorta inverted on the right side of IVC which is suggestive of situs inversus**



## Discussion

The clinical characteristics of Kartagener's syndrome are productive cough, respiratory tract infections, sinusitis, otitis media and infertility.<sup>7,8</sup> In PCD, the clinical phenotype is intensive and it overlaps with other chronic diseases of the respiratory tract.<sup>8</sup> The defect is congenital, and symptoms present at an early age, which emphasizes the importance for pediatricians to know this disease as a substantial, although infrequent, differential diagnosis in children with recurring symptoms in the upper and lower respiratory tract.<sup>5</sup>

In the patient we describe, the diagnosis of Kartagener's syndrome was established at the age of 28. Frequently, the diagnosis of PCD is delayed until adolescence or adulthood as a consequence of the heterogeneous nature of the disease, the lack of physicians' knowledge about the characteristics of the disease and the technical experience that is necessary for a precise diagnosis.<sup>3,8</sup> In addition, the diagnosis of PCD may be delayed because the syndrome, characterized by bronchitis, sinusitis and otitis, can be easily confused with common infections. The delayed diagnosis of the disease can translate into adverse consequences for the patient, including insufficient care or inappropriate treatment.<sup>8,9</sup>

The respiratory treatment of bronchiectasis includes respiratory supervision at regular intervals, respiratory tract clearance with combinations of physiotherapy and physical exercise, and an aggressive treatment of upper and lower respiratory tract infections.<sup>10</sup> The patient we report received an ample spectrum of

curative methods: short cycles of antibiotics, mucolytics, long-acting bronchodilators and daily physical therapy. In general, antibiotics are used during exacerbations of the disease and they are prescribed according to the bacterial growth from the previous sputum culture. The objective of the treatment should be the prevention of chronic lung lesions and bronchiectasis.<sup>11</sup> The two pillars of respiratory treatment are antibiotic therapy and thoracic physiotherapy. Physiotherapy is essential to improve the clearance of the respiratory tract with the aim to delay the onset and progression of obstructive respiratory disease.<sup>4,10</sup> Physical exercise can contribute to sputum clearance, and it has been demonstrated to be a better bronchodilator than the use of bronchodilators themselves in PCD.<sup>9</sup> The prognosis is generally considered favorable, and life expectancy is usually normal. An important part of the clinical visits at regular intervals should be monitoring the progression of the lung disease.<sup>3</sup>

The present clinical case demonstrated a non-progressive course of the bronchiectasis. The patient was followed up with regularly at scheduled appointments every 6 months, including additional visits during the exacerbations.

## References

1. E. Cichońka-Jarosz, U. Jedynak-Wasowicz, I. Głodzik, G. Lis, J.J. Pietrzyk. Primary ciliary dyskinesia in highlights of consensus statement. *PrzegLek*, 67 (2010), pp. 135-140
2. I.C. McManus, H.M. Mitchison, E.M. Chung, G.F. Stubbings, N. Martin. Primary ciliary dyskinesia (Siewert's/Kartagener's syndrome): respiratory symptoms and psycho-social impact. *BMC Pulm Med*, 3 (2003), pp. 4
3. M.W. Leigh, J.E. Pittman, J.L. Carson, T.W. Ferkol, S.D. Dell, S.D. Davis. Clinical and genetic aspects of primary ciliary dyskinesia/Kartagener syndrome. *Genet Med*, 11 (2009), pp. 473-487
4. W.E. Berdon, C. McManus, B. Afzelius. More on Kartagener's syndrome and the contributions of Afzelius and A.K. Siewert. *PediatrRadiol*, 34 (2004), pp. 585-
5. A. Ellerman, H. Bisgaard. Longitudinal study of lung function in a cohort of primary ciliary dyskinesia. *EurRespir J*, 10 (1997), pp. 2376-2379
6. F. Santamaria, S. Montella, H.A. Tiddens, G. Guidi, V. Casotti, M. Maglione. Structural and functional lung disease in primary ciliary dyskinesia. *Chest*, 134 (2008), pp. 351-357
7. N. Skeik, F.I. Jabr. Kartagener syndrome. *Int J Gen Med*, 4 (2011), pp. 41-43
8. P.G. Noone, M.W. Leigh, A. Sannuti, S.L. Minnix, J.L. Carson, M. Hazucha. Primary ciliary dyskinesia diagnostic and phenotypic features. *Am J Respir Crit Care Med*, 169 (2004), pp. 459-467
9. H.A. Ortega, A. Vega Nde, B.Q. Santos, G.T. Maia. Primary ciliary dyskinesia: considerations regarding six cases of Kartagener syndrome. *J Bras Pneumol*, 33 (2007), pp. 602-608
10. A. Bush, R. Chodhari, N. Collins, F. Copeland, P. Hall, J. Harcourt. Primary ciliary dyskinesia: current state of the art. *Arch Dis Child*, 92 (2007), pp. 1136-1140
11. A.B. Chang, K. Grimwood, G. Maguire, P.T. King, P.S. Morris, P.J. Torzillo. Management of bronchiectasis and chronic suppurative lung disease in indigenous children and adults from rural and remote Australian communities. *Med J Aust*, 189 (2008), pp. 386-39