



**ORIGINAL RESEARCH PAPER**

**General Surgery**

**ASSOCIATION OF BACILLUS ANTHRACIS IN CUTANEOUS ULCERS IN KORAPUT ,ODISHA**

**KEY WORDS:** Cutaneous ulcer, Cutaneous anthrax, *B. anthracis*, Koraput

**Bhupati Bhusan Das**

Associate Professor, Department of General Surgery, SLN MCH, Koraput

**Jagadananda Mishra**

Professor, Department of General Surgery, SLN MCH, Koraput

**Jagadananda Mishra\***

Junior Resident, Department of General Surgery, MKCG MCH, Berhampur, \*CORRESPONDING AUTHOR

**ABSTRACT**

Anthrax is an acute infectious zoonotic disease of antiquity caused by spore forming, aerobic, gram-positive, non-motile bacterium *Bacillus anthracis*.<sup>1,2,3</sup> Among the three clinical forms of anthrax in humans, more than 95% of naturally occurring infections are cutaneous anthrax. GI and inhalational anthrax are uncommon. Soil is contaminated with anthrax spores from carcasses of dead animals and can survive for decades under adverse conditions. Anthrax should be included in the differential diagnosis of cutaneous ulcers in endemic areas.

**Methods :** This a prospective study carried out on patients with cutaneous ulcers over a period of six months in S.L.N. Medical College & Hospital, Koraput, India. Ten cases of cutaneous anthrax of different age groups and both sexes were reported. Other cases of cutaneous ulcers were excluded as Gram stain for *B. Anthracis* were negative.

**Result :** In this study, it was observed that cutaneous ulcers are common problems in our population in Koraput. Cutaneous anthrax is common in both extremities, trunk, neck and face. The occurrence of black eschar, umbilicated ulcer, oedema, malignant pustule, fever, regional lymphadenopathy, helped in clinical suspicious of cutaneous anthrax. Anthrax was confirmed by demonstration of Gram +ve rods with rounded ends (pin head appearance). All cases were cured by ciprofloxacin and erythromycin/tetracycline.

**Conclusion:** A case of human cutaneous anthrax can be suspected in patients who suffer from acute onset of skin lesions with papule or vesicle or skin ulceration with raised margin and central black eschar and surrounding oedema in malignant pustule with history of slaughtering of sick animals and use of animal products. Cutaneous anthrax is curable condition with the use of proper antibiotics.

**INTRODUCTION**

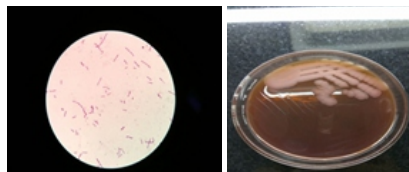
Cutaneous ulcers are common problems in our population causing hospital admissions, leading to tremendous emotional, physical, financial human burdens. Cutaneous anthrax, though uncommon, is a differential diagnosis of such ulcer in endemic areas.

Cutaneous anthrax is a Zoonotic infection caused by *B. anthracis*, *B. anthracis* is an aerobic, Gram +ve, spore forming, non-motile bacillus.<sup>4</sup> Human resistance to infection with the anthrax bacillus is high and despite widespread distribution of anthrax bacilli and spores among hoofed animals, human anthrax surprisingly rare.

Cutaneous anthrax outbreaks have been reported from developing countries with low socio-economic status i.e. parts of Africa, Asia (Bangladesh, India etc.), Eastern Europe (Turkey and Greece).<sup>4</sup> It is rare in Western Europe and United states.<sup>4</sup> Naturally occurring anthrax in humans is a disease acquired from contact with anthrax infected animals or anthrax contaminated animal products.<sup>3</sup> Anthrax infection occurs in humans via three major routes : cutaneous, gastrointestinal and inhalational. Cutaneous anthrax is the most common naturally occurring form with an estimated 2,000 cases reported annually worldwide.<sup>2</sup>

**MATERIALS AND METHODS:**

The present study was undertaken in the department of General Surgery, S.L.N. Medical College & Hospital, Koraput, Odisha prospectively from April 2017 to September 2017 (6 months). The selection of cases and procedure adopted in this study are detailed below. 50 Cases of cutaneous ulcer of different age group and both sexes were selected. The purpose of this study was explained to all the patients participating in the study and written consent was taken from all. All cases of cutaneous ulcers were admitted to the hospital and were subjected to routine blood investigations including FBS, 2 Hr PPBS, Gram Stain of exudate taken from floor of ulcer, radiological examination of the part to exclude osteomyelitis, DC, TLC, Hb%, HIV, culture of the exudate of ulcer.



**Fig 1:Gram stain and Culture of Bacillus anthracis**

**Inclusion Criteria**

Fifty cases diagnosed with cutaneous ulcer were included in the study. The ulcers were on different body parts.

**Exclusion Criteria**

1. Patient not willing for study
2. Patients with Diabetes
3. Immunocompromised patients

**OBSERVATION AND RESULTS**

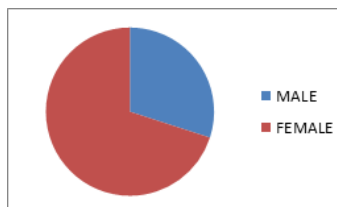
**Table 1: Etiological distribution of cutaneous ulcers:**

	Cutaneous Anthrax	Non specific ulcers
Skin Lesion	10	40

Non-specific Ulcers :Staphylococcal, Cellulitis, Pyaemic, Traumatic etc.

**Table 2: Gender distribution of cutaneous anthrax cases:**

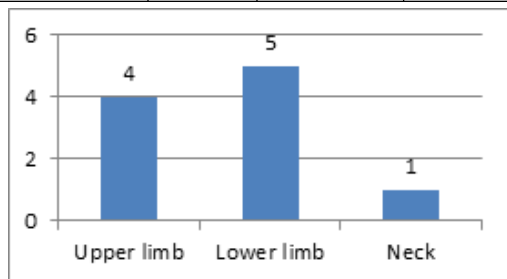
Gender	MALE	FEMALE	TOTAL
Cutaneous anthrax	03	07	10



**Fig 2: Gender distribution of cutaneous anthrax cases.**

**Table 3: Distribution of anthrax cases according to sites**

Cutaneous anthrax	Upper limb	Lower limb	Neck
	04	05	01



**Fig 3: Distribution of cutaneous anthrax cases according to site of involvement**

In this study, the most common cause for cutaneous ulcers was non-specific infection, staphylococcal, infection, cellulitis, abscess etc. Cutaneous anthrax was found only in 10 cases. Three cases were male and seven cases were female. 2 patients had multiple ulcers in lower extremity. All the patients were referred to Surgery department from Medicine department and were studied in detail. Four patients had upper limb affection, one in neck and five cases had lower limb affections including inguinal area, popliteal fossa and leg. All the patients tested positive on Gram stain for *Bacillus anthracis* (pin head appearance) Gram +ve rods with rounded ends single / chain.

It was observed that most common risk factor for cutaneous anthrax was occupational exposure butchering / sick animal slaughtering, exposure to animal products.<sup>3</sup> The patients were from Koraput and were of low socio-economic status.

All the patients were given oral antibiotics for 2 weeks Macrolide antibiotics (Erythromycin) / Tetracycline and oral Ciprofloxacin for 2 months. All the cutaneous anthrax ulcers healed and no one had any complication meningoencephalitis, coma or death. The healing was observed within a week time frame.

**Discussion**

This is a small study of 10 cases of cutaneous anthrax found in the month of March-April in Koraput District of Odisha. It is the onset of rainy season where spores germinate and infect grazing animals. Human beings are infected by slaughtering infected animals or use of animal products. The organisms in fact and cause skin lesions in cutaneous form, GI , inhalational forms and meningoencephalitis complications are rare.

In this study females outnumbered males. It may be due to more care of animals by ladies as well as dressing and washing of infected meat. The incidence in Koraput may be due to poor economic conditions, lack of knowledge (ignorance), social tradition and dietary behavior.

Microbiological diagnosis is the key to confirm clinical diagnosis. All cases herein were referred to surgery from Medicine department and all were smear positive cases. The smears for Gram stain was taken from floor of the ulcer. Demonstration of large Gram +ve rods with rounded ends (Pin headed appearance) typically resembled *B. anthracis*. Culture for isolation and PCR (Polymerase chain reason) for nucleic acid detection as by done in our cases due to lack of facilities. IHC examination can confirm diagnosis in complicated cases in cases improper use of antibiotics.<sup>2</sup>

Clinical suspicious of non-tender ulcer with black eschar with or without oedema and history of butchering or dressing / washing of cattle / goat or their meat in endemic areas is of importance simple gram stain fallen from the floor of ulcer confirmed the diagnosis.

The differential diagnosis of cutaneous anthrax includes staphylococcal infection, rate bite fever, spider bite, gangrenous erythema, vasculity and traumatic ulcer.<sup>2</sup>

Drugs for anthrax are penicillin (Penicilin V or Procain penicillin), Aminoglycosides, Macrolides, Quinolones, Tetracycline and Chloramphenicol. Rifampicin, Vancomycine, Imiperem, Meropenem, Clindamycin have also been used.<sup>6</sup> Ciprofloxacin and oral Flucloxacillin is widely used.<sup>7</sup> In this study ,all cases were treated with oral Ciprofloxacin for 2 months and oral Erythromycin / Tetracycline for 2 weeks.

**Conclusion:**

Cutaneous anthrax should be suspected in any cutaneous ulcer with black eschar, oedema (malignant pustule) or with pappule or vesicle with history of slaughtering of sick animals or use of contact of animal products. It should be included in the differential diagnosis of cutaneous uclers in endemic areas.

**REFERENCES:**

1. Ascenzi P, Visca P, Ippolito G, Spallarossa A, Bolognesi M, Montecucco C. Anthrax toxin: a tripartite lethal combination 1. FEBS letters. 2002 Nov 20;531(3):384-8.
2. Maguina C, Flores Del Pozo J, Terashima A, Gotuzzo E,et.al. Cutaneous anthrax in Lima, Peru: retrospective analysis of 71 cases, including four with a meningoencephalic complication. Revista do Instituto de Medicina Tropical de São Paulo. 2005 Feb;47(1):25-30.
3. Siddiqui, M.A., Khan, M.A.H., Ahmed, S.S., Anwar, K.S. et.al.. Recent outbreak of cutaneous anthrax in Bangladesh: clinico-demographic profile and treatment outcome of cases attended at Rajshahi Medical College Hospital. *BMC research notes*, 20<sup>12</sup>; 5(1), p.464
4. Demirdag K, Ozden M, Saral Y, Kalkan A, Kilic SS, Ozdarendeli A. Cutaneous anthrax in adults: a review of 25 cases in the eastern Anatolian region of Turkey. *Infection*. 2003 Oct 1;31(5):327-30.
5. Green BD, Battisti L, Koehler TM, Thorne CB, Ivins BE. Demonstration of a capsule plasmid in *Bacillus anthracis*. *Infection and immunity*. 1985 Aug 1;49(2):291-7.
6. Abramova FA, Grinberg LM, Yampolskaya OV, Walker DH. Pathology of inhalational anthrax in 42 cases from the Sverdlovsk outbreak of 1979. *Proceedings of the national academy of sciences*. 1993 Mar 15;90(6):2291-4.
7. Henderson DA, Inglesby Jr TV, O'Toole T, Bartlett JG, Inglesby Jr TV, Borio L. Management of anthrax. *Clinical infectious diseases*. 2002 Oct 1;35(7):851-8.5