



ORIGINAL RESEARCH PAPER

SURGERY

PROSPECTIVE STUDY OF RESULTS FOLLOWING INTERVENTION IN EXTREMITY VASCULAR TRAUMA CASES

KEY WORDS: Extremity , Vascular trauma

Dr. Paramasivam Ilayakumar	MBBS., MS., M.CH Assistant Professor, Institute of Vascular Surgery, Rajiv Gandhi Govt. General Hospital, Chennai-3.
Dr. M. Ramya*	MBBS., MS., M.CH Vascular Surgery Post Graduate, Institute of Vascular Surgery, Rajiv Gandhi Govt. General Hospital, Chennai-3. *Corresponding Author
Dr. N. Sritharan	MBBS., MS., M.CH., Professor, Institute of Vascular Surgery, Rajiv Gandhi Govt. General Hospital, Chennai-3.
Dr. Jayanth V. Kumar	MBBS., MS., M.CH., Assistant Professor, Institute of Vascular Surgery, Rajiv Gandhi Govt. General Hospital, Chennai-3.
Dr. M. Krishna	MBBS., MS., M.CH., Assistant Professor, Institute of Vascular Surgery, Rajiv Gandhi Govt. General Hospital, Chennai-3.
Dr. S. Prathap Kumar	MBBS., MS., M.CH., Assistant Professor, Institute of Vascular Surgery, Rajiv Gandhi Govt. General Hospital, Chennai-3.

ABSTRACT

INTRODUCTION : Extremity vascular trauma is common in civilian population following RTA. The aim of this study is to evaluate the results following intervention in extremity vascular trauma cases admitted in Rajiv Gandhi Government General Hospital , Chennai , during period 1st September 2016 to 31st August 2017.
METHOD OF STUDY : Prospective study
RESULTS : Of 52 cases, Commonly injured artery was popliteal artery (26.9%). Most of the cases were treated with interposition vein bypass(88.46%) and remaining with primary repair(5.76%) and ligation(5.76%). Failure following repair was 8.1% . Limb salvage rate was 98%.
Conclusion : Early intervention with interposition vein bypass with proper technique and proper case selection with adequate fasciotomy and wound care yield better results.

INTRODUCTION :

Extremity vascular injuries account for 40 to 75% of vascular injuries treated in civilian trauma centers. Their management is specially challenging due to associated soft tissue injury , orthopedic trauma, nerve damage and contamination. The clinical diagnosis of extremity vascular trauma is classically associated with diligent search for hard and soft signs⁽³⁾. Hard signs are an absolute indication for vascular exploration where as soft signs are an indication for angiography. The reported amputation rate following isolated limb arterial injuries is 4% where as in combined injuries is as high as 61%.

MATERIALS AND METHODS :

Over a one year period , 52 patients with extremity vascular trauma were prospectively studied.

Inclusion criteria :

- All patients with Extremity vascular injuries with or without

associated orthopedic and soft tissue injuries with salvageable limb.

Exclusion criteria :

- Associated head injuries or major injuries to abdomen necessitating urgent attention first.
- Non-salvageable limb (with major tissue loss/mangled limbs).

Diagnosis was made mainly on clinical basis. Preoperative hand held Doppler examination was routinely performed, while angiography was reserved for hemodynamically stable patients with doubtful diagnosis, provided no further delay was incurred. All acute injuries were initially haemodynamically stabilized followed by urgent exploration. Definitive management was carried out in collaboration with orthopedic and plastic surgeon. Primary amputation was excluded from the study.

RESULTS :

Table -1 : Summary of study results

ARTERY INJURED	MODE OF INJURY	NO OF INJURIES	METHOD OF ARTERIAL REPAIR	VEIN INJURY	METHOD OF VENOUS REPAIR	BONE INJURY	NERVE INJURY	FOLLOWUP
BA	B-4 C-2	6	IVG-6	4 (1thrombosed)	L-2 IVG-1	4	3	Amputation-1 Failure – 1
RA	B-1 C-10	11	IVG-7 E TO E-2 L-2	-	-	-	2	Failure – 2
UA	C-13	13	IVG-11 E TO E-1 L-1	-	-	-	8	Failure – 1
RA+UA	C-2 B-3	5	IVG-5	-	-	1	2	
POP. A	B-14	14	IVG-14	10 (3thrombosed)	IVG-1 L-6	13	-	Non func limb-1 Blowout -1
CFA	B-1	1	IVG-1	1	V-1	-	-	
CIA	B-1	1	IVG-1	1	V-1	-	-	
TPT	B-1	1	IVG-1	-	-	1	-	
TOTAL	B-25 C- 27	52	IVG - 46 E TO E- 3 L-3	16 (4thrombosed)	12	19	15	

B-Blunt injury, C-Cut injury, IVG –Interposition vein graft, E TO E –End to end anastomosis, L-Ligation, V-Venorrhaphy

Fig.1 : Method of arterial repair

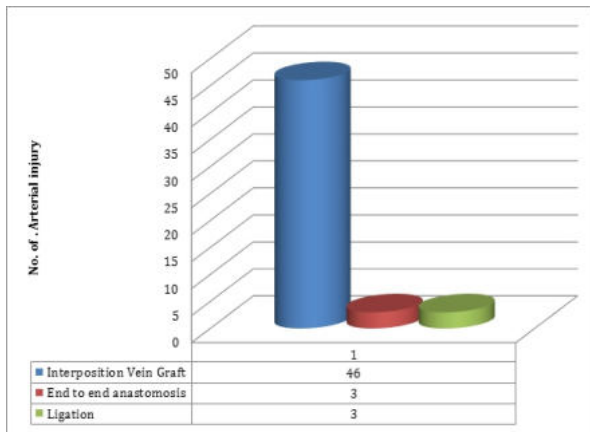


Fig.2 : Method of Venous repair

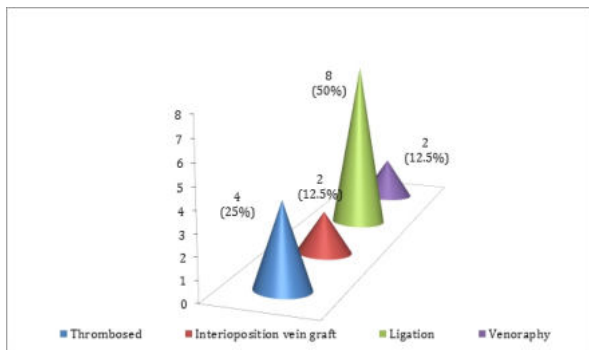
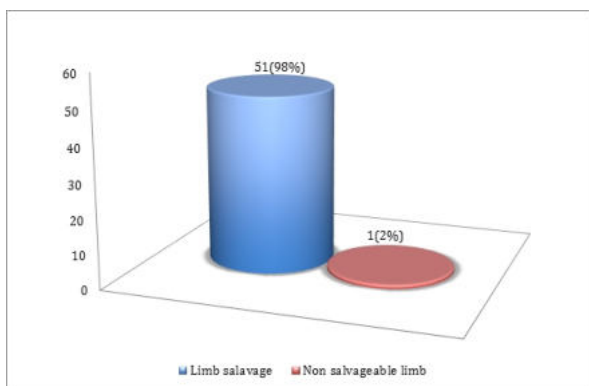


Fig.3 : Limb salvage rate



DISCUSSION :

In our study, extremity vascular trauma is common in young males (1)(2)(4) of age 13 to 58 years with cut injury being more common than blunt injury . Commonly injured extremity was upper extremity(1) and the commonly injured artery was popliteal artery(4). Combined injuries were seen in 36.5 % of cases . The sequence of repair was vascular repair followed by fracture stabilization with external fixator(2) , nerve and soft tissue repair by plastic surgeon, except for one case for which shunting was done first(due to unstable fracture) followed by fracture stabilization and definitive arterial repair.

Type of arterial repair included end to end anastomosis , interposition vein bypass and occasionally ligation. There was no failure following interposition vein bypass and high failure rate following end to end anastomosis. Ligation was done for 3 cases, with one patent vessel in upper extremity, due to heavy contamination . 30.7% of cases had associated vein injury. Vein injuries were repaired with inter position vein bypass for single axial vein , venoraphy and ligation . All were thrombosed after 24 to 48 hours of reconstruction which recanalised during followup(4-6 weeks).

There was no failure in early intervention(5)(6)(less than 6 hours) and 9.5% failure following late intervention (more than 6 hours). Redo bypass was done in one failure (both brachial artery and vein injury repaired with interposition vein bypass) which later ended up in amputation due to infection. Total failure following repair was 8.1% (4/49). Fasciotomy was done for patients who underwent repair for brachial artery ,popliteal artery and tibioperoneal trunk injury(1)(3)(7) .

Postoperatively patients were treated with Antiplatelets /Anticoagulants. Daily wound care was given with debridement , irrigation and dressing. Duration of hospitalization on an average was 7 to 10 days. Fasciotomy wounds which required SSG were handed over to plastic surgeon.

During followup, there was one 'blowout' which was ligated, one secondary amputation and 8 patients with upper limb dysfunction (related to nerve injury) , one lower limb was left non functional (due to associated extensive soft tissue and nerve injury), Nil amputation rate in isolated arterial injury, 2.8 % amputation rate in combined injuries. Limb salvage rate was 98 % with nil mortality.

CONCLUSION :

Early intervention with interposition vein bypass with proper technique and proper case selection with adequate fasciotomy and wound care yield better results. In spite of thrombosis , venous reconstruction for single axial vein is advisable giving a chance for recanalization(1)(2) .

REFERENCES

- [1] Hashem MM, Ali M, Grillo IA, Malatani TS, Mustafa FA, Mustafa MA. Peripheral Vascular Injuries Associated with Limb Fractures Clinical Presentation and Management. [Internet] [Cited on Oct 12 2015] Available from: https://uqu.edu.sa/files2/tiny_mce/plugins/filemanager/files/4260113/25.pdf
- [2] Cakir O, Subasi M, Erdem K, Erin N. Treatment of vascular injuries associated with limb fractures. *Ann R Coll Surg Engl* 2005; 87: 348–352
- [3] Hirshbergand A, Mattox KM. Vascular Trauma. In: Ascher E, editor-in-Chief. Haimovici,s Vascular Surgery, 5th ed. USA, UK, Australia, Germany: Blackwell Publishing, 2004. P. 421
- [4] Al-Museilih AY. Vascular Injuries in Basrah, Iraq: A 5-Year Experience. *JABMS* 2004;6:118-25E
- [5] Shi L. The delayed management of main arterial injuries in extremity trauma: surgical challenges and outcomes. *Pak J Med Sci* 2013;29:64-67. doi: <http://dx.doi.org/10.12669/pjms.291.2619>
- [6] Siddique MK, Majeed S, Irfan M, Ahmad N. Missed Vascular Injuries: Presentation and Outcome. *Journal of the College of Physicians and Surgeons Pakistan* 2014;24: 428-431.
- [7] Farber A, Tan T-W, Hamburg NM, Kalish JA, Joglar F, Onigman T. et al. Early Fasciotomy in Patients with Extremity Vascular Injury is associated with Decreased Risk of Adverse Limb Outcomes: A Review of the National Trauma Data Bank. *Injury* 2012; 43: 1486–1491. doi:10.1016/j.injury.2011.06.006