Volume : 6 | Issue : 2 | February - 2017 ISSN - 2250-1991 | IF : 5.215 | IC Value : 79.96

Original Research Paper Anatomy

MORPHOMETRIC ANALYSIS OF FORAMEN MAGNUM IN HUMAN DRY SKULLS IN CENTRAL INDIA REGION

Dr. P.C. Jain	Associate Professor, Department of Anatomy, N.S.C.B. Medical College, Jabalpur.
Dr. Neha Tiwari	PG Student, Department of Anatomy, N.S.C.B. Medical College, Jabalpur.
Dr. K.K. Gour	Assistant Professor, Department of Anatomy, N.S.C.B. Medical College, Jabalpur

ABSTRACT

The study of skull and its foramina is important to anatomists, anthropologists, clinicians, neurosurgeons and forensic experts. The dimensions of the foramina and variations in the same are clinically significant in view of the delicate neurovascular structures that traverse them. The present study aims to measure accurately the mean anteroposterior and transverse diameters of the foramen magnum in the region of central India so that the data will be available as a ready reference. Measurements were conducted on 100 dry human skulls in the Department of Anatomy, Netaji Subhash Chandra Bose Medical College, Jabalpur. The mean anteroposterior diameter was found to be 3.35 cm and transverse diameter was found to be 2.61 cm. The area of the foramen magnum was calculated to be 7.48 cm².

KEYWORDS Skull, Foramen Magnum, Sagittal Diameter, Transverse Diameter.

INTRODUCTION :-

The study of skull and its foramina is important to anatomists, anthropologists, clinicians, neurosurgeons and forensic experts. The dimensions of the foramina and variations in the same are clinically significant in view of the delicate neurovascular structures that traverse them.

The Foramen Magnum is a large oval opening in the skull base lying in the posterior cranial fossa.1 It is wider behind with its greatest diameter being Anteroposterior.2 It is located midway between and at the same level as the mastoid process. It is divided by the Alar ligament into a small anterior and larger posterior compartment.

The anterior part gives passage to:

- The apical ligament of dens
- Upper band of cruciate ligament
- Membrana tectoria

The structures passing through the posterior part of the foramen magnum are :

- Lower end of Medulla oblongata and the meninges
- Fourth part of vertebral arteries surrounded by sympathetic plexus of nerves
- Spinal roots of accessory nerves
- Anterior and posterior spinal arteries
- Occasionally tonsil of cerebellum

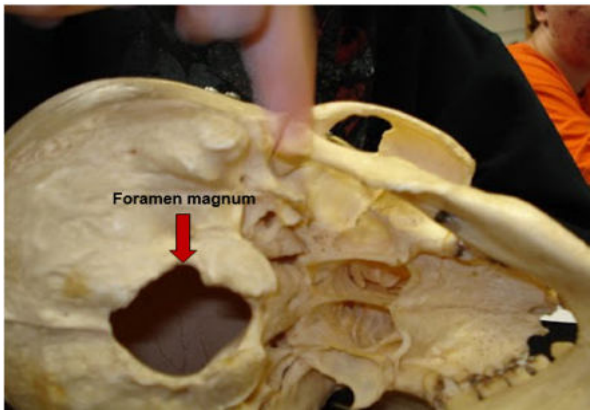

AIMS AND OBJECTIVES :

The dimensions of Foramen Magnum are clinically important because the above mentioned vital structures may endure compression in cases of Foramen Magnum lesions like herniation, Foramen Magnum Meningiomas, Achondroplasia etc. The knowledge of Foramen Magnum diameters is needed to determine some malformations such as Arnold Chiari syndrome which shows the expansion of transverse diameter. The dimensions of Foramen Magnum are important prior to removal of posterior cranial fossa lesions.[3]

The diameters and area of Foramen Magnum are greater in males than in females, hence its dimensions can be used to determine sex in the medico- legal cases especially in circumstances like explosions, aircraft accidents and warfare injuries.[4]

The present study aims to measure accurately the Antero-posterior and transverse diameters of the Foramen Magnum in the region of central India as the currently available data is mostly from studies conducted in foreign countries. We hope that this study augments the existing literature and provides focusing on this region and also contributes to forensic analysis.

MATERIALS AND METHODS:

The morphometric analysis of the Foramen Magnum was conducted in the Department of Anatomy, Netaji Subhash Chandra Bose Medical College, Jabalpur. The study involved 100 dry skulls. All the skulls belonged to adults of age above 18 years, as confirmed by the departmental records.

The measurements were done using manual vernier calipers measuring upto 2 decimal places, graduated to the last 0.01mm.

The following diameters were measured:

a. The anteroposterior or sagittal diameter of the Foramen Magnum, which is the distance between the basion and opisthion.
Basion – Central point of anterior edge of Foramen Magnum.
Opisthion – Central point of posterior edge of Foramen Magnum.

b. The transverse diameter, which is the maximum distance between the two lateral margins of foramen magnum at the point of maximum lateral curvature.

The technique involved repetition of the measurements twice and the average results were compared. If there was a difference of more than 0.1 mm, then a third measurement was taken.

c. The area of foramen magnum (A) was calculated using the formula derived by Radinsky based on his study conducted on relative brain size in 1967.[5]

Radinsky's formula:-
A= ¼ X π X T X S
A → area of Foramen Magnum
T → transverse diameter
S → sagittal diameter
π → mathematical constant, 22/7.

The data was collected, recorded and statistically analysed.

Vernier caliper

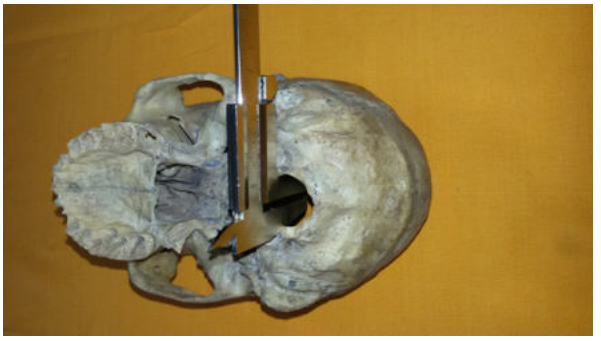

Technique of measuring diameter by Vernier Caliper

STATISTICAL METHODS:
Results were expressed as mean ± 1 SD (standard deviation) and range.

RESULT:
It was observed that on an average the sagittal diameters (S) was more than the transverse diameters (T) which is also in accordance with the shape of the foramen. The mean, average, range, maximum value and minimum value of anteroposterior and transverse diameters are given in Table-1.

TABLE-1 Values of AP and Transverse Diameter

Diameters	Mean	Avg.	Range	Max. value	Min. value
AP.	3.35cm	3.34cm	3.10-4.00cm	4.00cm	3.10cm
Transverse	2.61cm	2.60cm	2.12-3.33cm	3.33cm	2.12cm

TABLE -2 Values of Area of Foramen Magnum

Mean Area	Average	Range	Max.	Min.Value
6.86 sq.cm	6.79 sq.cm	6.14-6.99 sq.cm	6.99 sq.cm	6.14 sq.cm

Graph -1 : Showing frequency of values of AP diameters

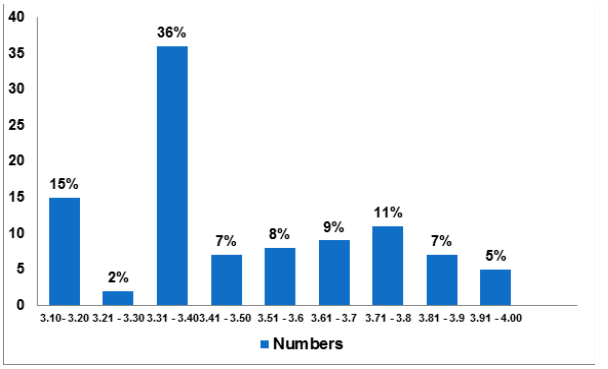

Graph-2: Showing frequency of values of Transverse diameters

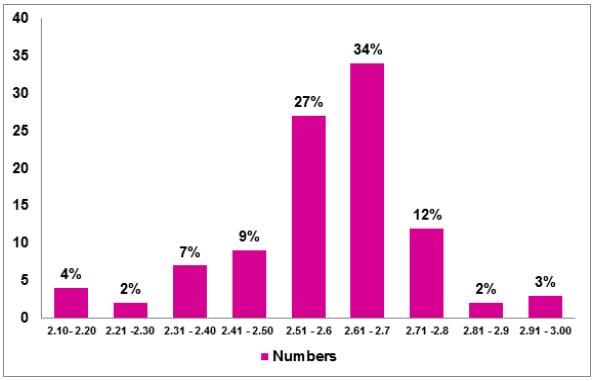

DISCUSSION:
Studies by Sayee et al, 6 Routal et al, 7 Gruber et al,8 and Murlidhar et al9 are a few resent studies on morphometric variations of the foramen magnum.

The mean sagittal diameter of foramen magnum of present study was similar to observations of Sayee and Jankiraman who studied the foramen magnum damnations in crania from Karnataka in 1987 where the mean value was 3.42 cm and to the study conducted by Murlidhar et al in 2014 whose mean value was 3.34 cm.

However it was lower than the observations made by Routal et al on Gujrati male skulls whose mean value of sagittal diameters was 3.55 cm and by Gruber et al who studied dimensions on Brazilian male skulls and calculated a mean of 3.56 cm.

In the present study the area of foramen magnum calculated was similar to observations made by Sayee on male skulls of Karnataka (7.69 cm2) . But lower than observation made by Routal et al on Gujrat male skulls (8.19 cm2) and Nakashima T – A morphological comparison of foramen magnum of male Kyushites with that of other ethnic groups.10

The observations of various studies may have varied depending on the ethnic group involved, size of study sample etc.

TABLE-3 Comparision of foramen magnum dimensions of previous studies with present

Parameters	Present Study	Sayee et al	Routal et al	Gruber et al
Mean AP Diameter	3.35 cm	3.42cm	3.55cm	3.65cm
Mean Transverse Diameter	2.61cm	2.72cm	3.01cm	3.11cm
Mean Area	7.48sqcm	7.69sqcm	8.19sqcm	9.09sqcm

REFERENCES :

1. Standring Susan Gray's Anatomy: The Anatomical Basis of Clinical practice 40th ed. London: Elsevier Churchill Livingstone;2008 p415
2. A. K. Datta: Essentials of Human Anatomy 5th ed.;2015, p56
3. Bannister LH, Berry MM, Collins P, Dyson M, et al:Gray's Anatomy- The Anatomical Basis of Medicine and Surgery. 38th ed. Edinburgh: Churchill Livingstone;1995 p567-568
4. Frazer's Anatomy of human skeleton. Sixth edition text ; 6th edition, 1965.
5. Radinsky L. Relative brain size: a new measure science 1967: 836-38.
6. Sayee R., Janakiram S., Thomas I. M. Foramen magnum measurements of Crania from Karnataka. Journal of the Anatomical Society of India. 1987; 36:87-89.
7. Routal RR, Pal GP, Bhagwat SS, Tamankar BP. Material studies with sexual dimorphism in foramen magnum of human crania. Journal Anat. Soc. Of India 1984;33(2):85-89
8. Singh KB: A material study of Chinese crania. Journal Anat. Soc. Of India 1963;12-16
9. Berge J. K., Bergman R. A. Variations in size and in symmetry of foramina of the human skull. Clinical Anatomy. 2001; 14 (6): 406-413. Doi: 10.1002/ca. 1075.
10. Nakashima T- A morphological comparison of foramen magnum of the male Kyushites with that of other ethnic groups. Journal of UOEH. 1986; 8(4): 405-410.