



IS HAPTIC LENGTH RELEVANT IN GLUED IOL SURGERY

Dr. Santosh Kumar

MS,DNB,FICO,FAICO,FRCS(Glasg). Associate Professor, Army Hospital(Research & Referral), Delhi Cantt-10

Dr Vijay Sharma

MS,DNB,Assistant Professor, Army Hospital(Research & Referral),Delhi Cantt-10

Dr Sagarika Patyal

DOMS,MS, Professor and Head of Department, Army Hospital(Research & Referral), Delhi Cantt-10

ABSTRACT

- Glued IOL surgery is now widely accepted for management of aphakia. However this surgical procedure is also fraught with its share of complications. We have observed increased incidence of post-operative haptic dislocation in patients who were implanted a glued IOL of overall length <13.0mm. This study analysed the factors responsible for IOL haptic dislocation with special attention to overall IOL length and in turn the haptic length.
- This study clearly brings forth that overall IOL length should be preferably > 13.0 mm and safely 13.5 mm so that adequate length of haptic is available to be tucked inside the scleral tunnels.
- A haptic tuck of at least 03mm on either side will minimize the chances of haptic dislocation. Moreover a larger haptic tuck ensures minimal haptic movement and nearly obliterates the chance for dislodgement of haptics and subsequent IOL dislocation.

KEYWORDS

Glued IOL, Aphakia, 3-Piece IOL, Haptic length

Aim

To ascertain and establish if an overall IOL length of ≥ 13.5 mm is necessary for success of glued IOL surgery.

Introduction

Aphakia is of a common occurrence and the incidence continues to rise due to a large number of cataract surgeries being performed and concurrent increase in incidence of intraoperative complications and resultant surgical aphakia. Also on the rise is lenticular trauma due to open or closed globe injuries and lenticular damage can present in form of subluxation, dislocation, capsular tear and flocculent cortical matter in the anterior chamber with intraocular inflammation and IOP rise. Other causes of aphakia are surgery for ectopia lentis and related syndromes. In cases with dislocated crystalline lenses or severe lenticular injury with ruptured posterior capsule or subluxation greater than 6-8 clock hours, it becomes imperative to completely remove the crystalline lens and correct the resultant aphakia. Historically, aphakia management has always been a challenge to manage as well as rehabilitate. In the past, majority of these cases have been managed with aphakic glasses, contact lenses, iris fixated lenses or anterior chamber intraocular lenses. These techniques had their own limitations and gave way to the more preferred technique of scleral fixated IOL's (1). Owing to the late suture degradation, risk of suture related infection and pseudophakodonesis, scleral fixated IOL's had their own set of problems. Currently with the advent of glued IOL technique, the management of aphakia has become more predictable with better surgical outcomes(2). This technique allows for the placement of intraocular lens behind the iris, very near to the original position of the natural crystalline lens. The surgical procedure though challenging, if performed consentiously yields gratifying results (3). However the success story is not limited to the procedure itself. During the course of management of these patients we observed that in a particular subset of patients there was increased incidence of IOL haptic dislocation(4,5,6). When the patients were analysed retrospectively, it was evident that the patients who were implanted an IOL of a particular overall length were more predisposed to haptic dislocation than others.(7,8)

MATERIALS AND METHODS

A retrospective case analysis of 32 cases of post-surgical / post-traumatic aphakia who underwent glued IOL surgery at a tertiary

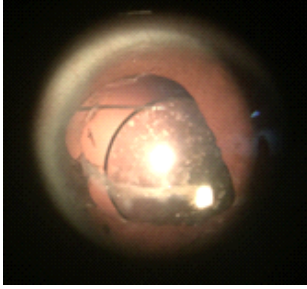
eye care referral centre between Jan 2012 and Jan 2015 was done. All patients were operated by a single surgeon under peribulbar anaesthesia using the same surgical technique. The IOL's used were 3- piece with hydrophobic acrylic optics and polypropylene haptics. The IOL's had three different overall lengths of 12.5 mm, 13.0 mm and 13.5 mm and their implantation was done randomly depending upon their availability at the time of surgery. The conjunctiva was incised at 3'o clock and 9'o clock just adjacent to limbus and retracted and episcleral vessels cauterised. Two partial thickness scleral flaps 3mm x 3 mm were made in horizontal meridian at 3'o clock and 9'o clock positions. 26 G needle was used to create a scleral tunnel pocket at the edge of the flap to hold the haptics. Two sclerotomies were made with a 26G needle about 02.5mm behind the limbus on the scleral bed below the partial thickness flap. An AC maintainer was placed inferotemporally in cornea. After performing a thorough vitrectomy through the sclerotomies, a 2.8mm clear corneal incision was made at 12'o clock position. The 3-piece IOL was loaded and kept ready for injection at the corneal wound. Simultaneously a 23G glued IOL holding forceps was inserted through the sclerotomy to grasp the IOL haptic and exteriorize it and subsequently the assistant holding it. Similarly the forceps were inserted through the other sclerotomy and IOL haptic exteriorized with the handshake technique. The two exteriorized haptics were then tucked in into the scleral tunnels/pockets at the edge of the scleral flaps. Subsequently the scleral flaps were glued back into place using a biological glue and the conjunctiva was repositioned back. The patients were followed up on day 01, 03, 07, 15 and day 30 after surgery. The patients were evaluated for BCVA, any signs of post op inflammation, placement and stability of IOL and haptics and fundus. The data for IOL placement was studied, analysed and tabulated.

RESULTS

Overall haptic length	IOL well centered. Haptic end not seen and present in the scleral tunnel.	No IOL tilt. One end of the haptic out of scleral tunnel.	One haptic end grossly displaced. IOL tilted.
12.5 mm	05 (05/08)	02 (02/08)	01 (01/08)
13.0 mm	09 (09/10)	01 (01/10)	00
13.5 mm	14 (14/14)	00	00

Fig.1: IOL centration correlated with haptic length
a) In patients where 12.5 mm IOL was used

- i. 05 patients (62.5 %) had a stable haptic and IOL.
- ii. 02 patients (25 %) had one end of the haptic out of scleral tunnel but no IOL tilt (Fig. 2). This patient's haptic was retucked into the scleral tunnel.
- iii. 01 patient (12.5 %) had one haptic grossly displaced and a tilted IOL which needed the IOL explantation and resurgery.



- a) In patients with 13.0 mm IOL overall length
 - i. 09 patients (90%) had a stable haptic and IOL.
 - ii. 01 patient (10%) had one end of haptic out of scleral tunnel which was retucked.
- b) In all 14 patients where a 13.5 mm overall IOL length was used there was complete stability of IOL and the edges of haptic were well tucked in the scleral tunnels.

CONCLUSIONS

- This study clearly brings forth that overall IOL length should be preferably > 13.0 mm and safely 13.5 mm so that adequate length of haptic is available to be tucked inside the scleral tunnels.
- A haptic tuck of at least 03mm on either side will minimize the chances of haptic dislocation. Moreover a larger haptic tuck ensures minimal haptic movement and nearly obliterates the chance for dislodgement of haptics and subsequent IOL dislocation.

REFERENCES

1. Scleral Fixation of Intraocular Lens in Eyes With History of Open Globe Injury : Banaee, Touka; Sagheb, Setareh: September 2011, Journal of Pediatric Ophthalmology & Strabismus; Sep/Oct 2011, Vol. 48 Issue 5, p292
2. Curr Opin Ophthalmol. 2013 Jan;24(1):21-9: Glued intraocular lens: a major review on surgical technique and results. DA Kumar, A Agarwal
3. Study finds reasonable results with glued IOL in pediatric eyes
Refractive changes in these young growing eyes can be problematic. Ocular Surgery News U.S. Edition, August 10, 2011, Amar Agarwal, MS, FRCS, FRCOphth, Dhivya Ashok Kumar, MD
4. Modified technique for removal of Sommering ring and in-the-bag secondary intraocular lens placement in aphakic eyes: Grewal DS, Basti S, J Cataract Refract Surg. 2012 May;38(5):739-42
5. Glued intrascleral fixation of posterior chamber intraocular lens in children. Am J Ophthalmol. 2012 Apr;153(4):594-601, Kumar DA, Agarwal A, Prakash D, Prakash G, Jacob S, Agarwal A
6. Cataract Refract Surg. 2015 Apr;41(4):708-13. : Glued intraocular lens scaffolding for Sommering ring removal in aphakia with posterior capsule defect. P Narang, A Agarwal, DA Kumar
7. Implantation of glued intraocular lenses in eyes with microcornea: Ashok Kumar D, Agarwal A, Sivangnanam S, Chandrasekar R, Agarwal A. J Cataract Refract Surg. 2015 Feb;41(2):327-33
8. Complications and visual outcomes after glued foldable intraocular lens implantation in eyes with inadequate capsules: Kumar DA, Agarwal A, Packiyalakshmi S, Jacob S, Agarwal A. J Cataract Refract Surg. 2013 Aug;39(8):1211-8.