



ORIGINAL RESEARCH PAPER

Pathology

Papillary cystadenoma of a minor salivary gland: A case report " – Case paper

KEY WORDS: Papillary, Cystadenoma, Minor salivary gland, Hard palate.

Dr. Udasimath. Shivakumar swamy

MD, DNB, MNAMS (Pathology), Associate. Prof, Department of Pathology, Hassan Institute of Medical Sciences, Hassan

Dr. Fidelis Grace Dass. A

Junior Resident, Department of ENT, Hassan Institute of Medical Sciences, Hassan

Dr. Nagesha. K.R.

MD., Head and Prof, Department of Pathology, Hassan Institute of Medical Sciences, Hassan

ABSTRACT

Papillary cystadenomas of the salivary gland are uncommon, benign, encapsulated or well-circumscribed, multicystic tumors with intracystic papillations. In a large review, papillary cystadenoma constituted 2% of all minor salivary gland tumors. The present study reports a rare case of a papillary cystadenoma arising from the hard palate. A 65-year-old woman was referred to ENT surgeon for the diagnostic evaluation of a swelling of the hard palate. An excision biopsy was performed and the microscopic findings were interpreted as papillary cystadenoma of minor salivary gland. The post-operative course was uneventful and suggested for follow up for any recurrence of the same.

Introduction:

Minor salivary gland cystadenoma is a rare, slowly and painlessly enlarging asymptomatic tumor that rarely exceeds 1.5 cm in diameter. Older patients are most frequently affected with a female predilection [1]. It comprises about 0.8-6.3% of all benign minor salivary gland tumors. Common sites of occurrence are palate, buccal mucosa, lip and the tonsillar area, but cyst adenomas have also been reported to occur on the tongue [2]. No large series of cyst adenoma with follow-up information has been reported. The likelihood of recurrence is low. A conservative surgical procedure ensures complete removal [1]. Recurrence may result from incomplete excision of the slow-growing cyst adenoma or when a cystadenocarcinoma is mis diagnosed.

Case report:

A 65-year-old woman was referred to ENT surgeon for the diagnosis of a swelling of the right hard palate. Physical examination revealed a swelling that was 13 mm in diameter, well-circumscribed, elastic, soft, round and located on the right hard palate. The surface of the mass was smooth with a normal color. The hematological and biochemical examinations were within the normal limits. Based on the findings of the physical examination, the benign salivary gland tumor was pre-operatively diagnosed, and an excision biopsy was performed. The excised swelling was a soft-tissue lesion, measuring 16x9 mm in size. Microscopic examination of hematoxylin and eosin stained tissue sections at low magnification showed unicystic papillary cystadenoma with intraluminal proliferation (Fig. 1). Cystic papillary projections and the major cyst cavity were lined by bilayer columnar epithelium (Fig. 2). Intraluminal papillary projections supported by fibrous connective tissue and underlying capsular connective tissue (Fig. 3) and lined by one to three layers of columnar to cuboidal cells with focal areas showing oncocytic differentiation. Mitotic figures and cytological atypia were not observed (Fig. 4). The microscopic findings were interpreted as those of a papillary cystadenoma. Subsequent to the procedure, the healing was uneventful. The post-operative period was uneventful, and suggested for the follow up for evidence of recurrence.

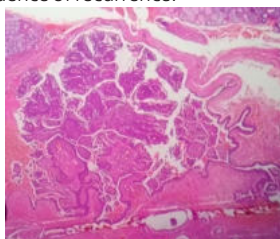


Fig. 1 Unicystic papillary cystadenoma with intraluminal proliferation.

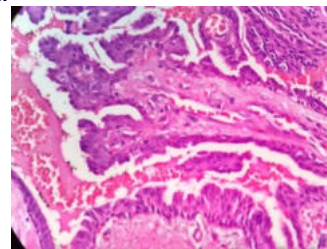


Fig. 2 Cystic papillary projections and the major cyst cavity were lined by bilayer columnar epithelium

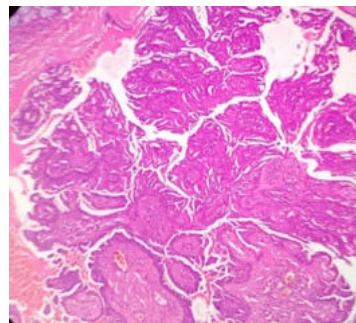


Fig. 3 Intraluminal papillary projections supported by fibrous connective tissue and underlying capsular connective tissue

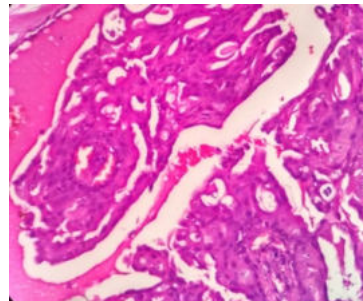


Fig. 4 lining by one to three layers of columnar to cuboidal cells with focal areas of oncocytic differentiation.

Discussion:

Salivary gland cystadenoma is a rare benign neoplasm in which the

epithelial proliferation is characterized by the formation of cystic cavities containing intraluminal papillary projections. Cystadenoma has been reported to occur in patients between 17 years and 86 years of age with a mean age of about 61 years [3]. It frequently occurs in the 6th decade of life more frequently in females, with a female: male ratio being 3:1. The age of occurrence in our case is in terms with what has been reported in the literature. The most common site of occurrence is the palate, as described in our case, followed by the buccal mucosa and the tongue. It has also been reported to occur on the upper and lower lip and floor of the mouth [4]. The frequency of papillary cystadenoma is extremely low. Toida et al [5] reported 1 case of papillary cystadenoma among 82 cases of intraoral minor salivary gland tumors. Chaudhry et al [6] reported only 3 cases of the tumor (7.0%) out of 43 cases of intraoral benign minor salivary gland tumors. In addition, out of the 800 benign intraoral minor salivary gland tumors reported in the English language literature between 1927 and 1960, 16 cases of papillary cystadenoma (2.0%) have been reported [7]. Clinically they are asymptomatic and appearance is similar to mucocele. These lesions present as a slow growing, painless mass, usually <1 cm in greatest dimension when arising in the minor salivary glands with one case reporting 1.5 cm in its maximum diameter in buccal mucosa [8].

Due to the rarity of papillary cystadenoma, the cytological features of the lesion have not been well described in textbooks and other publications. The cytological findings of a reported case of papillary cystadenoma from a minor salivary gland revealed cohesive groups of epithelial cells demonstrating a complex folded appearance in a cystic proteinaceous background, and the possibility of salivary gland tumors was raised in the fine needle aspiration diagnosis [9].

Cystadenoma of the salivary gland is further subdivided into papillary and mucinous types [10]. Bauer and Bauer suggested that the cyst adenoma arises principally from the undifferentiated epithelium of the intercalated ducts of the salivary gland. They are characterized by multicystic growth within a fibrous connective tissue stroma. The papillary variety of cyst adenoma exhibits papillary proliferations that project into the cystic lumens and may closely resemble the Warthin's tumor with the absence of the lymphoid element. The less frequently seen mucinous variety predominantly shows mucous cells in the epithelial lining of the cystic lumens, with absence of distinctly visible papillary projections [11].

Diagnosis of cystadenoma is strictly histopathological. The histopathological features described in our case were characteristic and in general agreement with what has been reported in the literature for cystadenoma. 25% cases of cystadenoma have been reported to show a distinct fibrous capsule, [12] which was present in our case. Microscopically, it has been revealed that the tumors are generally well circumscribed and surrounded by fibrous capsules. Although the extent of solid regions is usually limited, there are cystic regions into which papillae lined by two layers of cuboidal to columnar cells usually project. In the majority of cases, the multilocular individual cystic space is separated by a limited amount of interstitial intervention. Lumens, in numerous cases, contain eosinophilic material with scattered epithelial, inflammatory or foamy cells. Oncocytic, mucus, epidermoid and apocrine cells are occasionally present locally, or may be predominant. Oncocytic variants of cystadenomas predominantly consist of oncocytes in a unilayered or two-layer papillary structure, similar to the epithelium of Warthin tumors, but without lymph stroma [13]. Although papillary configurations are commonly seen in this tumour, the term Papillary Cystadenoma is applied only when the lesion has multilocular cyst formations with conspicuous multiple papillary projections into the cystic spaces [14]. The cysts contain eosinophilic, proteinaceous material, sometimes with a few epithelial and inflammatory cells. Psammoma bodies or crystalloids (tyrosine rich crystals) are rarely present within the luminal secretions. The lining of cystic structures varies from flattened to tall columnar epithelium and cuboidal cells. Mucous, oncocytic, squamous, and apocrine cells are also present in the epithelium

focally or occasionally extensively; a mixture of several cell types may commonly be seen. The lining may be one to three epithelial cells thick and may then abruptly become focally thickened or form ramifying papillary projections with central cores of connective tissue [15]. If multiple cysts are predominantly lined by mucous columnar epithelium with absence of papillary projections, the tumour is termed as Mucinous Cystadenoma [16].

Papillary Oncocytic Cystadenoma is composed of papillary-cystic proliferation of a single or double layered oncocytic epithelium, superficially resembling a Warthin's tumour without a lymphoid stroma [17]. It lacks the dense lymphoid stroma characteristic of Warthin's tumour. The lining epithelium of Oncocytic Cystadenoma may focally be admixed with cuboidal or columnar cells. One case of Oncocytic Cystadenoma having prominent signet ring cell component has been reported in literature [18]. Some cases of papillary oncocytic cystadenoma in minor salivary glands have been reported in literature [19].

Papillary Apocrine Cystadenoma is another variant of papillary cystadenoma containing apocrine cells [20]. The appearance of epithelial cells with eosinophilic cytoplasm, tall and columnar cells and blebbing of the luminal surface provides evidence for apocrine secretion. So far only one case has been reported in literature [21]. In view of the complexity and histomorphological diversity of salivary gland tumours, the pathological differential diagnosis of Papillary Cystadenoma should include Warthin's tumour, mucinous Cystadenoma, Intraductal Papilloma, Cyst Adenocarcinoma, Low grade Mucoepidermoid Carcinoma, and Polycystic Disease which are discussed below.

This tumor closely resembles Warthin tumors, but does not demonstrate the lymphoid elements; Warthin tumors are strongly associated smoking and commonly present as asymptomatic slow-growing round masses. They are typically composed of glandular and cystic structures, with a papillary cystic arrangement. Typically, the tumors are lined by an epithelial bilayer comprised of inner columnar eosinophilic or oncocytic cells surrounded by smaller basal cells and the stroma contains a variable amount of lymphoid tissue with germinal centres. The most frequent clinical finding of salivary gland cystadenoma is a painless mass beneath the mucosa of the palate, lips or buccal mucosa. Oncocytic change can be observed focally or extensively. The majority of cystadenoma cases are treated by simple excision, and recurrence is extremely rare [22]. The present case was distinguished from Warthin tumors by the almost complete lack of lymphoid follicles.

Although rare in oral mucosa, low grade cyst adenocarcinomas are morphologically similar to cystadenomas. Pattern of solid growth in focal areas, cellular atypia in some cases, permeation or destruction of glandular parenchyma, breakdown of the glandular lobe architecture as well as infiltration of adipose, muscle or bone tissues are characteristic features of low grade cyst adenocarcinomas. Differentiation of tumour types depends largely on the identification of actual infiltration of salivary gland parenchyma or surrounding connective tissue by either cystic or solid epithelium in cyst adenocarcinomas. Also, low grade cyst adenocarcinoma is a purely intraductal carcinoma lesion [23]. None of these features was observed in the present case.

Low grade mucoepidermoid carcinoma resembles cystadenoma in terms of growth pattern and the cell population involved. Marked non papillary thickening of cyst lining cells is a more characteristic feature, which often has areas of solid, proliferating, extra luminal cords and islands of tumor. The cell population exhibits a combination of epidermoid, mucosal and to a lesser extent intermediate and basaloid cells. The rare low grade mucoepidermoid carcinoma composed entirely of mucous cells usually contains larger, more irregular mucous cells than those seen in cystadenomas and cystic structures that these mucous cells line are found infiltrating beyond the confines of the salivary gland lobule which was not evident in our case. Polycystic disease involves the entire gland more diffusely than does the well circumscribed cystadenoma [24].

Commonly, cystadenoma is treated by simple excision, and recurrence is not observed. However, Skorpil and Collins have each reported cases that experienced recurrence. However, a lack of evidence of locally devastating behaviour, the relative quiescence of the tumors, which results in the tumors often being found incidentally, histological evidence of a well-circumscribed tumor lacking mitoses and atypia, and the notable failure of any of these tumors to metastasize all prevent the suggestion of malignant potential. Therefore, it is likely that recurrences are attributable to incomplete resection or possibly due to a misdiagnosis of a low-grade cystadenocarcinoma [25]. For these reasons, the present patient is followed-up at regular intervals, and a similar management plan is recommended for all patients that are diagnosed with papillary cystadenoma.

Conclusion:

Most cases of cystadenomas, including our case, are treated by simple surgical excision. Regular follow-up of the patient is necessary for early identification of recurrence, which may occur due to incomplete excision. To the best of authors' knowledge, very few cases have been reported of papillary variety of cystadenoma. The aim of this case report is to document the rarely reported papillary cystadenoma.

References:

1. Shafer WG, Hine MK, Levy BM. Textbook of Oral Pathology. New Delhi: WB Saunders, Philadelphia, Elsevier; 2006. Tumors of salivary glands; pp. 309–56.
2. Santos Jean. Nunes dos. Cystadenoma: A rare tumor originated in minor salivary gland. *J Bras Patol Med Lab.* 2008;44:205–8.
3. Buchner A, Merrell PW, Carpenter WM. Relative frequency of intra-oral minor salivary gland tumors. A study of 380 cases from northern California and comparison to reports from other parts of the world. *J OralPathol Med.* 2007;36:207–14.
4. Halbritter SA, Altermatt HJ, Caversaccio M, Bornstein MM. Apocrine papillary cyst adenoma of a minor salivary gland on the lower lip: Case presentation. *Quintessence Int.* 2009;40:167–9.
5. Toida M, Shimokawa K, Makita H, Kato K, Kobayashi A, Kusunoki Y, Hatakeyama D, Fujitsuka H, Yamashita T and Sibata T: Intraoral minor salivary gland tumors, A clinicopathological study of 82 cases. *Int J Oral Maxillofac Surg.* 34:528–532. 2005.
6. Chaudhry AP, Vickers RA and Gorlin RJ: Intraoral minor salivary gland tumors: An analysis of 1,414 cases. *Oral Surg Oral Med Oral Pathol.* 14:1194–1226. 1961.
7. Tsurumi K, Kamiya H, Yokoi M and Kameyama Y: Papillary oncocytic cystadenoma of palatal minor salivary gland, A case report. *J Oral Maxillofac Surg.* 61:631–633. 2003.
8. Eveson and Nagao (2009) Diseases of salivary gland. In: Leon Barnes. Surgical pathology of the head and neck (3rd edn). Informa healthcare 1: 475–648
9. Lim CS, Ngu I, Collins AP and McKellar GM: Papillary cystadenoma of a minor salivary gland, Report of a case involving cytological analysis and review of the literature. *Oral Surg Oral Med Oral Pathol Oral Radiol Endod.* 105:e28–e33. 2008.
10. Seifert G: Adenoma. *Histological Typing of Salivary Gland Tumors (2nd).* (Berlin Germany). Springer-Verlag. 16–17. 1991.
11. Bauer WH, Bauer JD. Classification of glandular tumors of salivary glands study of one-hundred forty-three cases. *AMA Arch Pathol.* 1953;55:328–46.
12. Tsurumi K, Kamiya H, Yokoi M, Kameyama Y. Papillary oncocytic cyst adenoma of palatal minor salivary gland: A case report. *J Oral Maxillofac Surg.* 2003;61:631–3.
13. Alexis JB and Dembrow V: Papillary cystadenoma of a minor salivary gland. *J Oral Maxillofac Surg.* 53:70–73. 1995.
14. Waldron CA, El-Mofty SK, Gnepp DR. Tumours of the intraoral minor salivary glands: a demographic and histologic study of 426 cases. *Oral Surg Oral Med Oral Pathol.* 1988;66:323–333.
15. Kerpel SM, Freedman PD, Lumerman H. The papillary cystadenoma of minor salivary gland origin. *Oral Surg Oral Med Oral Pathol.* 1978;46(6):820–826.
16. Tange K, Fukuta K, Yonezaki H, Nakayama A, Matsuura H, Maeda MA. Case of mucinous cystadenoma arising in the palate. of Japanese. *J Oral & Maxillofacial Surgery.* 2006;52:73–76.
17. Matsuzaka K, Kokubu E, Takeda E, et al. Papillary cystadenoma arising from the upper lip: a case report. *Bull Tokyo Dent Coll.* 2003;44(4):213–216.
18. Michal M, Hrabal P, Ska lova A. Oncocytic cystadenoma of the parotid gland with prominent signet-ring features. *Pathol Int.* 1998;48(8):629–633.
19. Tsurumi K, Kamiya H, Yokoi M, Kameyama Y. Papillary oncocytic cystadenoma of palatal minor salivary gland: a case report. *J Oral Maxillofac Surg.* 2003;61:631–633.
20. Mahler V, Schell H (1998) Papillary cystadenoma of the minor salivary glands (in German). *Hautarzt* 49:784–788
21. Halbritter SA, Altermatt HJ, Caversaccio M, Bornstein MM. Apocrine papillary cystadenoma of a minor salivary gland on the lower lip: case presentation. *Quintessence Int.* 2009;40:167–169.
22. Tsurumi K, Kamiya H, Yokoi M and Kameyama Y: Papillary oncocytic cystadenoma of palatal minor salivary gland, A case report. *J Oral Maxillofac Surg.* 61:631–633. 2003.
23. Foss RD, Ellis GL, Auclair PL. Salivary gland cystadenocarcinomas: a clinicopathologic study of 57 cases. *Am J Surg Pathol.* 1996;20(12):1440–1447.
24. Auclair PL, Ellis GL, Gnepp DR. Other benign epithelial neoplasms. In: Ellis GL, Auclair PL, Gnepp DR, editors. *Surgical pathology of the salivary glands.* Philadelphia: WB Saunders; 1991. pp. 252–268.
25. Alexis JB and Dembrow V: Papillary cystadenoma of a minor salivary gland. *J Oral Maxillofac Surg.* 53:70–73. 1995.