



**ORIGINAL RESEARCH PAPER**

**Dental Science**

**RADIOGRAPHIC STUDY OF THE JAWS AND TEETH IN THALASSEMIA MAJOR PATIENTS**

**KEY WORDS:** Thalassemia major (TM), Orthopantamogram (OPG)

**Dr. Mrudu J Gondalia**

(M.D.S. Oral Pathology), 15, Narayandham Bunglows, On Canal Road, Nikol Road, Nikol, Ahmedabad, Gujarat, 382350

**Dr. Deepa V Sommanek**

(M.D.S. Oral Pathology), 102, Suvarnabhumi Apartment, Patidar Chowk, near madhuvan park, Sadhuvaswani Road, Rajkot, Gujarat. 360005

**Dr. Dhara Z Mistry**

(M.D.S. 3<sup>rd</sup> year post graduate student, Oral Pathology, G.D.C.H. Ahmedabad), B 105, Shantinagar Village Dahad, Ta Umbergaon, District Valsad, Gujarat, 396171

**ABSTRACT**

Thalassemia is considered to be the most common genetic disorder world-wide. The homozygous form of  $\beta$ -thalassemia (thalassemia major) exhibits the most severe clinical symptoms with marked orofacial deformities. The most common oral and facial manifestations are enlargement of the maxilla, bossing of the skull and prominent malar eminences due to the intense compensatory hyperplasia of the marrow, which gives typical appearance known as "chipmunk" face. In this study 20, panoramic (OPG) radiographs of thalassemia major and 10 of normal children were taken with standardized parameters and assessed to compare the radiographic changes in teeth size & shape, lamina dura, bone marrow size, size of maxillary sinus and inferior alveolar canal width of thalassemia major patients of different ages. These measurements of various parameters were taken by software adobe photoshop from JPEG image and the results were compared with age matched normal children without thalassemia.

**INTRODUCTION**

Thalassemia is considered to be the most common genetic disorder world-wide that involves the defective and decreased production of hemoglobin.<sup>1</sup> About 3% of the world's population carry the thalassemia genem. The disorder is most common among individuals of Mediterranean descent.<sup>2</sup> Worldwide approximately 15 million people are expected to suffer from thalassemic disorders. In India nearly 12,000 infants are born every year with a hemoglobinopathy. On an average one in every 25 Indian is a carrier of thalassemia.

It is inherited single gene ( $\beta$ -thalassemia) or multiple genes ( $\alpha$ -thalassemia) recessive, autosomal blood disease, where hemoglobin is totally absent or partially produced. It is very common in Mediterranean region. Based on genetic and clinical entities, thalassaemias are classified as homozygous, heterozygous or compound heterozygous. The homozygous form of  $\beta$ -thalassemia (thalassemia major) exhibits the most severe clinical symptoms with marked orofacial deformities.<sup>3</sup>

Thalassemia major (TM) is a life-threatening condition that commonly manifests during early infancy, after which progressive pallor, severe anemia, and failure to thrive are common.<sup>2</sup>  $\beta$ -thalassemia is also responsible for causing various manifestations and complications of various degrees on different organs of patients. Orofacial changes include changes in bones of face, resulting in severe disfigurement of face, high and bulging check bones, retraction of the upper lip, protrusion of anterior teeth, and spacing of other teeth; Over- bite or Open-bite; varying degree of malocclusion.<sup>3</sup>

Few studies are available which describes radiographic changes of jaw and teeth in thalassemia patients of Indian Population. So the present study was carried out on Indian population with Thalassemia major to find out the bony changes of the jaws and dental structures using Panoramic Radiographs.

**MATERIALS AND METHOD**

Twenty thalassemia major patients were included in the present study based on set inclusion and exclusion criteria. Orthopantamogram of 10 of normal children in age range of 6-16 were taken. Parent's or guardian's consent was taken and they were subjected to panoramic radiography. OPG machine was Planmeca Proline XC Panoramic x-ray machine with standardized parameters at our institute.

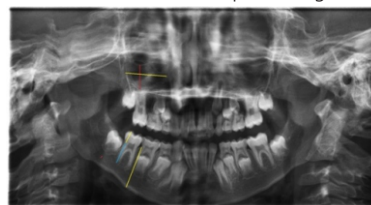
**Inclusion Criteria:**

Known cases of thalassemia major with the age group of 6-14 years, undergoing blood transfusions were included.

**Exclusion Criteria:**

Without prior history of dental treatment and not other systemic disease with thalassemia major.

The measurements of parameters short and spicky roots, bone marrow enlargement, thin or absent lamina dura, loss of cortication of inferior alveolar canal, size of maxillary sinus, taurodontism, crown and root size were taken by software Adobe PhotoshopCS5 from JPEG image and the results were compared with age matched normal children without Thalassemia. Mandibular 1<sup>st</sup> molar was measured for short and spicky root, taurodontism and crown root size. In the case where mandibular 1<sup>st</sup> permanent molar is developing, mandibular deciduous 2<sup>nd</sup> molar is considered as shown in orthopantamogram.



**RESULTS**

**Table 1: Chi Square Test Results for Qualitative Data**

Sr. No.	Parameter	Group I (T. major)		Group II (Normal)		Result	
		Present	Total	Present	Total	p Value	Significance
1	Short & spiky roots	8 (66.6%)	20	0	6	<0.01	Significant
2	BM Enlargement (>1.5mm)	12 (60%)	20	0	10	<0.0025	Highly Significant
3	Loss of lamina dura	14 (70%)	20	0	10	<0.0001	Highly Significant
4	Loss of cortication of Inferior Alveolar Canal	14 (70%)	20	0	10	<0.0001	Highly Significant
5	Small maxillary sinus	17 (85%)	20	0	10	<0.0005	Highly Significant

6	Taurodontism	5 (25%)	20	0	10	>0.1	Non significant
---	--------------	---------	----	---	----	------	-----------------

**Table 2: t- Test Results for Quantitative Data**

	Parameter		n	mean	SD	t value	p value	results
1	Crown size	Group I	18	7.3	0.7467	0.85	0.39	non significant
		Group II	8	7.52	0.2333			
2	Root size (> 2 mm)	Group I	8	7.18	0.691	20.77	0.0001	highly significant
		Group II	6	13.55	0.404			

Table 1 showed that 66.67% thalassemia major children had spiky and short roots and it was statistically significant. 60% thalassemia major children had bone marrow enlargement (average 2.5mm), loss of lamina dura and loss of cortication of inferior alveolar canal in 70% patients; Small maxillary sinus was present in 85% patients. All these findings were statistically highly significant. Taurodontism was present in 5 out of 20 patients and it was statistically non significant.

Table 2 showed that mean crown size of 18 thalassemia major patients was  $7.3 \pm 0.7467$  and it was statistically nonsignificant. Roots more than 2mm in size were found in 8 subjects in TM  $7.18 \pm 0.691$  and in group 2 it was  $13.55 \pm 0.404$  and it was statistically highly significant.

**DISCUSSION**

Thalassemia is the most common single gene disorder in the world and represents a major health burden. It is a heterogeneous group of recessively inherited disorders of hemoglobin molecule characterized by the deficiency or absence of or globin chains. The children with thalassemia classically present with severe anemia and have transfusion dependent survival. The onset of symptoms occurs early in infancy (usually at the age of 4-6 months) and the children are severely anemic and have a short life expectancy. Children with most severe form of the disease rarely survive into adulthood because of cardiac failure, chronic anemia and hypoxia.<sup>4</sup>

The most common oral and facial manifestations are enlargement of the maxilla, bossing of the skull and prominent malar eminences due to the intense compensatory hyperplasia of the marrow, which gives typical appearance known as “chipmunk” face. The overdevelopment of the maxilla frequently results in an increased overjet and spacing of maxillary teeth and other degrees of malocclusion.<sup>5</sup> Radiographic changes occurring during the disease process are mainly because of marrow expansion to compensate for anemia. Obliteration of maxillary sinuses may be due to erythroid hyperplasia. There is also difference in dimensions of crown root ratio noted in these patients.<sup>6</sup>

In the present study, mandibular molar teeth were considered for demonstrating the presence of short and spiky roots. 66.6% of cases showed short roots in this study. It may be due to severe anemia, genetic & environmental factors such as endocrine dysfunction & stomatocedin deficiency which affect the tooth size in thalassemia major as a part of their general effect on growth retardation, The findings were in accordance with Hazza'a et al, Avinash L. Kashid et al and N S Venkatesh Babu & H A Amitha.

Children with thalassaemia have chronic anemia due to ineffective erythropoiesis which damages the red blood cell membrane. The body responds by increasing the production of red blood cells, consequently causing expansion of the bone marrow up to 15-30 times the normal amount. Enlarged bone marrow was present in 60% of TM patients. Similar findings were observed with Hazza'a et al, Neera Ohri et al and Avinash L. Kashid et al.

Lamina dura is part of the alveolar bone which lines the socket as a thin layer of dense cortical bone. Absence or thinning of lamina dura is also seen in other systemic condition like secondary hyperparathydoism. Loss of lamina dura was present in 70% of TM patients. The finding was in accordance with Hazza'a et al, Neera Ohri et al, Avinash L. Kashid et al and N S Venkatesh Babu & H A

Amitha.

Loss of cortication of inferior alveolar canal was observed in 85% TM patients. As the mean hemoglobin decreases, the degree of remodeling increases which explains the absence of the two radiopaque lines of the inferior alveolar canal. Similar finding was observed with Hazza'a et al and Neera Ohri et al.

Small maxillary sinus in 85% of patients can be attributed to the bone marrow expansion causing hyperplasia of alveolar processes of the maxilla at the expense of the sinus's normal volume. It is reported that hemoglobinopathies prohibit maxillary sinus pneumatization. Similar findings were observed with Hazza'a et al, Neera Ohri et al and Avinash L. Kashid et al.

25% patients had taurodontism in TM whereas none had taurodontism in normal children. Difference in frequencies of taurodontism in between two groups using Chi Square test was observed to be statistically nonsignificant. The finding was constracting to Hazza'a, and Avinash L. Kashid et al.

The finding of root length is highly significant in our study but it is significant in Hazza'a. Crown length of group 1 and 2 is statistically nonsignificant which is highly significant in study by Hazza'a.

Hence the results of this study suggest that all these panoramic radiographic signs can be taken as an evidence of systemic diseases and can be used in the field of dentistry as a diagnostic aid for the disease.

**CONCLUSION**

The results of the study reveal that study parameters can also be considered as a good monitor for jaw and dental changes associated with thalassemia major patients under treatment. General dental practitioners are little exposed to such patients in daily practice and are aware of the nature of the disease and its implication on dental care.

**REFERENCES**

1. Avinash L. Kashid, S.P. Kumbhare, R.S.Sathawane, R.N. Mody, Comparative evaluation of radiographic features of jaws and teeth on opp (orthopentamogram) in thalassemia major patients and normal individuals, International Journal of Current Research and Review, Aug 2013; 05 (15): 12-22.
2. Faiez N. Hattab, Patterns of physical growth and dental development in Jordanian children and adolescents with thalassemia major, Journal of Oral Science, 2013; 55(1):71-77 .
3. Syed Muhammad Ali, Syed Mahmood Haider, Sufyan Ahmed, Syed ghanfar Hassan, Sarfaraz Husain Jaffry, Oral and maxillofacial manifestations in 50 -thalassemic patients — a clinical study, Pakistan Oral & Dental Journal 2016; 36(2): 179-183
4. N S Venkatesh Babu, H A Amitha, Radiological study of Oral and Craniofacial Findings in  $\beta$  Thalassaemic Children Undergoing Blood Transfusion, International Journal of Scientific Study, April 2014; 2(1): 11-15.
5. AM Hazza'a and G Al-Jamal, Radiographic features of the jaws and teeth in thalassaemia, Major, Dentomaxillofacial Radiology, 2006; 35: 283-288.
6. Neera Ohri, Mubeen Khan, Nikita Gupta, Garima Bhatt, Parul Malhotra, Abhishek Ranjanpati, A study on the radiographic features of jaws and teeth in patients with thalassemia major using orthopantomograph, Journal of Indian Academy of Oral Medicine and Radiology, Jul-Sep 2015; 27(3): 343-348