



**ORIGINAL RESEARCH PAPER**

**Oncology**

**A CASE REPORT OF CUTANEOUS METASTASIS IN CARCINOMA HYPOPHARYNX**

**KEY WORDS:** skin metastasis ,head and neck squamous cell carcinoma

<b>Dr. Antony Prestine</b>	Department of Radiation oncology, The Gujarat Cancer & Research Institute , Ahmedabad
<b>Dr Ritika Harjani Hinduja</b>	Department of Radiation oncology, The Gujarat Cancer & Research Institute , Ahmedabad
<b>Dr U. Suryanarayan</b>	Department of Radiation oncology, The Gujarat Cancer & Research Institute , Ahmedabad
<b>Dr. Prerak Agrawal</b>	Department of Radiation oncology, The Gujarat Cancer & Research Institute , Ahmedabad
<b>Dr.Saheli Saha</b>	Department of Radiation oncology, The Gujarat Cancer & Research Institute , Ahmedabad
<b>Dr. Jagruti Koladiya</b>	Department of Radiation oncology, The Gujarat Cancer & Research Institute , Ahmedabad

**ABSTRACT**

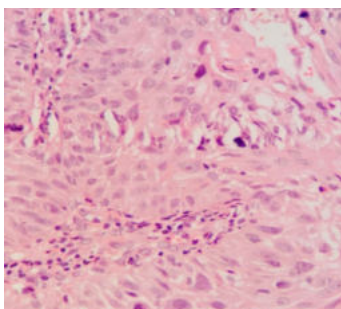
Skin metastasis in a case of head and neck squamous cell carcinoma is rare and distant cutaneous metastasis to lower part of the body in such cases is even rarer. We report a case of 52 year old male with carcinoma hypopharynx who presented to our out patient department and underwent concurrent chemoradiotherapy but eventually developed cutaneous metastasis to abdominal skin while on treatment. He survived for only one month after the diagnosis of skin metastasis .Poor prognosis in cases of head and neck squamous cell carcinoma has already been explained by some authors

**Introduction:**

The most common sites of distant metastases in head and neck cancers are lung (70–75%), liver (17–38%) and bone (23–44%) [1]. The incidence of skin metastasis from internal malignancies varies from 0.7% to 9% of all cancer patients [2]. Skin metastasis has been reported to occur in 0.8–1.3% of patients with SCCHN [3]. Stoma recurrences, permeation nodules and cutaneous metastases in the head and neck or trunk areas from nearby head and neck cancer are by far most commonly reported. Conversely, distant cutaneous metastases to the lower part of the body are exceedingly rare in the absence of iatrogenic tumour seeding.

There is paucity of literature about skin metastases from head and neck cancers. Hence, their diagnosis commonly poses a dilemma about the disease course and management. Here we are reporting a case of a patient with carcinoma in the posterior pharyngeal wall with abdominal skin metastasis.

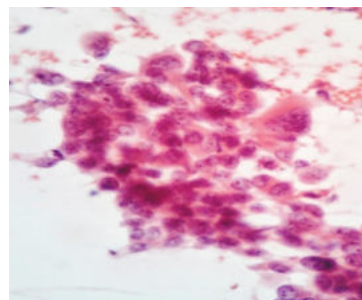
**Case History:** A 52year old man, who was a chronic smoker, presented to our OPD with complaints of pain during swallowing for 2 months. General examination was essentially normal. Direct laryngoscopy under anaesthesia revealed irregular mucosa over posterior pharyngeal wall which bled on touch. Histopathological examination of biopsy from posterior pharyngeal wall showed moderately differentiated Squamous cell carcinoma.



**Figure 1: Histological examination of posterior pharyngeal wall biopsy specimen [40x view]**

After pre-treatment dental and nutritional assessment, he was started with definitive therapy with radiation and concurrent chemotherapy. Radiation was planned to a mid-plane dose of 66Gy in 33 fractions at 2Gy per fraction using conventional technique on 6MV linear accelerator. This was accompanied by Cisplatin based concurrent chemotherapy 40 mg/m<sup>2</sup> weekly.

His treatment progressed uneventfully until 27 fractions when he presented to our emergency department with vomiting lasting one day. He was managed symptomatically. While examining him, a 3cm sized hard non-tender subcutaneous nodule was found at epigastrium. Fine needle aspiration cytology revealed metastatic squamous cell carcinoma.



**Figure 2:Cytological examination of fine needle aspiration specimen from skin nodule [40x view]**

Radiation was discontinued and further management was being planned about feasibility of surgical excision of the subcutaneous nodule. During this time, he developed severe headache. Contrast enhanced computed tomography(CECT) of brain suggested brain metastases. Further metastatic workup revealed multiple metastases in both lungs , adrenal gland, vertebrae and sternum with enlarged mediastinal and abdominal lymph nodes. Treatment intent was changed to palliation. Radiation to head and neck region was discontinued. He received whole brain radiation therapy to a dose of 30 Gy in 10 fractions at 3Gy per fraction using parallel opposed fields. After cranial radiation, he was referred to

medical oncologist for consideration of palliative chemotherapy. Patient and his relatives denied any further treatment and he was taken home against medical advice and succumbed to the disease at home.

#### Discussion:

Distant metastasis from squamous cell carcinoma of head and neck can occur at many sites, most commonly lung and bone (1). The incidence of skin metastasis in HNSCC is reported to be between 0.8%-1.3%(3). In a cohort of 2491 patients reported by Pitman and Johnson 0.76% of the patients developed metastasis to the skin (4). The sites of skin metastasis in HNSCC include neck, chest, scalp, face, lips, axilla, areolas, back, arms and digits; the most common being the neck and chest. The majority of skin metastasis usually occur above the umbilicus, and infra-umbilical skin metastasis are very rare & usually portend a very poor prognosis(5).

Skin metastasis are identified as painless, solitary or multiple subcutaneous nodules and rarely present as plaques, ulcers and cysts. Skin metastasis are distinguished from primary cutaneous squamous carcinoma because skin metastases are completely separate from overlying epidermis. The degree of differentiation is usually the same as in primary although EGFR expression may vary (6). The skin metastases may evolve through three possible mechanisms, -as explained by Kmucha and Troxel. Direct spread involves the extension of the tumour along various tissue planes in proximity to the primary tumour. Local spread can be ascribed to spread through dermal lymphatics with resultant implantation in the skin. The disruption of the normal lymphatic drainage system secondary to surgical excision of the primary tumour and/or radiation therapy may cause the entrapment of tumour cells within the skin. Distant metastasis is thought to involve haematogenous spread. Pulmonary circulation and filtration can be theoretically bypassed via the azygous venous and vertebral venous system via Batson's plexus, allowing skin implantation. The disruption of the normal venous drainage pathways, chiefly the internal jugular vein, as a result of surgical alteration may contribute to this mode of spread. Skin metastases can also occur via the pulmonary circulation itself, with those tumour cells that survive the filtration process achieving successful metastasis to distant skin sites (7).

Treatment options available are surgical excision, chemotherapy, external beam radiotherapy, or combination of these. Surgical excision has been shown to increase survival time –but should only be considered in a few highly selective cases in which the skin metastasis is the only site of disease with no other metastases in the body. In general treatment offered is palliative (8). Berger et al in their study reported that length of survival was approximately three months after skin metastasis become clinically evident in head and neck cancer (9). A study by Dequanter et al showed the overall one- year survival rate for patients developing skin metastases was 0%. (10)

**Conclusion:** There is paucity of literature about cutaneous metastasis from head and neck cancers and hence their diagnosis commonly poses a dilemma about the disease course and management. Distant cutaneous metastasis in a case of squamous cell carcinoma of head and neck carries poor prognosis and early diagnosis of which may allow beneficial modification of treatment strategy which emphasizes the need for thorough skin examination on follow up.

#### References:

1. Cooper JS. Carcinoma of the oral cavity and oropharynx. In: Cox JD, editor. *Moss' radiation oncology—rationale, technique, results*. 7th ed. Mosby: St. Louis; 1994. p. 169–213
2. Spencer PS, Helm TN. Skin metastases in cancer patients. *Cutis*. 1987;39:119-121
3. Zbaren P, Lehmann P. Frequency and sites of distant metastases in head and neck squamous cell carcinoma. *Arch Otolaryngol Head Neck Surg* 1987;113:762–4.
4. Pitman KT, Johnson JT. Skin metastases from head and neck squamous cell carcinoma: incidence and impact. *Head Neck* 1999;21:560–5.
5. Schwartz RA. Cutaneous metastatic disease. *Journal of American Academy of Dermatology* 1995;33:161-82.
6. Saeed S, Keehn CA, Morgan MB (2004) Cutaneous metastasis: a clinical, pathological, and immunohistochemical appraisal. *J Cutan Pathol* 31:419-430
7. Kmucha ST, Troxel JM. Dermal metastases in epidermoid carcinoma of the head and neck. *Arch Otolaryngol Head Neck Surg*. 1993;119:326–30
8. Cole RD, Mc Guirt WF. Prognostic significance of skin involvement from mucosal

tumours of the head and neck. *Arch Otolaryngology Head Neck Surgery* 1995;121:1246–8.

9. Berger DS, Fletcher OH. Distant metastasis following local control of squamous cell carcinoma of the nasopharynx, tonsillar fossa and base of tongue. *Radiology* 1971;100:141-3.
10. Skin metastases from a head and neck carcinoma: a prognostic factor? D. Dequanter, F. B. Mboti, P. Lothaire and G. Andry

