



ORIGINAL RESEARCH PAPER

Surgery

A COMPARITIVE STUDY BETWEEN FIBRIN GLUE AND SUTURING TECHNIQUE IN CONJUNCTIVAL PTERYGIUM SURGERY WITH AUTOGRAFT

KEY WORDS: Pterygium, autograft, fibrin glue, ethilon sutures.

Dr. G.Balaji.

M.S.,D.O., Associate professor, Govt.villupuram Medical College, Villupuram.

Dr. P.Anuradha.*

M.S., Assistant professor, Govt.villupuram Medical College, Villupuram.

*Corresponding author

ABSTRACT

Aim of the study:The aim of the study is to compare fibrin glue versus suture technique in Pterygium surgery with conjunctival autograft.

Materials and methods:A prospective interventional study was conducted in fifty patients who were operated for primary nasal Pterygium in ophthalmology department of Villupuram medical college. Conjunctival auto graft taken from superotemporal limbus was used to cover the bare sclera after excision of the Pterygium. Fifty patients were randomized in to either glued graft or sutured groups. Twenty five received standard sutured autograft with 10-0 ethilon and twenty five received glued autograft. Outcome measures include surgical duration, post operative complications, patient's discomfort, and recurrence rate.

Results: Group I had 25 patients in mean age of 38.00 and in Group II had twenty five patients in age of 46.00. Mean surgical time for group I(12± 0.15)was found to be significantly less as compared to group II[23.42±0.20];(p=0.016). Post operative complications were found to be less in Group I as compared to Group II.

Conclusion:Using fibrin glue for graft fixation in Pterygium surgery shortens surgery time and causes significantly less post operative pain.

Introduction:

Pterygium is a degenerative condition of conjunctiva in which abnormal fibroproliferative tissue extends to the cornea in the interpalpebral region. Exposure to Ultraviolet rays causing damage to limbal stem cell is the recently accepted theory for its occurrence. Though surgery is the treatment of choice, recurrence is most often encountered problem. Many studies are done to reduce the complications in which now a days, autologous conjunctival graft with limbal tissue are having a less complication.

In our study we had compared fibrin glue and suturing technique for fixing the limbal autograft. Fibrin is a blood derived product which act as a biological glue. It is easy to use and absorbable. It mimics last stage of coagulation cascade. We used 10-0 ethilon suture material for suturing the autograft to the sclera bed. We compared these two techniques in means of comfort of the patient, duration of the surgery, post operative complication and recurrence.

Materials and methods:

Sample size : 50patients who presented in the period of January to September 2017 with nasal or temporal pterygium were included for the study. Informed consent was taken from all patients after explaining the procedure. After completion of general ophthalmologic examination, patients were divided in to two groups randomly by systemic random sampling method.

- **Group I:** pterygium excision with conjunctival autograft using fibrin glue.
- **Group II:** pterygium excision with conjunctival autograft using 10-0 ethilon suture fixation.

Duration of the surgery was noted from the first incision to removal of lid speculum.

Methods:

Under local peribulbar anaesthesia, surgical site and eye lashes were cleaned and sterile drape was applied in place. After applying wire speculum, pterygium head was dissected from its corneal attachment by using surgical blade. The fleshy pterygium tissue located under conjunctiva was carefully resected with conjunctival scissors. By using the calipers sclera bed was measured and matching size of conjunctival limbal autograft was harvested from supero temporal region. In group I fibrin glue was applied using duplojet injector over the surface and the autograft placed over the bare area. In group II patients 3 to 4 sutures were applied by using 10-0 ethilon to fix the graft over the bare area.

Post operatively antibiotic steroid were given topically and followed on 1st day, 3rd day, 1st week, one month and third month.

Subjective complaints like pain, irritation, watering were enquired and graded. Objective signs like graft edema, hyperemia were assessed by using slit lamp.

Results:

Age distribution:

Group I had 25 patients in the mean age group of 38.00(S.D-10.192) and in group II had 25 patients in the mean age group of 46.00(S.D-11.51).P value of 0.598(p>0.05)which was found to be not significant.

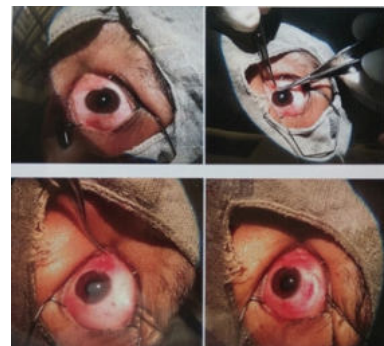GROUP	AGE DISTRIBUTION(MEAN VALUE)
FIBRIN GLUE GROUP	38.00
SUTURED GROUP	46.00

Sex distribution:

In group I 14 male and 11 female patients underwent glue technique and in group II 11 male patients 14 female patients underwent suture technique These data's were analyzed using chi square test and p value was > 0.05 and found was not significant.

GROUP	MALE	FEMALE	TOTAL
FIBRIN GLUE	56%(14)	44%(11)	50%(25)
SUTURE	44%(11)	56%(14)	50%(25)

Fig 1: Steps Of Conjunctival Auto Graft Excision



Post operative signs and symptoms:

Patient's discomfort, irritation, stinging sensation was compared in both group and analyzed using chi square test. Group I patients experienced less discomfort as compared to group II resulting in a significant P value (<0.05).

COMPLICATION	FIBRIN GLUE	SUTURE GROUP
DISCOMFORT LEVEL	4%(1)	92%(23)
GRAFT EDEMA	4%(1)	72%(18)
GRAFT RECESSON	0%	28%(7)

Surgery time:

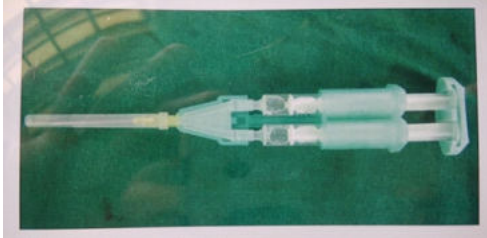
Duration of surgery was analyzed with independent t test and had a significant P value - 0.016(<0.05).

GROUP	TIME TAKEN FOR SURGERY (MEAN VALUE)
FIBRIN GLUE	12.00 MINUTES+ _0.15
SUTURE GROUP	23.42 MINUTES+ _0.20

Recurrence rate:

Patients were followed up at 1st, 3rd and 6th for assessment of recurrence. Recurrence was nil in both the groups.

Fig 2: Duplojet Injector

**Discussion:**

Though limbal auto graft was an ideal procedure in prevention of recurrence after pterygium surgery, suturing technique requires a high level of surgical expertise, prolonged duration of surgery, possibility of suture related complications, post operative discomfort to the patient. An increase in the inflammatory response around sutures in conjunctiva seems to be responsible for these complications.

By replacing the sutures with fibrin glue reduces the suture related complications, reduces the time taken for surgery and less discomfort to the patients.

According to our study we found that 50% were males and 50% were females. In our study discomfort was noted more in suture group 23 patients (92%) as compared to glue 1 patient (4%). Graft edema was observed commonly in suture group patient when compared to fibrin glue patient (72 % and 4% respectively) due to surgical manipulation. Graft edge recession was noticed in 28% of the suture group patients where as none of patient encountered recession in fibrin glue group. There was no evidence of recurrence in neither group of the study.

The average duration of surgery for fibrin glue group was 12 minutes and 23 minutes for suture group, this compares Baher et al study in which mean operating time was 16 and 20 minutes for fibrin glue and suture group respectively.

Conclusion:

Sutureless fibrin glue conjunctival autograft technique is effective, less time consuming with less post operative discomfort to the patients as compared to sutured conjunctival autograft. Hence fibrin glue autografting is a good technique and the patient stands to benefit on account of early return to normal life with less discomfort.

References:

- Rosenthal J W. chronology of Pterygium therapy. Am J Ophthalmol 1953. (PubMed)
- Ang LP, chua JL, Tan DT. Current concepts and techniques in Pterygium treatment. Curr Opin Ophthalmol 2007; 18:308-313.
- McCoombes J A, Hirst L W, Isbell G P. Sliding conjunctival flap for the treatment of primary Pterygium. Ophthalmology 1994. [PubMed]
- Singh G, Wilson M R, Foster C S. Long-term follow up study of mitomycin eye drops as adjunctive treatment for pterygia and its comparison with conjunctival autograft transplantation. Cornea 1990. [PubMed].
- Laughrea P A, Arentsen J J. Lamellar keratoplasty in the management of recurrent Pterygium. Ophthalmic surg 1986. [PubMed]
- Chen P P, Ariyasu R G, Kaza V. et al A randomized trial comparing mitomycin C and conjunctival autograft after excision of primary Pterygium. Am J Ophthalmol 1995. [PubMed]
- Tan D T, Chee S P, Dear K B. et al Effect of Pterygium morphology on Pterygium recurrence in a controlled trial comparing conjunctival autografting with bare sclera excision. Arch Ophthalmol 1997. [PubMed]
- Hogan M. Pterygium and pingecula electron microscopic study. Archives of ophthalmol. 1967; 78: 174-186.
- Trott AT. Cyanoacrylate tissue adhesives. An advance in wound care. JAMA 1997; 277: 1559-60.