



ORIGINAL RESEARCH PAPER

Surgery

VARIED PRESENTATION OF MECKEL'S DIVERTICULUM IN CHILDREN

KEY WORDS:

Dr.gomathi Vadivelu

Asst Prof, Dept Of Paediatric Surgery, Ich, Chennai

Dr.nirankumar Samuel

Resident, Dept Of Paediatric Surgery, Ich, Chennai

Dr.j.muthukumaran

Prof, Dept Of Paediatric Surgery, Ich, Chennai

Dr. Praveen Pandian

Resident, Dept Of Paediatric Surgery, Ich, Chennai

ABSTRACT

Meckel's diverticulum is the most common anatomical variant of the gastrointestinal system. It has varied presentation. The commonest presentation of Meckel's Diverticulum is a band obstruction. We present four cases of different presentation of Meckel's Diverticulum in children.

INTRODUCTION

Meckel's Diverticulum is the most common congenital abnormality of the gastrointestinal tract accounting to about 1.2% of the population and is associated with a number of complications. Diagnosis of a Meckel's diverticulum is difficult in an asymptomatic child. In children, the diagnosis is usually made intra-operatively and the most common presentation is a band obstruction. We present the much rarer presentations of Meckel's diverticulum that presented as acute abdomen.

CASE SERIES

Case 1

A one day old neonate was admitted in the surgical new born as a case of omphalocele and delayed history of passage of meconium. Child gradually developed abdominal distension requiring a laparotomy. A laparotomy was proceeded with a right supraumbilical transverse incision. The omphalocele sac was excised and the content was found to be a ruptured vitellointestinal tract cyst (Fig.1). The child subsequently underwent resection anastomosis and had an uneventful post-operative period.

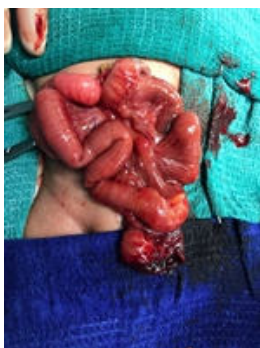

Fig 1: Ruptured giant vitellointestinal duct cyst

Case 2

An 11 month old female child was admitted with bleeding per rectum. Child was apparently healthy with a sudden onset bleeding per rectum. Child was pale on examination. Digital rectal examination revealed blood and clots. X-ray and USG of the abdomen was normal. A technetium scan was done and revealed a Meckel's diverticulum. A laparotomy was planned. A bleeding Meckel's diverticulum was found and a resection anastomosis was done (fig2). The child had an uneventful post-operative period.

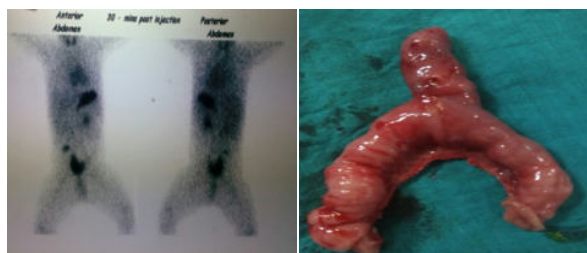


Fig2: A technetium scan showing Meckel's diverticulum and resected specimen of Meckel's diverticulum

Case3

A 2 year old male child was referred to our institute from a peripheral centre as a case of acute appendicitis. The child had history of abdominal pain that was sudden in onset and gradually increasing in severity. The child did not have fever nor was the child having abdominal pain. Clinical examination revealed pain in the right iliac fossa. X-ray of the abdomen was normal. USG revealed that the child had a cystic lesion in the right iliac fossa. A CT of the abdomen was done that showed the cystic lesion in the right iliac fossa. The child was diagnosed to have a perforated acute appendicitis and underwent laparotomy. Laparotomy revealed that the child had an omphalomesenteric cyst that had twisted in its axis. The child underwent resection anastomosis and his post-operative period was uneventful.

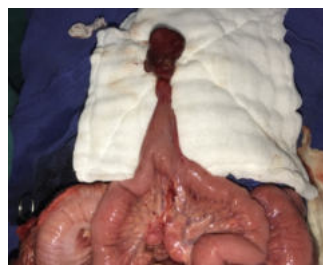


Fig 3: the Meckel's diverticulum with an omphalomesenteric cyst

CASE 4

A 7 year old male child was admitted with abdominal pain, bilious vomiting and abdominal distension. Clinical examination revealed an upper abdominal mass. X-ray revealed that the child had features suggestive of intestinal obstruction requiring an emergency laparotomy. The intraoperative findings were

ileoileocolic intussusception with gangrenous ileal segment requiring resection of the gangrenous segment and an ileocolic anastomosis. Child had an uneventful postoperative period. (Fig 4)

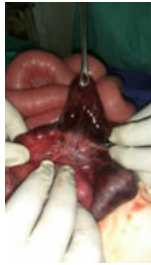

Fig4. Showing the gangrenous segment and the Meckel's diverticulum.

DISCUSSION

Meckel's diverticulum is the most common anatomic variant of the alimentary tract mostly found within the proximal 100 cm of the bowel from the ileocaecal junction [1, 2]. Meckel's Diverticulum presents as a spectrum of symptoms and its complications result from ectopic tissues or bands and cause intestinal hemorrhage, diverticulitis with or without peritonitis, and intestinal obstruction. The clinical presentation of Meckel's diverticulum is varied and is often intestinal obstruction due to bands in the paediatric population [3, 4].

Meckel's Diverticulum is lined mainly by the ileal mucosa. However, Meckel's Diverticulum may contain ectopic tissues, including ectopic gastric, duodenal, colonic, pancreatic or endometrial mucosa, Brunner's glands, and hepatobiliary tissue [5]. Meckel's diverticulum containing ectopic mucosa tend to bleed and hence become symptomatic.

Meckel's Diverticulum can cause intestinal obstruction, which presents with abdominal pain, nausea, vomiting, and distension. Intestinal obstruction can be secondary to (1) volvulus around the vitelloumbilical cord, (2) intussusception, (3) inflammation with adhesion, (4) band between Meckel's Diverticulum and mesenterium, and (5) internal hernia or Littre hernia [6-11]. The incidence differs according to different studies and articles. According to Yahchouchy, obstruction is the most common presenting symptom in the adult population, occurring in almost 40% of patients [12]. But Bemelman et al. thought that intestinal obstruction occurred mainly in patients under the age of 10 [13].

Meckel's Diverticulum can become symptomatic when inflamed, which results in diverticulitis, perforation, and even peritonitis. Inflamed Meckel's Diverticulum and appendicitis share similar clinical symptoms and signs, including fever, nausea, vomiting, tenderness to palpation, and rebound pain. The mechanism of inflammation of Meckel's Diverticulum was also thought to be similar to appendicitis, which is caused by obstruction of the lumen leading to inflammation and even perforation and peritonitis [6].

CONCLUSION

The clinical presentations of Meckel's Diverticulum differed by age and gender. Intestinal hemorrhage occurred more frequently in the pediatric population and in cases of MD that contained ectopic gastric mucosa. When a pediatric patient presents rectal bleeding without other symptoms or signs of infection or bowel obstruction, further studies that detect ectopic gastric mucosa of Meckel's Diverticulum should be considered. Inflammation of MD and acute appendicitis had similar clinical presentations, and they were undistinguishable clinically. Intestinal obstructions also occurred in Meckel's Diverticulum. Early diagnosis of complicated Meckel's Diverticulum is necessary to avoid resection of longer segments of bowel. Meckel's diverticulum can present in a varied manner and a clinical suspicion is often required when handling children with obstruction or acute abdomen.

REFERENCES

[1] J. Dumper, S. Mackenzie, P. Mitchell, F. Sutherland, M. L. Quan, and D. Mew, "Complications of Meckel's diverticula in adults," *Canadian Journal of Surgery*, vol. 49, no. 5, pp. 353-357, 2006.

- [2] R. Satya and J. P. O'Malley, "Case 86: meckel diverticulum with massive bleeding," *Radiology*, vol. 236, no. 3, pp. 836-840, 2005.
- [3] Y.-Y. Tseng and Y.-J. Yang, "Clinical and diagnostic relevance of Meckel's diverticulum in children," *European Journal of Pediatrics*, vol. 168, no. 12, pp. 1519-1523, 2009.
- [4] M. I. Matsagas, M. Fatouros, B. Koulouras, and A. D. Giannoukas, "Incidence, complications, and management of Meckel's diverticulum," *Archives of Surgery*, vol. 130, no. 2, pp. 143-146, 1995.
- [5] J. Sagar, V. Kumar, and D. K. Shah, "Meckel's diverticulum: a systematic review," *Journal of the Royal Society of Medicine*, vol. 99, no. 10, pp. 501-505, 2006.
- [6] V. K. Pepper, A. B. Stanfill, and R. H. Pearl, "Diagnosis and management of pediatric appendicitis, intussusception, and Meckel diverticulum," *Surgical Clinics of North America*, vol. 92, no. 3, pp. 505-526, 2012.
- [7] S.-F. Ko, M.-M. Tiao, F.-C. Huang et al., "Internal hernia associated with Meckel's diverticulum in 2 pediatric patients," *American Journal of Emergency Medicine*, vol. 26, no. 1, pp. 86-90, 2008.
- [8] S. Ishigami, K. Baba, K. Kato et al., "Small bowel obstruction secondary to Meckel diverticulum detected and treated laparoscopically—case report," *Surgical Laparoscopy, Endoscopy and Percutaneous Techniques*, vol. 16, no. 5, pp. 344-346, 2006.
- [9] R. B. Rutherford and D. R. Akers, "Meckel's diverticulum: a review of 148 pediatric patients, with special reference to the pattern of bleeding and to mesodiverticular vascular bands," *Surgery*, vol. 59, no. 4, pp. 618-626, 1966.
- [10] R. Tse and R. W. Byard, "Littre hernia—a rare cause of unexpected death in the elderly," *Journal of Forensic Sciences*, vol. 57, no. 1, pp. 260-261, 2012.
- [11] P. N. Skandalakis, O. Zoras, J. E. Skandalakis, and P. Mirilas, "Littre hernia: surgical anatomy, embryology, and technique of repair," *American Surgeon*, vol. 72, no. 3, pp. 238-243, 2006.
- [12] E. K. Yahchouchy, A. F. Marano, J.-C. F. Etienne, and A. L. Fingerhut, "Meckel's diverticulum," *Journal of the American College of Surgeons*, vol. 192, no. 5, pp. 658-662, 2001.
- [13] W. A. Bemelman, E. Hugenholtz, H. A. Heij, P. H. Wiersma, H. Obertop, and W. P. Tunell, "Meckel's diverticulum in Amsterdam: experience in 136 patients," *World Journal of Surgery*, vol. 19, no. 5, pp. 734-737, 1995.