ORIGINAL RESEARCH PAPER

Medicine

# USE OF VIDEO-ENDOSCOPY AS ADJUVANT IN OPEN MASTOIDECTOMY

**KEY WORDS:** middle ear; endoscopy; open mastoidectomy.

| | |
|---|---|
| **Marcos Luiz Antunes*** | PhD in Medicine from the Federal University of São Paulo (UNIFESP); former Assistant Professor of the Discipline of Otolaryngology at Faculty of Medicine of ABC (FMABC), Adjunct Professor, Department of Otorhinolaryngology and Head and Neck Surgery (UNIFESP), Brazil. *Corresponding Author |
| **Gustavo Fernando Tognini Rodrigues** | Otorhinolaryngologist, Discipline of Otorhinolaryngology of FMABC, São Paulo, Brazil. |
| **Caio Barbosa Campanholo** | Otorhinolaryngologist; assistant physician of the Discipline of Otorhinolaryngology of FMABC, São Paulo, Brazil. |
| **Carlos Eduardo Borges Rezende** | Master in Medicine by FMABC; assistant professor of the Discipline of Otorhinolaryngology at FMABC, São Paulo, Brasil. |
| **Osmar Clayton Person** | PhD in Medicine from the UNIFESP. Master in Otorhinolaryngology from the Medical School of Ribeirão Preto (University of São Paulo –USP). Professor at University of Santo Amaro (UNISA), São Paulo, Brazil. |

**ABSTRACT**

**Introduction:** Use of the endoscope in otologic surgery has been a reason to study anatomical regions of the difficult-to-view middle ear with light microscopy.
**Aim:** evaluate the feasibility of the use of endoscopy in mastoidectomies by open technique, as adjuvant to the use of optical microscopy.
**Methods:** patients with chronic cholesteatomatous otitis media submitted to open mastoidectomy from July 2012 to December 2015, by conventional technique with optical microscopy and adjuvant use of video endoscopy. This was a prospective randomized controlled study, comparing the control of the disease in the post-operative period with a control group.
**Results:** Inflammatory mucosa and cholesteatoma matrix were visualized in anatomical sites difficult to reach under surgical microscopy, through video endoscopy, allowing removal of the disease and better postoperative result.
**Conclusion:** the adjuvant use of video endoscopy in open mastoidectomies has contributed to the visualization of anatomical regions for a better control of the disease.

## INTRODUCTION

The use of endoscopes in numerous medical specialties is well established. It has a special application in sinonasal and cranial base surgery, allowing excellent visualization of anatomical structures, in different angulations, and adequate handling of lesions with preservation or functional restoration.

In otology, however, endoscopes began to be used as an adjuvant and complementary to conventional techniques and have been used as surrogates for the surgical microscope in some surgeries. They may aid in the evaluation of difficult-to-see middle ear regions through light microscopy, such as recess of the facial nerve, anterior epitympanum, tympanic sinus (TS), and supra-tubal recess. Its use in the middle ear is still the object of studies, either in the indication of a more conservative surgical procedure (closed mastoidectomy technique) or in order to reduce the possibility of residual cholesteatoma in some anatomical sites.

There are some authors who have compared conservative surgical techniques using optic microscopy and intraoperative endoscopy with mastoidectomy. They have suggested that the use of endoscope for the treatment of chronic cholesteatomatous otitis media (CCOM) added efficacy, since the relapses of the disease were more delimited and easily removed surgically, but did not demonstrate a reduction of the statistically significant relapse[1].

Other authors, however, advocate the complementary character of endoscopy in conventional otologic surgery not modifying the indication of the surgical technique, but contributing to the proper cleaning of the tympanic and mastoid cavity[1]. In this context, endoscopy in otologic surgery would have importance in the detection of residual lesions, a cholesteatoma matrix in regions not visualized by optical microscopy, regardless of the surgical technique, conservative or not.

In the middle ear it is of special interest the approach of the tympanic sinus, anatomic region of difficult access and of potential residues of CCOM due to the difficulty in removing debris from the disease. Surgical techniques were proposed in order to access the posterior portion of the mesotympanum, more specifically TS. Initially, TS visualization was idealized through its anterior border, that is, from the tympanic cavity towards the mastoid and removal of the disease blindly with hooks and curettes, running the risk of facial nerve injury or disease remaining in the depth of the TS. Later, mastoidectomy with posterior tympanotomy was suggested. However, this access does not yet allow adequate vision of the TS region, since the ideal would be access in the anteroposterior direction or the tympanic cavity towards the mastoid. There is a marked controversy in the literature regarding the presence of the posterior wall of the external auditory meatus, making it difficult to visualize TS in closed mastoidectomy techniques[2].

From the understanding of the possible extension of TS, retrofacial approach techniques in the direction of the mastoid to the tympanic cavity were developed, especially in TS with great posterior extension, which are barely visible by previous access. However, this technique is limited by the pneumatization of the mastoid and risk of facial nerve and posterior semicircular canal injury.

The use of the endoscope in otologic surgery has been a reason to study difficult anatomical regions such as cochlear and vestibular windows, anterior epitympanum and TS with better exposure of these anatomical regions and lower risk of residual disease, considering the chance of up to 48% of TS involvement in CCOM[2].

In view of this, even in the open technique, where the posterior wall of the external acoustic meatus is removed, the presence of residual disease can occur, since the vision obtained with the surgical microscope does not allow to identify with total clarity certain anatomical regions, in particular the pneumatization of the

mastoid. To improve access to these regions, the use of angled vision could contribute to the removal of these wastes.

Considering this new technical possibility, in order to reduce the chances of residual disease in the middle ear, it is necessary to study the use of endoscopes in open mastoidectomies, comparing with a control group.

The aim of this study was to evaluate the feasibility of the use of endoscopy in mastoidectomies by open technique, as adjuvant to the use of optical microscopy, in the sense of visualization and removal of diseases in regions of difficult access and to compare with control group submitted to the open technique with exclusive use of the microscope, taking into consideration the otorrhea symptom or presence of residual cholesteatoma.

## METHODOLOGY

### *Casuistry*

Our sample consisted of patients with diagnostic suspicion of CCOM, treated at the Otorhinolaryngology clinic of the Mario Covas State Hospital and submitted to open mastoidectomy, from July 2012 to December 2015; a prospective randomized controlled study.

### *Methods*

The patients were evaluated through tonal and vocal audiometry, computerized tomography of temporal bones, as well as clinical and physical examination compatible with the suspected diagnosis (CCOM). A protocol was elaborated with the information previously mentioned, plus surgical detail (Annex I). All patients were advised of the risks and benefits of surgery and signed the informed consent form (Annex II).

The study was submitted and approved by the Research Ethics Committee of ABC Medical School, through the Brazilian Platform, number 05688912.9.0000.0082.

Only patients submitted to open mastoidectomy were included. When there was a change from open to closed technique intraoperatively, the patient was excluded from the study. The surgical procedure was initially performed using a surgical microscope until the end of the conventional open technique. Next, the patients were evaluated through endoscopy to visualize some regions, namely; tympanic sinus; recess of the facial nerve, round window, vestibular window and anterior epitmpanum (study group). The patients were evaluated for the presence of cholesteatoma and / or hyperplastic mucosa and, when present, were removed using video endoscopy with 45o, 4mm and 18cm optics, connected to video system (camera and Storz light source and high definition monitor).

The control group consisted of patients with the same diagnosis of CCOM who underwent open technique with the use of the Zeiss surgical microscope (model Z8), the same used in the study group, but without the aid of video-endoscopy after the end of surgery with the surgical microscope.

Tissue samples removed from all patients from both groups were submitted to histological study in order to confirm the initial cholesteatoma hypothesis.

When this diagnosis was not confirmed, the patient was excluded from the study. Patients who did not have adequate postoperative follow-up of at least 12 months after surgery were also excluded. The two groups were randomized by simple draw, respecting age randomization and tomographic changes.

Postoperative follow-up:
All patients, from both groups, were operated by the same surgical team and were followed up at the Otology outpatient clinic for a minimum of 12 months.

The patients followed a protocol of postoperative care of the service, being reassessed weekly in the first month after the surgery, fortnightly in the 2nd and 3rd months and every 3 months, from the 3rd month until one year. Thereafter, as long as the patient is asymptomatic, the return is done every 6 months. In order to evaluate the postoperative evolution, considering the presence of otorrhea and / or recurrence or recurrence of cholesteatoma in the operated ear, the presence of these findings were computed in two periods in both groups, in 6 months and in 12 months.

### *Statistical analysis*

To evaluate the intraoperative and tomographic findings between the groups, the surgical findings by optical microscopy between the groups and to compare the otorrhea and / or residual cholesteatoma between the groups, we used the chi-square test, with a significance level of 5% and reliability of 95% through the IBM-SPSS-SS software version 21-0.

## RESULTS

Twenty-one patients were included in the study group, 11 men and 10 women; mean age of 33 years (SD ± 19). Among the patients in this group, 17 (78.6%) had no history of prior otological surgery, while four patients (21.4%) underwent closed mastoidectomy revision, where open technique was indicated.

In the control group, 20 patients were included, 10 males and 10 females, mean age of 35 years (SD = 20). 17 patients (85%) underwent the first surgery and 3 cases (15%), revision surgery.

Temporal bone computed tomography (CT) showed content with attenuation of soft tissues according to Tables 1 and 2.

**TABLE 1:** Anatomical site involved in CT analysis of preoperative temporal bones in the study group.

| Anatomical site | Soft tissue content in CT of temporal bones |
|---|---|
| Posterior Epitympanum + Mastoid antrum (PE) | 18 (85,71%) |
| Anterior Epitympanum / Supratubaria recess (AE) | 15 (71,43%) |
| Tympanic sinus (TS) | 12 (57,14%) |
| Oval window (OW) | 9 (42,86%) |
| Round window (RW) | 8 (38,09%) |

**TABLE 2:** Anatomical site involved in CT analysis of preoperative temporal bones in the control group.

| Anatomical site | Soft tissue content in CT of temporal bones |
|---|---|
| PE | 17 (85%) |
| AE | 13 (65%) |
| TS | 10 (50%) |
| OW | 8 (40%) |
| RW | 6 (30%) |

**TABLE 3:** Comparison between the tomographic findings in the two groups.

| Site | PE | AE | TS | OW | RW |
|---|---|---|---|---|---|
| Study group | 19 | 15 | 12 | 9 | 8 |
| Control group | 17 | 14 | 10 | 8 | 6 |
| Chi2-p | 0,63 | 1,0 | 0,75 | 1,0 | 0,75 |

*There was no difference between the tomographic findings between the control and study groups.

During surgery under optical microscopy, there was cholesteatoma matrix involvement of the following anatomical regions (Tables 4 and 5)

**TABLE 4:** Anatomical sites involved by cholesteatoma in the study group, under optical microscopy.

| Anatomical Site | Cholesteatoma Matrix by the Optical Microscopy |
|---|---|
| PE | 17 (80,9%) |
| TS | 3 (14,28%) |
| AE | 10 (47,61%) |
| Facial Nerve Recess (FR) | 5 (23,8%) |

**TABLE 5:** Anatomical sites involved by cholesteatoma in the control group, under optical microscopy.

| Anatomical Site | Cholesteatoma Matrix by the Optical Microscopy |
|---|---|
| PE | 17(85%) |
| TS | 4 (20%) |
| AE | 8 (50%) |
| FR | 3 (15%) |

The table 6 presents the comparison between the groups considering the presence or not of cholesteatoma matrix in the various anatomical sites identified by the surgical microscope.

**TABLE 6:** Comparison between the groups in relation to presence of cholesteatoma matrix in the various anatomical sites

| Anatomical site | PE | AE | TS | FR |
|---|---|---|---|---|
| Study group (n) | 18 | 10 | 3 | 5 |
| Control group (n) | 17 | 8 | 4 | 3 |
| Chi2-p | 1,0 | 0,75 | 0,68 | 0,43 |

*There was no statistical difference in the cholesteatoma involvement between the groups by vision under the surgical microscope, proving that the groups were homogeneous.

Using video-endoscopy, it was assessed whether there was involvement of the following regions and or anatomical structures: oval and round window, tympanic sinus, facial nerve recess and anterior epitympanum. When the presence of a cholesteatoma matrix was evaluated after adequate cleaning with optical microscopy, residual lesions were found in some anatomical sites in the study group (Table 7).

**TABLE 7:** Identification of cholesteatoma fragments, according to the anatomical site, under endoscopic vision, after removal under microscope (study group).

| Anatomical site | Cholesteatoma Matrix (%) |
|---|---|
| AE | 5 (14,28%) |
| TS | 3(7,14%) |
| RW | 1 (7,14%) |
| OW | 0 |
| FR | 0 |
| **Total** | **9** |

Endoscopic cholesteatoma fragments were found in 9 anatomical sites of 21 patients in the study group, in a total of 105 anatomical sites (5 sites evaluated in 21 patients). Therefore, 9/105 anatomical sites with cholesteatoma residue (8.6%) were found in the study group.

When the presence of mucosa of residual inflammatory aspect was evaluated, 10 patients presented this condition. In these patients, the inflammatory mucosa appeared in the regions according to the table 8. The patients presented this type of mucosa in different anatomical regions concomitantly.

**TABLE 8:** Presence of hyperplasia of mucosa identified only with endoscopic vision.

| Anatomical site | Hyperplasia of mucosa |
|---|---|
| TS | 10 (47,6%) |
| FR | 6 (28,6%) |
| OW | 2 (9,5%) |
| RW | 2 (9,5%) |
| AE | 3 (14,3%) |
| **Total** | **23** |

***Postoperative Following***

All patients, from both groups, were followed for a minimum period of 12 months and the otorrhea and/or cholesteatoma findings were evaluated at 6 months and 12 months, with the comparison between the groups (table 9).

**TABLE 9:** Presence of otorrhea/cholesteatoma in periods 6 months and 12 months postoperatively.

| Otorrhea/cholesteatoma | 6 months | 12 months |
|---|---|---|
| Study group (n) | 4 | 2 |
| Control group (n) | 10 | 7 |
| Chi2-p | 0,04 * | 0,05 * |

*There was a statistically significant difference in the presence of otorrhea/ cholesteatoma in the postoperative period of 6 and 12 months between the control and study groups, demonstrating a decrease in the recurrence of cholesteatoma in the short and medium period in patients who were submited to endoscopic surgery.

PO - control group (n = 10/20 cases) - PO- 12 months-otorrhea (study group-n = 2/21 cases) (control group n = 7/20 cases).

PO – 6 months- otorrhea - (study group–n=4/21)/ (control group-n= 10/20)

PO- 12 months- otorrhea (study group-n= 2 /21)/ (control group-n= 7/20).

## DISCUSSION

Video-endoscopy is a method increasingly used by otologists in mastoidectomies, aiming at the preservation of middle ear structures, minimizing the risk of lesions and providing adequate visualization of regions that are difficult to access under optical microscopy.

Most of the authors use this technique in a complementary way, after using the surgical microscope; they defend that the endoscopic vision would allow a more conservative approach, without prejudice to the adequate removal of the disease in chronic cholesteatomatous otitis media[2].

Through the aid of the endoscope, regions of difficult visualization can be accessed, such as anterior epitmpanum, facial nerve recess, sinus and oval and round window; regions of residual cholesteatoma potential. In this context, many authors use this instrument to indicate a more conservative surgical technique, such as transcanal ototomy (subcortical mastoidectomy) for cholesteatoma with or without involvement of the mastoid antrum[1,3].

In our study all patients underwent open mastoidectomy; a technique widely used in patients with large cholesteatomas, very inflammatory tissue, disease in anatomical regions difficult to visualize, and in patients with a lower socioeconomic level, usually seen in public health services, where there are difficulties to perform more than one surgery (second look), difficulty in carrying out specialized imaging tests for postoperative control, such as magnetic resonance imaging with diffusion and where patients have greater difficulty accessing health services, a common condition in less developed countries.

Video endoscopy, in our study group, was not used to define a surgical technique. It aimed exclusively at the inspection of anatomical regions hidden under optical microscopy to identify residual cholesteatoma lesion or the presence of hyperplastic mucosa that may be the cause of persistent postoperative otorrhea in some patients, which were removed with the aid of the endoscope after apparent complete removal with surgical microscope.

Ayache S. et al carried out a retrospective study with 350 patients, dividing them into two groups; group A submitted to surgery with optical microscope only and group B with use of optical microscope and video endoscopy. Transcanal tympanoplasty (42%), closed tympanomastoidectomy (46%) and open mastoidectomy (12%) were performed in these groups. The author suggested a significant decrease ($p < 0.05$) in the indication of open mastoidectomy in group B compared to group A, according to the same result of endoscopic vision. There was a

76% incidence of residual retrothympanic lesion in 85 operated ears and 44% in 80 operated ears in group B. Patients were subsequently submitted to a second surgical procedure with endoscopic help (after one year of the first surgery) incidence of total residual lesion to 25% (18 cases in 71 ears). The authors concluded that although endoscopy allows better visualization of the disease, it does not decrease the rate of residual cholesteatoma. But when it manifests itself, it is usually well defined and small, facilitating new surgical approaches. The number of revision surgeries of the study did not allow the calculation of the predictive values.

In our study, in the intraoperative period, after adequate cleaning of the cavity with the surgical microscope, a video endoscopy was performed. Residual cholesteatoma was detected in almost 10% of the evaluated anatomical sites, most of them in the anterior epitympanum and the tympanic sinus. In the literature this percentage is variable and difficult to compare, since different surgical techniques are used, approaches in ears previously operated, disease with varying degrees of aggressiveness. There are reports in the literature on the incidence of residual lesions ranging from 14.78% to 50% for closed technique and first surgery[4,5,6, 7].

In the present study the percentage of residual lesion identified by the endoscopic view (7/21 patients or 33.4% of them had some cholesteatoma fragment) is considered high considering the open technique. We associate this finding with our sample consisting of aggressive cholesteatomas and with involvement of several anatomical regions. The regions considered as hidden and potential residual cholesteatoma lesion, despite open technique, remain difficult to visualize under light microscopy, justifying similar incidences in the two techniques.

Some authors advocate the use of special materials such as ultrasonic curette to facilitate the drilling of external auditory meatus bone under endoscopic vision in order to perform more conservative surgery and with exclusive use of endoscope[10], but they are still unavailable in many services, especially in the case of public hospitals in poorer countries. Hanna et al. described a residual cholesteatoma index of 4% of 119 patients operated with adjuvant fiber optic use[11].

Other authors use magnetic resonance imaging with non-echoplanar imaging to evaluate the extent of cholesteatoma and to program surgery exclusively through a transcanal endoscopic approach or a combined approach using a microscope and endoscope through mastoidectomy.[12] We consider it to be viable exclusively endoscopic access in small and localized cholesteatomas, with little posterior extension to the mastoid, but it was not the profile found in the patients of this study.

In this study, residual hyperplastic mucosa was identified in 61.9% of cases (13/21 patients), most of them in the tympanic sinus. Relevant data, since recent works have associated the presence of this chronic inflammatory tissue to the humid postoperative cavity, corroborating with a decrease in the quality of life of the patient and causing the specialist to suspect of relapse of the disease. Many of these patients persist with otorrhea, despite multiple treatments and adequate cavities and meatoplasties.[9] This fact may explain the higher incidence of otorrhea in the control group, where the endoscope was not used, considering that some of the patients in this group may have inflammatory mucosa and / or residual cholesteatoma in some anatomical sites difficult to see under the microscope, as demonstrated in our results. In the study group, 9.5% of the patients presented otorrhea at 12 months postoperatively and in the control group, 35% of the patients presented the same symptom. This finding was statistically significant in both the 6-month and 12-month postoperative periods ($p = 0.04$ and $p = 0.05$, respectively). This has an important impact on the quality of life of these patients, as well as on the decision of an interventional procedure, such as a revision surgery, in cases of persistent symptoms or suspicion of recurrence of the disease.

In addition to identifying residual cholesteatoma through the endoscope after cleansing with the surgical microscope, we were able to remove inflamed tissues in regions of difficult surgical access, which allows a better control and result of dry cavities, as we observed in the postoperative follow-up of our patients.

## CONCLUSION

We conclude that the adjuvant use of video endoscopy in open mastoidectomies contributed to the visualization of anatomical regions that were difficult to access, facilitating the removal of diseased tissues, which resulted in a lower presence of cholesteatoma and / or otorrhea in the postoperative period of up to 12 months.

**FIGURE 1:** Endoscopic view after final procedure with surgical microscope (right ear).

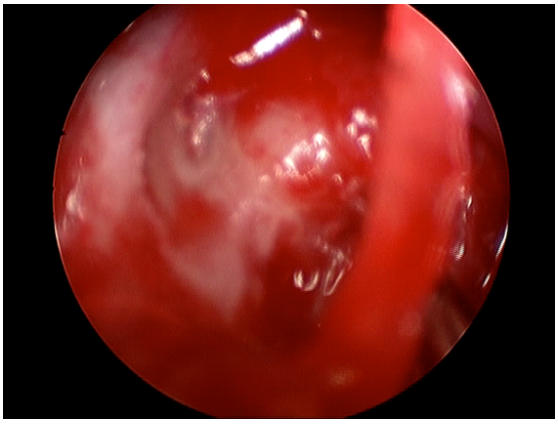

Note the presence of inflamatory tissue around the round window and sinus tympani (right and inferior part of the picture).

## REFERENCES


1. Ayache S, Tramier B and Strunski V. Otoendoscopy in Cholesteatoma Surgery of the Middle Ear: what benefits can be expected? Otology & Neurology 29; 1085-1090, 2008.
2. Abreu C. E. C. Anatomical Study of Anterior and Retrofacial Accesses to the Tympanic Sinus. Master thesis presented to the Federal University of São Paulo - Unifesp / EPM, São Paulo, 2004.
3. Aoki K. Advantages of Endoscopically Assisted Surgery for Attic Cholesteatoma. Diagnostic and Therapeutic Endoscopy, vol.7, pp 99-107, 2001.
4. Good GM, Isaacson G. Otoendoscopy for improved pediatric cholesteatoma removal. Ann Otol Rhinol Laryngol, 108: 893-6, 1999.
5. Barakate M, Bottrill I. Combined approach tympanoplasty for cholesteatoma: impact of middle ear endoscopy. J laryngol Otol; 122: 120-4, 2008.
6. El- Meselaty K, badr- El-Dine M, Mandour M, Maurad M, Darweesh R. Endoscope affects decision making in cholesteatoma surgery. Otolaryngol head Neck Surg; 129: 490-6, 2003.
7. Badr-el-Dine M. Value of ear endoscopy in cholesteatoma surgery. Otol Neurotol; 23: 631-5, 2002.
8. Nogueira Junior JF, Cruz, DN. Endoscopic Ear Surgery: middle ear dissection. Intl. Arch. Otorhinolaryngol, 13 (4): 421-425, 2009.
9. Fukuda TY, Takahashi H, Terakado M, Hishikawa et al. Expression of Keratinocyte Growth Factor and Its Receptor in Noncholesteatomatous and Cholesteatomatous Chronic Otitis Media. Otol Neurotol; 31: 745-751, 2010.
10. Kakehata S; Watanabe T; Ito T; Kubota T; Furukawa T. Extension of indications for transcanal endoscopic ear surgery using an ultrasonic bone curette for cholesteatomas. Otol Neurotol 35 (1); 101-107, 2014.
11. Hanna BM; Kivekas I; Wu YH; Guo LJ; Guidi J; Poe D. Minimally invasive functional approach for cholesteatoma surgery. Laryngoscope, 124 (10): 2386-92, 2014.
12. Migirov L; Wolf M; Greenberg G; Eyal A. Non EPI DW MRI in planning the surgical approach to primary and recurrent cholesteatoma. Otol Neurotol, 35 (1), 121-125, 2014.