



ORIGINAL RESEARCH PAPER

Medical Science

HYPERCEMENTOSIS: A CHALLENGE FOR ENDODONTICS

KEY WORDS: Hypercementosis, Denta Scan, 3D imaging

Dr. Akriti Goel*	Senior Resident, Department of Conservative Dentistry & Endodontics, King George's Medical University, Lucknow. *Corresponding Author
Dr. Namita Mishra	Senior Resident, Department of Conservative Dentistry & Endodontics, King George's Medical University, Lucknow.
Dr. A.P. Tikku	Professor & Head, Department of Conservative Dentistry & Endodontics, King George's Medical University, Lucknow.
Dr. Anil Chandra	Professor, Department of Conservative Dentistry & Endodontics, King George's Medical University, Lucknow.

ABSTRACT The primary objective of endodontic treatment is to restore the affected tooth to its proper form and function. Determination of accurate working length of the root canals is an important primary step that determines the success of endodontic therapy. Hypercementosis, the excessive deposition of cementum caused due to various factors poses additional procedural difficulty while performing root canal therapy. The purpose of this article is to report the successful nonsurgical endodontic management of mandibular molar with hypercementosis diagnosed with the help of 3D imaging.

INTRODUCTION

The primary objective of endodontic treatment is to restore the affected tooth to its proper form and function for which a thorough knowledge of the normal as well as unusual configurations of the pulp and root canal morphology is of prime importance. Determination of accurate working length of the root canals is an important primary step that determines the success of endodontic therapy. A lack of knowledge of internal anatomy and its variations will undoubtedly lead to an error in localization, instrumentation and obturation of root canal system and therefore affect the prognosis.

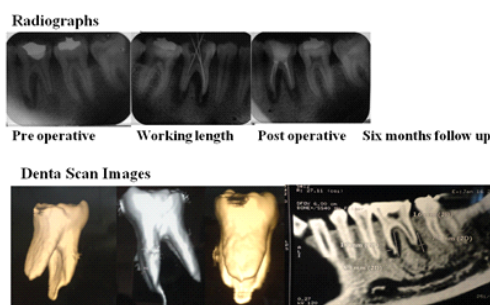
Hypercementosis, also called cemental hyperplasia refers to an adaptive change in the periodontal ligament, characterized by increased cementum thickness on the root surface which is above and beyond the extent necessary to fulfill its normal functions and therefore resulting in abnormal thickening at a limited point or the entire root surface.(1)

The incidence of Hypercementosis is not well established and the available data in the current literature suggests an incidence of 3.8% to 8.4%.(2) The causative factors considered for hypercementosis are many pathological and physiological conditions, such as reactionary response to periapical inflammatory processes (3), various types of trauma, (4) developmental disorders during physiological cementum deposition and physiological continuous dental eruption. Masticatory function and tensile forces are assumed to play an important role in stimulating cementum deposition. However, completely impacted teeth without any functional stimulation are reported to exhibit thicker cementum layers, implying that functional loading is not necessarily a stimulus for cementum apposition.(5) Furthermore, systemic factors such as parathyroid disease, Paget's disease, atherosclerosis, acromegaly, deforming arthritis, hypertrophic arthritis have been described to be associated with the occurrence of hypercementosis.(6) In addition, cementoblastoma must also be taken into consideration as a differential diagnosis.(7) The characteristic radiographic appearance of hypercementosis is thickening of the cementum layer along with blunting or rounding of the root tip with various expressions of the trait from mild to severe.(8) The biological width between the root surface, the alveolar bone and the periodontal ligament is found intact on the radiographs. Usually hypercementosis is associated with lack of pain and is an incidental finding on radiographs, and requires no further treatment however, if the endodontic treatment of the tooth is required it may pose great difficulty and might necessitate surgical intervention. (9) The purpose of this article is to report the successful nonsurgical endodontic management of mandibular

molar with hypercementosis diagnosed with the help of 3D imaging.

CASE REPORT

A 27-year old male patient reported with a chief complaint of pus discharge in the lower right back region of mouth since 2-3 months. Patient had his tooth restored with resin filling with respect to the right mandibular first molar about 3-4 years back. About 2-3 months back patient complained of pus discharge with respect to the same tooth intra-orally. The patient complained of no other symptoms. Pain was absent. His medical history was non-contributing. Clinical examination revealed a draining sinus with respect to mandibular right first molar and defective restoration with respect to the same. Tooth was not tender on percussion. Pulp vitality testing using electric pulp tester yielded a response at a higher current level than the adjacent and contra lateral teeth that were clinically normal. Pre-operative radiograph of the tooth revealed large periapical radiolucency. A unique finding was that of the root apex. An irregular extension was found extending from the apices of both mesial and distal roots of the right mandibular first molar. For further diagnosis a 3-D image was called for.



The Denta Scan images were conclusive enough of the pathology being hypercementosis extending upto 4 mm beyond the root apex. It was focal spur like hypercementosis. The definitive diagnosis was symptomatic chronic periapical abscess with concurrent finding of hypercementosis.

TREATMENT PLAN

A non-surgical endodontic treatment was planned. The treatment plan was explained to the patient and consent was obtained. Under rubber dam isolation, access was gained and three canal orifices were located. Patency of the canals was established using 10 no. K-Files (Dentsply Maillefer). A significant finding was that all the foramina were patent indicating that the cemental growth had not compromised the neurovascular supply of the tooth. The most

challenging part in such cases is the determination of exact tooth length and subsequent working length of the canal, which remains a corner stone for proper endodontic treatment. Working length was established by the radiographic method on dentascanner.

Following the working length determination, the root canals were prepared with a crown down technique by using HyFlex EDM (Coltene Whaledent) rotary files till 6% 25 using copious irrigation with 3.5% sodium hypochlorite solution and saline. 2% chlorhexidine was used for final irrigation. After completion of cleaning and shaping, the root canal system was obturated with cold lateral compaction of gutta percha cones with resin-based sealer (AH plus). The coronal access cavity was restored with composite resin (GC EverX Posterior)

At six months follow up the patient exhibited signs of healing clinically and radiographically.

DISCUSSION

This case report illustrates endodontic treatment of a mandibular molar with hypercementosis. The most common reason for failure of endodontic treatment is presence of missed canal. A canal may be left untreated because of the clinician's negligence to recognize its presence or lack of knowledge of unusual root canal anatomy.

The prevalence of hypercementosis of teeth is not well established and the available data in the current literature range from 1.7% to 3.8% and even up to 84%.⁽⁹⁾ The increased thickness of cementum does not represent a disease, and does not require treatment. However, if any treatment procedure for a diseased tooth, associated with hypercementosis, needs to be carried out, may present with procedural difficulties. Root canal treatment of these teeth can be challenging because it is still unclear whether limiting root canal instrumentation and obturation should occur above or beyond the cementum-dentin-canal junction in teeth with hypercementosis.

Pinheiro et al⁽¹⁰⁾ highlighted that adequate shaping and filling of the canals of hypercementosed teeth may be difficult because the cementum may be not permeable to endodontic instruments. It is important to note, that root canal shaping and filling below the adequate limit might cause the retention of either a contaminated area or inflamed tissue within root canal, contributing to occurrence of chronic apical periodontitis resistant to endodontic treatment. Therefore, hypercementosis may directly influence treatment outcome. In this study, working length, as established by dentascanner ends at the beginning of the cementum canal. This is in accordance with the description by Siqueira et al. who described the beginning of the cementum canal as the narrowest area of root canal which is divergent to tooth apex; even its clinical and radiographic determination is not viable because it is highly inconstant regarding to tooth apex of several teeth. Similarly Pinheiro et al⁽¹⁰⁾ stated that most of root apexes of teeth presenting mild and diffuse hypercementosis did not show irregularities and resorption, but they had a greater number of foramina. Moderate hypercementosis cases presented more irregular areas. In severe hypercementosis, the authors found obliteration of root apex which limited the working length.

CONCLUSION

This case describes a mandibular molar with the presence of excessive cementum at apex of root, which obscured the apex on radiographs and apical termination point of endodontic instrumentation is found challenging to evaluate. The clinician must also thoroughly examine the pulp chamber, canals and associated pathology to ensure complete debridement of all the root canal system which might increase the chances for long-term successful endodontic therapy. There is lack of scientific based studies guiding the root canal treatment in teeth with hypercementosis. The clinical implications of teeth with hypercementosis should be evaluated thoroughly by the clinicians.

REFERENCES

1. Weine FS, Healey HJ, Gerstein H, Evanson L: Canal configuration in the mesiobuccal root of the maxillary first molar and its endodontic significance. *Oral Surg Oral Med Oral Pathol* 1969; 28: 419-25.

2. Grzesik WJ, Narayanan AS. Cementum and periodontal wound healing and regeneration. *Crit Rev Oral Biol Med* 2002; 13: 474-84.
3. Thoma KH, Goldman HM. The pathology of dental cementum. *J Am Dent Assoc* 1939; 26: 1943-53.
4. Comuzzie AG, Steele DG. Enlarged occlusal surfaces on first molars due to severe attrition and hypercementosis: examples from prehistoric coastal populations of Texas. *Am J Phys Anthropol* 1989; 78: 9-15.
5. Israel H. Early hypercementosis and arrested dental eruption: heritable multiple ankylosis. *J Craniofac Genet Dev Biol* 1984; 4: 243-46.
6. Aldred MJ, Cooke BED. Paget's disease of bone with involvement of the dental pulp. *J Oral Pathol Med* 1989; 18: 184-85.
7. Napier Souza L, Monteiro Lima Junior S, Garcia Santos Pimenta FJ, et al. Atypical hypercementosis versus cementoblastoma. *Dentomaxillofac Radiol* 2004; 33: 267-70.
8. Nanci A. *Ten Cate's Oral Histology: Development, Structure, and Function*. 8th ed. St Louis, MO: Elsevier Mosby; 2012. 70-232.
9. Vertucci FJ. Root canal anatomy of the human permanent teeth. *Oral Surg Oral Med Oral Pathol* 1984; 58: 589-99.
10. Pinheiro BC, Novaes T, Capelozza ALA, Consolaro A. A scanning electron microscopic study of hypercementosis. *J Appl Oral Sci*. 2008; 16: 380-84.